

---

# EM CASES DIGEST

THE MAGAZINE SERIES FOR ENHANCED EM LEARNING

---



## Vol. 2: Pediatric Emergencies

BY ANTON HELMAN & TARYN LLOYD

---

# **EM CASES DIGEST**

**THE MAGAZINE SERIES FOR ENHANCED EM LEARNING**

## **Vol. 2: Pediatric Emergencies**

**BY ANTON HELMAN & TARYN LLOYD**



---

Copyright © 2016 by Medicine Cases

Emergency Medicine Cases by Medicine Cases is copyrighted as “All Rights Reserved.” This ebook is Creative Commons Attribution-NonCommercial-NoDerivatives 3.0 Unsupported License. Upon written request, however, we may be able to share our content with you for free in exchange for analytic data. For permission requests, write to the publisher, addressed “Attention: Permissions Coordinator,” at the address below.

Medicine Cases  
216 Balmoral Ave  
Toronto, ON, M4V 1J9  
[www.emergencymedicinecases.com](http://www.emergencymedicinecases.com)

This book has been authored with care to reflect generally accepted practices. As medicine is a rapidly changing field, new diagnostic and treatment modalities are likely to arise. It is the responsibility of the treating physician, relying on his/her experience and the knowledge of the patient, to determine the best management plan for each patient. The authors and publisher of this book are not responsible for errors or omissions, or for any consequences from the application of the information in this book, and disclaim any liability in connection with the use of this information. This book makes no guarantee with respect to the completeness or accuracy of the contents within.

---

# OUR THANKS TO...

## EDITORS-IN-CHIEF

Anton Helman

Taryn Lloyd

## PRODUCTION EDITOR

Michelle Yee

## PRODUCTION MANAGER

Garron Helman

## CHAPTER WRITERS

Sean Caine

Lincoln Foerster

Anna MacDonald

Michael Misch

Meeta Patel

Robyn Shafer

Rob Simard

Ahmed Taher

Rajani Vairavanathan

## PODCAST SUMMARY EDITORS

Niran Argintaru

Lucas Chartier

Keerat Grewal

Claire Heslop

Michael Kilian

## REVIEW QUESTIONS AUTHORS

David Homuth

Areej Shahbaz

## PODCAST GUEST EXPERTS

Alyssa Abo

Samina Ali

Alex Arroyo

Sarah Curtis

Anthony Crocco

Jason Fischer

Stephen Freedman

Anna Jarvis

Eric Letovsky

Sanjay Mehta

Angelo Mikrogianakis

Gina Neto

Jonathan Pirie

Sarah Reid

Lawrence Richer

Jennifer Riley

Dennis Scolnik

Adam Sivitz

Rahim Valani

Amy Drendel



*University of Toronto, Faculty of Medicine*

*EM Cases is a venture of the Schwartz/  
Reisman Emergency Medicine Institute.*

*We'd like to thank our colleagues at SREMI  
for their support and encouragement.*

# SREMI

**SCHWARTZ/REISMAN  
EMERGENCY MEDICINE  
INSTITUTE**

---

**Mount Sinai Hospital**

**North York General Hospital**

## ACKNOWLEDGEMENTS

I would like to thank my wife, Sasha, and my children Emma and Rowan for their ceaseless patience and support; my brother Garron for his dedication and advice; my brother Wayne for the original website and logo design; my mentor, Walter Himmel, for his inspiration, friendship, and advice; the EM Cases Advisory Board for their guidance; the *EM Cases* team (Lucas Chartier, Teresa Chan, Justin Morgenstern, Michael Misch, Claire Heslop, Keerat Grewal, Taryn Lloyd, Michelle Yee, Lincoln Foerster, and Michael Kilian) for their hard work and dedication; Mike Cadogan for his inspiration to join the FOAMed community and his unparalleled altruism; the Schwartz/Reisman Emergency Medicine Institute (Howard Ovens for his support and wisdom; Bjug Borgundvaag, Shirley Lee, and Shelley McLeod for their support and team spirit); Kuldeep Sidhu for his leadership, support, and patience; all of the guest experts for their incredible knowledge and wisdom; the FOAMed community for teaching me and for its egalitarian spirit; and the *EM Cases* audience for your honest feedback and the inspiration to keep *EM Cases* growing. I feel immensely fortunate to have had the opportunities that have allowed me to learn, and educate others, in a profession that is continually blossoming.

Anton Helman, MD, CCFP(EM), FCFP  
Assistant Professor, University of Toronto  
Department of Family & Community Medicine  
Staff Physician, North York General Hospital, Department of Emergency Medicine  
Education Innovation Lead, Schwartz-Reisman Emergency Medicine Institute  
Founder, Editor-in-Chief, and host of *Emergency Medicine Cases*

*Thanks to TREKK for its partnership in recruiting the pediatric emergency guest experts for the podcasts and for the needs assessment from which the topics were chosen.*



# FOREWORD

Social media technologies are game-changers in health professions education.

In the past several years, social media technologies have begun challenging how traditional academic institutions think about education delivery and teaching. Expensive textbooks, classroom-based teaching, and siloed workshops are competing with the growing presence of open-access blogs, podcasts, and global online journal clubs for learner attention. New communities of practice are appearing constantly, connected by the Internet.

*EM Cases* was one of the first podcasts I noticed at the forefront of this movement. When it launched in 2010, I was immediately impressed by the high-quality content and attention to detail. I am not surprised to see that it currently garners an amazing 90,000+ downloads per month. Its popularity is a reflection of the how today's busy lifelong learners consume medical knowledge. In a word, it is—opportunistically. With so many digital distractors and an overwhelming amount of medical information to keep abreast of in today's world, education delivery needs to be portable, easily accessible, and digestible in chunks. Thus podcasts provide an appealing solution for the busy learner, who may wish to listen while driving to work or exercising.

As a blogger, however, I am keenly aware that blogs and podcasts generally provide a rather haphazard delivery of content to learners. I am guilty of that. I publish what is most timely and relevant in the eyes of my editorial team. There is no set curriculum framing the periodic release of new materials, and generally each blog post is a standalone lesson. But can't we, as educators, do better?

*EM Cases* can. The launch of the *EM Cases Digest* series is a huge step toward structuring the modern learning experience using social media technology. This marks the evolution of *EM Cases* from a podcast resource to a premiere podcast-enhanced educational curriculum. While many podcast organizations have brief show notes for their podcasts, none that I know of has created a professionally designed ebook, integrating podcasts into a thoughtfully organized framework of text- and image-based lessons with question-and-answer sections.

## FOREWORD (Continued)

From a pedagogical and instructional design standpoint, this innovative approach makes sense. It optimizes and solidifies learning based on Mayer's cognitive theory of multimedia learning. Incorporating both visual (ebook) and auditory (podcast) elements optimizes working memory and thus learning.

Congratulations to Dr. Anton Helman and his *EM Cases Digest* team, who are at the forefront of reimagining health professions education. I can only imagine the ginormous effort that went into producing such a product with an eye toward visual design, education theory, and multimedia integration. The result is an ebook series that is fun, educational, and a joy to read. Thank you for your dedication and pioneering vision for advancing education in emergency medicine.

Your friend and fan,  
Michelle

Michelle Lin, MD  
Academy Endowed Chair of Emergency Medicine  
Professor of Emergency Medicine  
University of California, San Francisco;  
Editor-in-Chief  
*Academic Life in Emergency Medicine* blog (<http://aliem.com>)  
@M\_Lin

# Guide to EM Cases Digest

We hope you will find the *EM Cases Digest* series to be an interactive, flexible, and engaging way to enhance your emergency medicine learning journey. These ebooks are intended to be an adjunct to the EmergencyMedicineCases.com podcasts, as well as to existing emergency medicine curricula and resources. For optimal learning, we suggest *EM Cases Digest* be used in conjunction with the podcasts for spaced, repetitive learning, and as an interactive workbook, through which you can explore the links, videos, and original resources (links to original references can all be found on our website). We encourage you to attempt the Q&As actively, revealing expert answers only after formulating your own answers and opinions.



**Clinical  
Pearls**



**Tools  
& Rules**



**Key  
References**



**Pitfalls**



**Caution**



**What would  
you do?**



**AH-HA**

**Ah-Has**



**EXPERT  
OPINION**

**Expert  
Opinion**



**Your  
Comments**

Here's a little description to help explain all of the graphics in this book:

**Clinical Pearls:**

Nuggets of wisdom

**Pitfalls:**

Common regrets

**Ah-Has:**

Wow moments

**Tools & Rules:**

Clinical decision tools and rules

**Caution:**

Warning; badness ahead

**Expert Opinion:**

What our guest experts think when the evidence is unclear

**Key References:**

EBM game-changers

**What would you do?:**

Reflect on what you would do in your practice

**Your Comments:**

Go to the linked blog post to leave your comment





## JUMP TO CHAPTER...

---

### **Chapter 1: Fever Without a Source**

**Page 4**

[\*Link to the podcast with Sarah Reid and Gina Neto\*](#)

### **Chapter 2: Sepsis and Septic Shock**

**Page 22**

[\*Link to the podcast with Sarah Reid and Gina Neto\*](#)

### **Chapter 3: Pain Management**

**Page 35**

[\*Link to the podcast with Samina Ali and Anthony Crocco\*](#)

### **Chapter 4: Head Injury**

**Page 53**

[\*Link to the podcast with Rahim Valani and Jennifer Riley\*](#)

### **Chapter 5: Pediatric Procedural Sedation**

**Page 68**

[\*Listen to the podcast with Amy Drendel\*](#)

### **Chapter 6: Orthopedic Injuries**

**Page 82**

[\*Link to the podcast with Sanjay Mehta and Jonathan Pirie\*](#)

### **Chapter 7: POCUS Nerve Blocks**

**Page 106**

[\*Link to the podcast with Jason Fischer\*](#)

### **Chapter 8: Abdominal Pain and Appendicitis**

**Page 117**

[\*Link to the podcast with Anna Jarvis and Stephen Freedman\*](#)

### **Chapter 9: POCUS Appendicitis and Intussusception**

**Page 132**

[\*Link to the podcast with Adam Sivitz and Alex Arroyo\*](#)

### **Chapter 10: Gastroenteritis, Constipation and Obstruction**

**Page 143**

[\*Link to the podcast with Anna Jarvis and Stephen Freedman\*](#)



## JUMP TO CHAPTER...

---

### **Chapter 11: Diabetic Ketoacidosis**

**Page 168**

[\*Link to the podcast with Sarah Reid and Sarah Curtis\*](#)

### **Chapter 12: Bronchiolitis**

**Page 183**

[\*Link to the podcast with Dennis Scolnik and Sanjay Mehta\*](#)

[\*Listen to the bonus podcast with Amy Plint\*](#)

### **Chapter 13: Asthma**

**Page 197**

[\*Link to the podcast with Dennis Scolnik and Sanjay Mehta\*](#)

### **Chapter 14: Lung POCUS**

**Page 212**

[\*Link to the podcast with Alyssa Abo\*](#)

### **Chapter 15: Croup**

**Page 221**

### **Chapter 16: Pediatric Syncope**

**Page 230**

[\*Link to the podcast with Eric Letovsky and Anna Jarvis\*](#)

### **Chapter 17: Pediatric Seizures**

**Page 250**

[\*Link to the podcast with Lawrence Richer and Angelo Mikrogianakis\*](#)

### **Rapid Review Questions**

**Page 269**

# CHAPTER 1: FEVER WITHOUT A SOURCE

[LISTEN TO THE PODCAST WITH SARAH REID AND GINA NETO HERE](#)



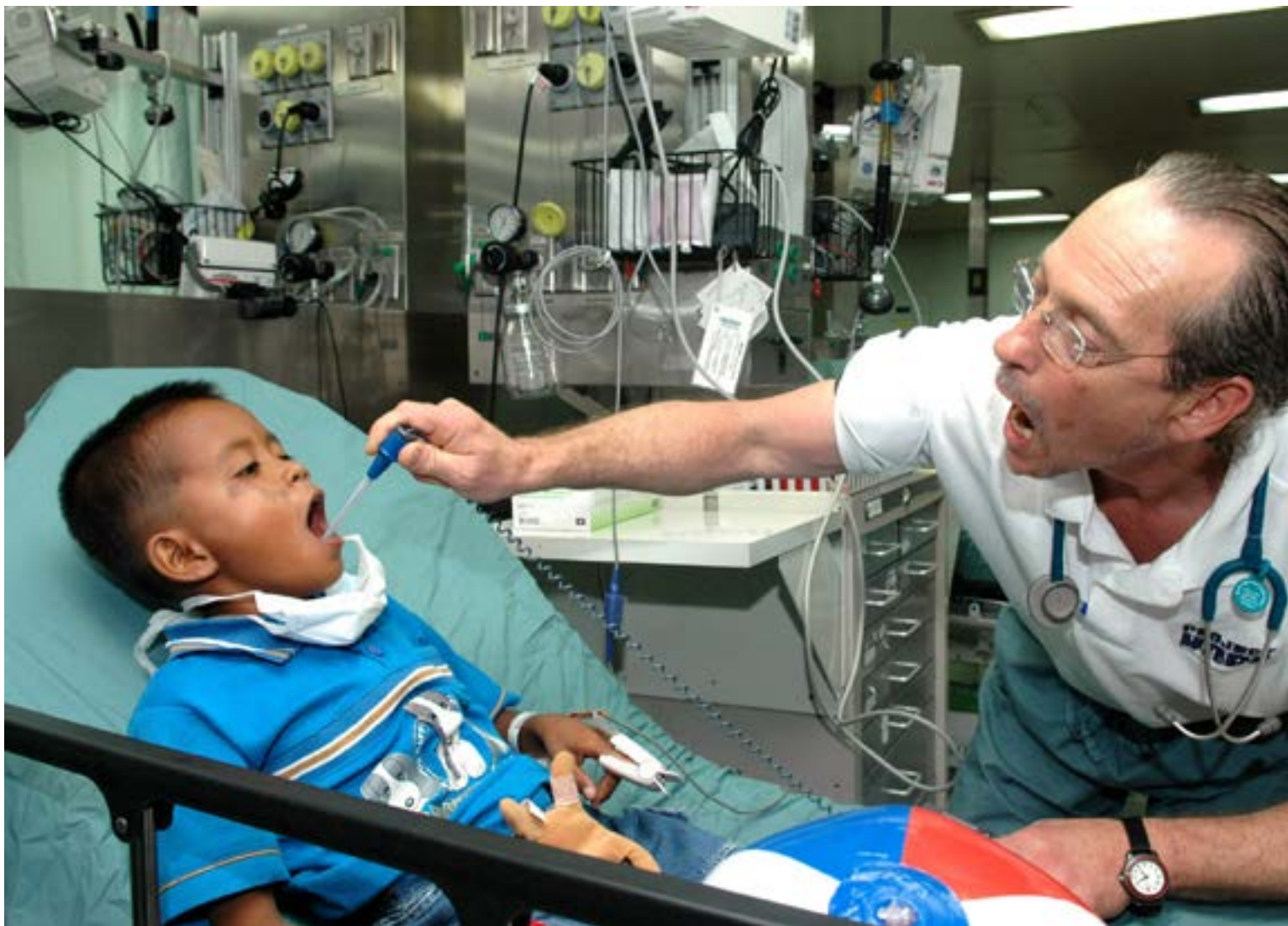## Objectives

1. Understand the principles of fever management
2. Identify abnormal vital signs in the setting of pediatric fever
3. Have an approach to the investigation of UTI in children
4. Develop an approach to the child with fever without a source
5. Know when to order a full septic workup versus a partial septic workup

Approximately 20% of children who present to the ED with fever will have **fever without a source** despite your thorough history and physical exam.

A small but significant number of this 20% without an identifiable source of fever will have an occult bacterial infection—UTI, bacteremia, pneumonia, or even the dreaded early bacterial meningitis. These are all defined as serious bacterial infections (SBI), with occult UTI being the most common SBI (especially in children under the age of two years).

In the old days, we used to do a full septic workup including LP for all infants under the age of three months; thankfully, times have changed in the post-*Haemophilus* and pneumococcal vaccine age, and we aren't quite so aggressive any more with our workups. Nonetheless, it's still controversial as to which kids need a full septic workup, which kids need a partial septic workup, which kids need just a urine dip, and which kids need little except to reassure the parents.





## CASE 1: FEVER PRINCIPLES

A 12-month-old girl is brought in to your ED with three days of fever between 38.5°C and 40°C. She is previously healthy, immunizations are up to date (including Haemophilus and pneumococcal vaccines), and there has been no recent travel. She has no cough, no difficulty breathing, no vomiting, no apparent belly pain, no rash, and no diarrhea. She's been eating and drinking well at home.

**Q: Does this child require a rectal temperature measurement? Which children with suspected fever require a rectal temperature measurement in the ED?**

**A:** As rectal temperatures are the most accurate estimation of core body temperature compared with axillary, oral, and ear temperatures, and missing fever in younger children may carry high morbidity, it is recommended that a rectal temperature be obtained in all neonates, infants, and toddlers (younger than three years old) who present to the ED with suspected fever or with an undefined illness that could be the result of an infection/sepsis.

**Q: The parents are very concerned that the “very high fever” of their 12-month-old girl might cause brain damage or represent a serious illness. This is a common concern. How do you counsel the parents?**

**A:** Fever itself is the body's natural response to fighting infection, and does not inherently cause harm. Children with infection as a cause of their fever almost never mount a fever high enough to be dangerous (> 41.5°C); these very high temperatures are typically seen only in non-infectious causes of hyperthermia.

In terms of predicting bacteremia, the precise height of the fever is not as important as the duration of the fever. A fever of 39.8°C that has lasted for two days is not as concerning as a fever of 38.2°C that has lasted for six days in terms of the risk of bacteremia.

### **Video:**

[Click here to see Dr. Anthony Crocco's rant on fever phobia.](#)



### Clinical Pearl:

A parent's assessment of fever by touch has been shown to correlate fairly well with a true fever. A child who is brought in for a "tactile fever" but who is afebrile in the ED still warrants a thorough assessment for sources of fever. Be sure to ask if the child received an antipyretic prior to your assessment.



### Expert Opinion:

To avoid potential toxicities, our experts recommend no more than three doses of ibuprofen 10 mg/kg per day and no more than four doses of acetaminophen 15 mg/kg per day.

**Q: This child has a rectal temperature of 39°C. Do we need to treat this child's fever in the ED?**

**A:** While this temperature is not inherently dangerous to the child, there are benefits to treating fever. Lowering the temperature of a febrile child not only provides comfort and minimizes dehydration, but treating the fever also allows for more accurate prognostication when the now afebrile child is re-examined. When a child changes from being irritable or lethargic to active, playful, and alert after receiving an antipyretic for their fever, you can usually be less concerned about an SBI. If the child's vital signs and clinical picture continue to be concerning when afebrile, then an SBI should be suspected.

**Q: Which is the better antipyretic: acetaminophen or ibuprofen?**

**A:** Studies show that ibuprofen is superior at treating both fever and pain in children.

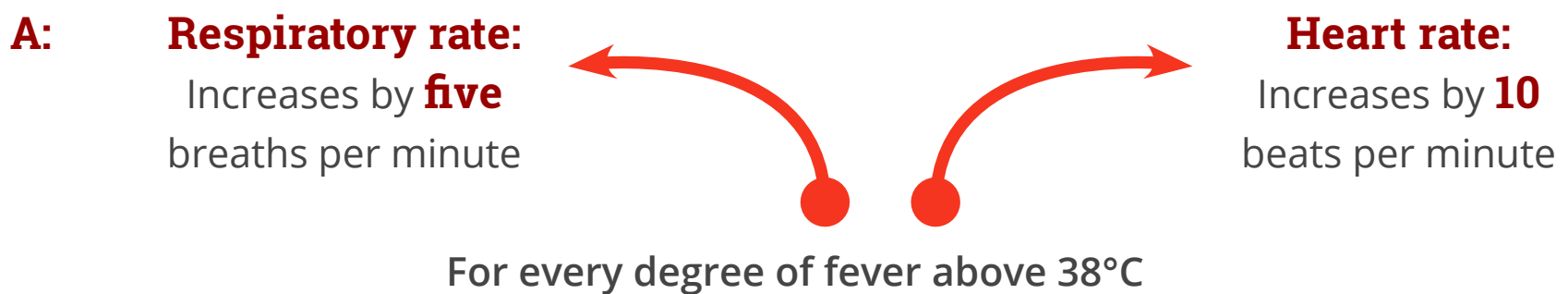


**Caution!** Combining ibuprofen and acetaminophen may be a more effective strategy than either alone (based on adult literature), however, there is a real risk of toxicity due to dosing errors in children. If advising this strategy, a handout on dosing methods can help parents keep track of a dosing schedule.

**FOAMed link:** [Click here for a great blog post reviewing the literature on the treatment of pediatric fever by The Skeptics' Guide to EM.](#)

**Case continued:** On exam of this 12-month-old female, she appears tired but non-toxic. Her vital signs are: a rectal temperature of 39.0°C, heart rate of 125, and respiratory rate of 25. A thorough head-to-toe exam reveals an erythematous and bulging left tympanic membrane.

**Q: What is the normal change in heart rate and respiratory rate in response to a fever?**



So, in our 12-month-old girl:

- Corrected HR =  $125 - (10 \times 1) = 115$
- Corrected RR =  $25 - (5 \times 1) = 20$

### Normal Pediatric Vital Signs by Age

Vital Sign	Infant (0-12 mths)	Child (1 -11 years)	Pre-teen/Teen (12 yrs+)
Heart Rate	100 to 160 bpm	70 to 120 bpm	60 to 100 bpm
Resp Rate (breaths per min)	<b>0 to 6 months</b> 30 to 60 bpm	<b>1 to 5 years</b> 20 to 30 bpm	12 to 18 bpm
	<b>6 to 12 months</b> 24 to 30 bpm	<b>6 to 11 years</b> 12 to 20 bpm	
Blood Pressure	<b>0 to 6 months</b> 65 to 90 systolic /45 to 65 mm Hg	90 to 110 systolic / 55 to 75 diastolic mmHg	110 to 135 systolic/ 65 to 85 diastolic mmHg
	<b>6 to 12 months</b> 80 to 100 systolic /55 to 65 mm Hg		

All ages	
Rectal Temperature	36.6°C to 38°C (97.9°F to 100.4°F)
Tympanic Temperature	35.8°C to 38°C (96.4°F to 100.4°F)
Oral Temperature	35.5°C to 37.5°C (95.9°F to 99.5°F)
Axillary Temperature	34.7°C to 37.3°C (94.5°F to 99.1°F)

**Case resolution:** The child is observed in the ED and is treated with ibuprofen 10 mg/kg po. She continues to look well, normal vital signs are recorded, and she is tolerating oral fluids. You diagnose her with otitis media and give the parents a prescription for amoxicillin. You give them clear discharge instructions and advise them to follow up with their primary-care physician.



**Clinical Pearl:**

If the child has abnormal vital signs after correcting for fever, have a high degree of suspicion for dehydration, early compensated shock, or early sepsis. Make sure you assess for perfusion and mentation, and ask about urine output.



## CASE 2: URINARY TRACT INFECTION

An 18-month-old male is brought to your ED with four days of fever at home between 38.0°C and 38.8°C. His parents say he has been fussier than usual. He has no significant past medical history, his immunizations are up to date, and there is no history of recent travel. He has been drinking well at home. No infectious source is identified on history. On exam, he is alert and non-toxic. Vital signs are normal except for an oral temp of 38.2°C. On a thorough head-to-toe exam you do not find a source of infection.

**Q: This child has no source of infection that is readily identifiable on history or physical. What is the difference between fever without a source and fever of unknown origin?**

**A: Fever without a source:** There is no identifiable source of fever after a complete history and physical.

**Fever of unknown origin:** At least two to three weeks of fever without an identifiable source after initial investigations. The most likely cause remains infectious but other causes, such as malignancy and rheumatologic causes, need to be considered.

**Q: For children who present to the ED with fever without a source, how likely are they to be suffering from an occult serious bacterial infection?**

**A:** A small proportion of these infants and young children will have an occult bacterial infection, such as an occult urinary tract infection, pneumonia, bacteremia or even early bacterial meningitis. These are defined as SBIs, and occult UTI is the most common SBI, especially in the first two years of life.

**Q: Does immunizing children help prevent SBIs?**

**A:** There is a very low rate of bacteremia in children with two or more doses of the *Haemophilus influenzae* type b and pneumococcal conjugate vaccine. In Canada, the Haemophilus vaccine is given at two, four, six, and 18 months, and the pneumococcal vaccine is given at two, four, and 12 months.



**Ah-Ha!**

For the child with a fever without a source, be sure to take a complete history and to undress the child completely when performing a thorough physical exam. Pay particular attention to the following points on history and physical exam:

**History:**

- Duration of fever
- Recent surgeries
- Underlying medical co-morbidities
- Previous infections
- Immunization status

**Physical exam:**

- A careful assessment of the vital signs
- Behaviour and mental status
- Meningeal signs and fontanelles
- If the child is at an ambulatory stage of development, watch the child walk and look for a limp
- A careful abdominal exam
- A careful skin exam
- A careful joint exam

**Q: What are the five most common sources of fever in a child without an obvious source for their fever after initial assessment?**

**A:** These are defined by the **LUCAS** mnemonic:

- **L**ungs
- **U**rine
- **C**NS
- **A**bdomen
- **S**kin



## Pediatric Assessment of Appearance

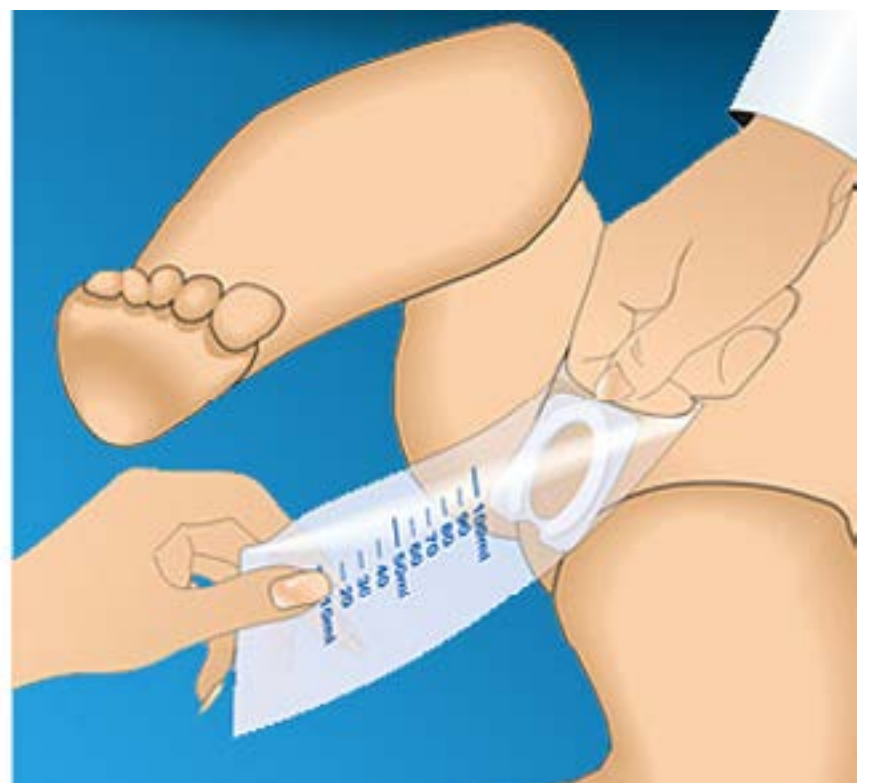
Element	Explanation
<b>Tone</b>	Is he/she moving around or resisting examination vigorously and spontaneously? Is there good muscle tone?
<b>Interactability</b>	How alert is he/she? How readily does a person, object, or sound distract or draw attention? Will he/she reach out, grasp, and play with a toy or new object, such as a penlight or tongue depressor?
<b>Consolability</b>	Can he/she be consoled or comforted by the caregiver or by the clinician?
<b>Look/gaze</b>	Can he/she fix her gaze on the clinician's or caregiver's face, or is there a "nobody home," glassy-eyed stare?
<b>Speech/cry</b>	Is his/her speech/cry strong, and spontaneous, or weak, muffled, or hoarse?

**Q: Is this 18-month-old male with a four-day history of fever at risk for a UTI?**

**What are the risk factors for UTI in the pediatric population?**

**A:** Yes, he is at risk. The following are risk factors for UTI:

- Females < 24 months
- All males < six months
- Uncircumcised males < 24 months
- Fever for more than two days
- Fever > 39°C
- History of previous UTI



**Q: Does this 18-month-old male with a four-day history of fever need testing for a UTI? How do you decide which children with fever to test for a UTI?**

**A:** Yes, this child does require testing for a UTI as he has multiple risk factors.

**< Three months:**

Get a urine sample for all babies with fever without a source

**Three to 24 months:**

Check all girls; check uncircumcised boys if  $\geq$  one risk factor and circumcised boys if  $\geq$  two risk factors

**> 24 months:**

Check all girls; check all symptomatic uncircumcised boys and circumcised boys with several symptoms of UTI

**Q: You tell the parents you would like to get a urine sample, and they immediately express concern that they don't want their child to have a catheter placed. How do you get a urine sample in this situation?**

**A:** Your investigation of this child could begin with a urine bag specimen. In general, the following principles apply when getting a urine sample.

**< Two months:**

Obtain urine sample by catheterization and send every sample for a culture (as the urinalysis may be normal with a true infection)

**From two months until toilet trained:**

Bag urine is acceptable to screen by microscopy; if positive (i.e.,  $> 10\text{--}20$  WBCs/hpf), a catheter sample is necessary.

**Toilet trained:**

Obtain a mid-stream urine sample after adequate cleaning of the genitals



### **Clinical Pearl:**

One study describes a safe, quick, and effective technique to obtaining a midstream urine sample. Twenty-five minutes after feeding, simply hold the baby upright, gently tap on the bladder for 30 seconds, then massage the sacrum for 30 seconds. Both stimulation manoeuvres are repeated until micturition starts.

### **Q: In what way can the urine dipstick be deceptive in children who aren't toilet trained?**

**A:** The urine dipstick relies on leukocyte esterase and nitrites as an indirect measure of pyuria and bacteriuria. The urine needs to be “incubating” in the bladder for about four hours to become positive on the dipstick. So, the child who isn't toilet trained is urinating too often (more frequently than every four hours) for the dipstick to become positive when an infection is present.

**Case continued:** Let's go back to our case of the 18-month-old uncircumcised male. We end up getting a urine bag specimen. There are 40–50 WBCs/hpf, so we proceed to get a urine sample by catheterization and send it for a urinalysis. The results come back with 30–40 WBCs/hpf, suggestive of a UTI. As you are looking up the appropriate antibiotic dose, you wonder about the child's disposition.

### **Q: Which children with UTI need to be admitted to hospital?**

**A:**



In general, children < two months of age with a UTI should be admitted to hospital. Well-appearing children > two months old can usually be discharged home on antibiotics with good follow-up, provided they do not show any evidence of dehydration and have reliable caregivers.

**Q: The parents ask whether their child has a problem with his kidneys or bladder that predisposed him to a UTI. What sort of follow-up should this 18-month-old male with a first-time UTI have?**

**A:** All children < two years of age with a first-time UTI should have an outpatient ultrasound to look for vesico-ureteral reflux and structural anomalies. A voiding cysto-urethrogram (VCUG) is no longer recommended for children with a first-time UTI.

**Q: What antibiotic options do you have for treating this child with a UTI?**

**A: Treatment of pediatric UTI:** Antibiotic options depend on local antibiotic resistance patterns, however, in our experts' catchment area (Ottawa)

- **In hospital:** IV ampicillin and gentamicin
- **Outpatient:** Cephalexin for most, or cefixime for infants two to six months old, or for those you are worried have a complicated UTI or urinary tract abnormalities



**Clinical Tools:**

[Click here for the Canadian Paediatric Society Guidelines on UTI in children](#)

## CASE 3: PNEUMONIA STRIKES

You are seeing a four-year-old female with a six-day history of a runny nose, cough, and fatigue. She was brought to your ED because she has had a fever for the past three days. She is otherwise healthy. On examination, she appears tired but non-toxic. She has a temperature of 40.0°C, a respiratory rate of 30, a heart rate of 130, and a blood pressure of 110/70. She has mild increased work of breathing.

**Q: You are considering a diagnosis of pneumonia. What are the factors on history, physical examination, and blood work that make this diagnosis more likely?**

**A: History:**

- Upper respiratory infection for several days followed by onset of fever
- Fever for  $\geq$  five days
- Cough for  $\geq$  10 days
- Temperature  $\geq$  40°C

**Physical Exam:**

- Increased work of breathing
- Tachypnea

**Investigations:**

- WBC count  $\geq$  20,000



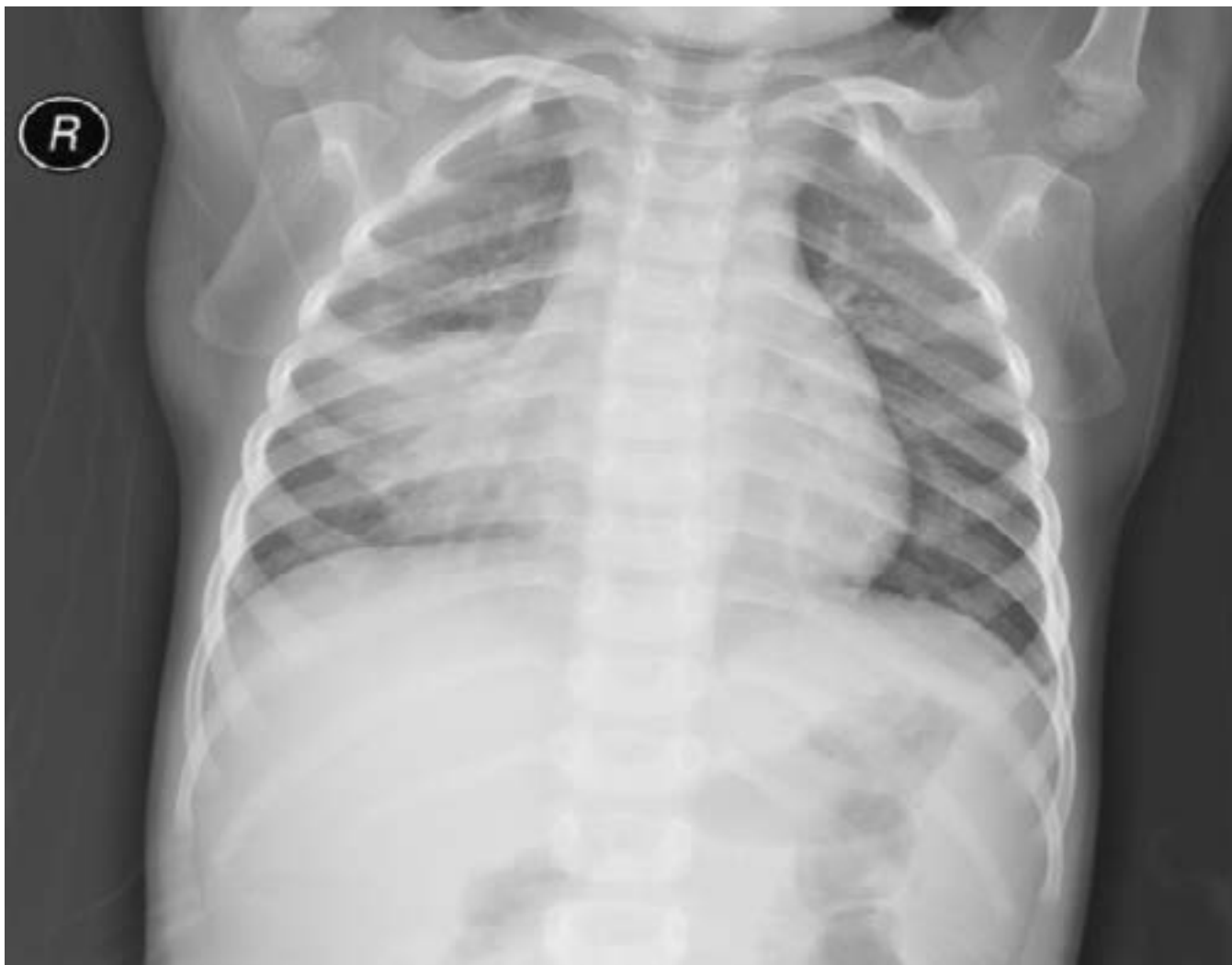**Clinical Pearl:**

Carefully examine the patient for “quiet tachypnea.” Children with quiet tachypnea will remain tachypneic after correcting the respiratory rate for the fever (as described above)—this may indicate an underlying pneumonia.



**Q: Other than the mild increased work of breathing, the rest of your physical exam is normal. Does this four-year old girl warrant a chest X-ray?**

**A:** Yes, she should have a chest X-ray (see below) because she has multiple factors that make the diagnosis of pneumonia more likely. Despite the fact that most pediatric pneumonias are viral in origin, we are unable to accurately differentiate between viral and bacterial causes based on the X-ray appearance alone. It is therefore prudent to start antibiotics in all children who have an infiltrate on chest X-ray that is consistent with pneumonia.



**Q: Does this child require blood work and/or blood cultures? What are the indications for blood work and blood cultures in pediatric fever without a source?**

**A:** A well-appearing, immunized child with a fever typically does not need blood work or cultures. While C-reactive protein (CRP) and pro-calcitonin may be helpful in risk-stratifying patients with fever without a source, this hasn't become a standard of practice, and the availability of pro-calcitonin is limited.



## CASE 4: THE FEBRILE NEONATE

A two-week-old female born at term is brought into your ED with a 24-hour history of fever. No source can be identified on history or physical exam. The child is alert but has a rectal temperature of 39.1°C.

**Q: What sort of workup does this infant need?**

**A:** This patient needs a full septic workup. Infants in the first month of life have the highest rate of SBI out of any time in childhood, and therefore they represent a high-risk group.

A full septic workup includes:

- CBC
- Blood cultures
- Urinalysis collected by catheter
- Urine culture
- CSF sampling (send for: cell count, culture, Gram stain, protein, glucose, and viral studies)

**Q: This infant is started on IV antibiotics. Your resident asks you whether the child requires acyclovir, in case the child has herpes simplex encephalitis (HSV). What do you tell your resident?**

**A:** If you suspect meningitis based on physical exam or lumbar puncture results, start acyclovir. This is especially important in children < 14 days of age, as the rate of HSV meningitis is highest in this age group. HSV can also cause hepatitis and pneumonitis, so check for these if you are suspicious of HSV meningitis.

## CASE 5: THE PARTIAL SEPTIC WORKUP

A two-month-old male born at 36 weeks is brought in with a 12-hour history of fever. He is unvaccinated and he is circumcised. No focus is identified on history or physical exam. He appears non-toxic and has a rectal temperature of 38.6°C, and the rest of the vitals are normal.

**Q: How do you correct for age when it comes to premature infants who present with fever to the ED?**

**A:** When calculating age for the purposes of infection, you should use the chronological age; however, premature babies with a complex medical history should be thought of as high risk.



**Q: What sort of work-up does this two-month-old boy require?**

**A:** This child will require at least a partial septic workup and then be assessed regarding low-risk criteria to determine if any further investigations are needed.

For children between 29–90 days of age, there are many criteria for the work-up of fever without a source. Our experts recommend using the low-risk criteria from the American Academy of Pediatrics. If these criteria are met, the child has an approximate risk of 1.5% of developing an SBI. These children may be safely discharged home if they have reliable parents and follow-up is available within 24 hours.

Low-risk criteria (American Academy of Pediatrics):

- No obvious source of infection
- No complex past medical history
- WBC count between 5–15,000
- Normal urinalysis (<10 WBCs/hpf)
- Normal stool WBC count if they have diarrhea
- Normal chest X-ray if there are respiratory symptoms



### **Clinical Tools:**

[Click here for a review article of the American Academy of Pediatrics guidelines on fever without a source.](#)



## **Putting it All Together: Workup Decisions in Pediatric Fever Without a Source**

**A full septic workup including LP is recommended for infants younger than 28 days** because they have the highest risk of SBI.

- This includes routine blood work and culture, urinalysis and culture, and lumbar puncture (cell count, protein, glucose, culture, Gram stain and culture, and viral studies).

**For infants ranging in age from 29 days to 90 days**, use the American Academy of Pediatrics low-risk criteria.

- If they are well appearing, with no obvious source of infection, no complex past medical history, normal laboratory criteria (WBC count, normal urinalysis, and normal stool white count if diarrhea is present), they can usually be sent home if they have reliable parents and good availability for follow-up in 24 hours.
- These infants have a rate of SBI of about 1.5% (usually UTI), so be sure that urine is sent for culture in addition to urinalysis.



### **Comments?**

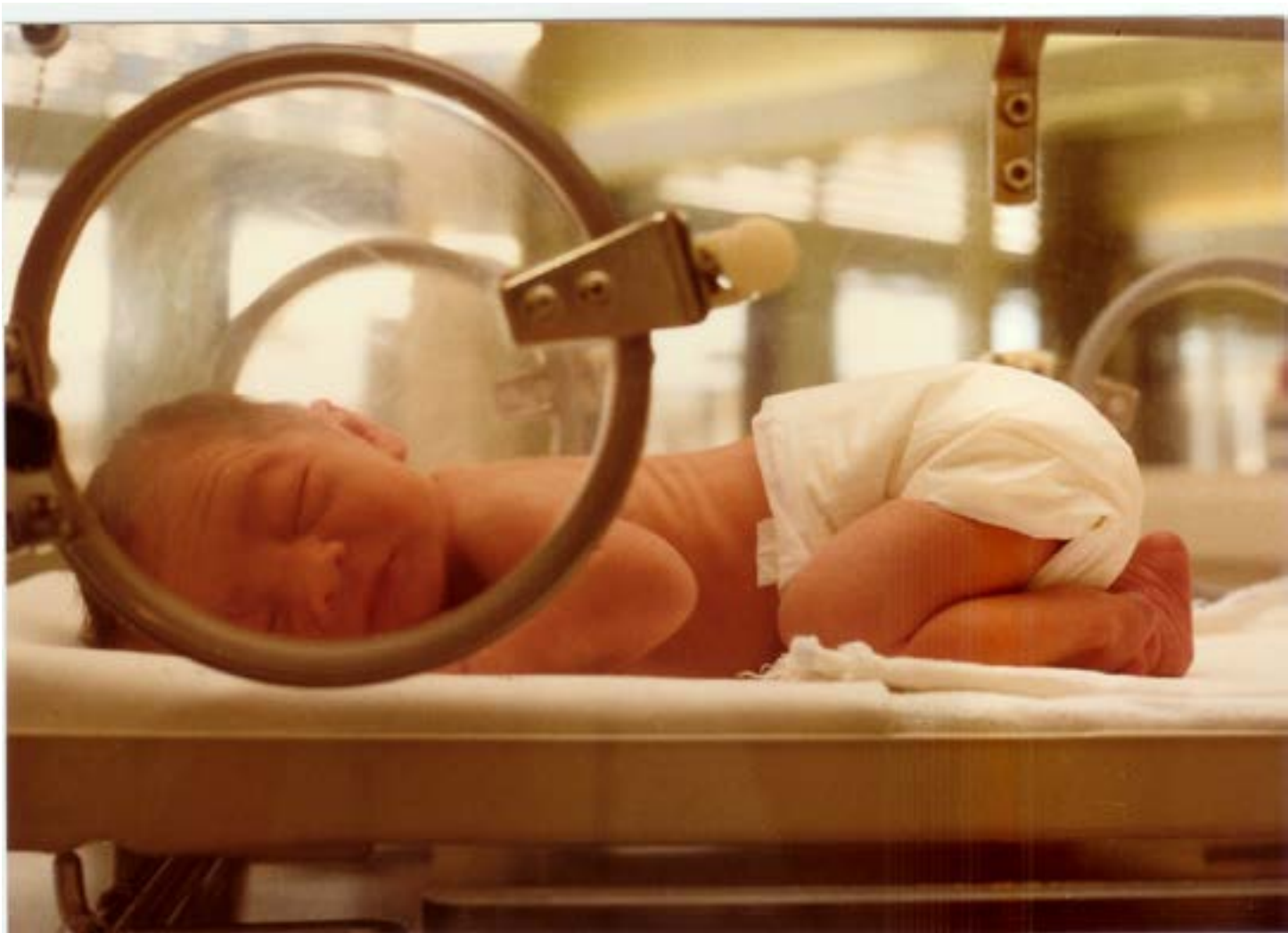[Click here to leave a comment or to listen to this podcast.](#)

## **KEY REFERENCES:**

1. Baraff LJ. Management of infants and young children with fever without source. *Pediatr Ann.* 2008; Oct;37(10):673-679.
2. Robinson JL, Finlay JC, Lang ME, Bortolussi R,. Urinary tract infection in infants and children: Diagnosis and management. *Paediatr Child Health.* 2014; 19(6):315-319.
3. Shaikh N, Monroe NE, Lope J, et al. Does This Child Have a Urinary Tract Infection? *JAMA*, 2007; 298(24):2895-2904.
4. Subcommittee on Urinary Tract Infection, Steering Committee on Quality Improvement and Management. Urinary Tract Infection: Clinical Practice Guideline for the Diagnosis and Management of the Initial UTI in Febrile Infants and Children 2 to 24 Months. *Pediatrics.* 2011; 128(3):595-610.
5. Wilkinson M, Bulloch B, Smith M. Prevalence of occult bacteremia in children aged 3 to 36 months presenting to the emergency department with fever in the post pneumococcal conjugate vaccine era. *Acad Emerg Med.* 2009; Mar;16(3):220-225.

# CHAPTER 2: SEPSIS & SEPTIC SHOCK

[LISTEN TO THE PODCAST WITH SARAH REID AND GINA NETO HERE](#)



## Objectives

1. Recognize sepsis and septic shock in a pediatric patient
2. Understand the differences between the presentation, diagnosis, and treatment of septic shock in children compared with adults
3. Review fluid management, antibiotic use, and vasopressor options in pediatric sepsis and septic shock

## **CASE 1: SICK OR NOT SICK, THAT IS THE QUESTION**

A seven-day-old boy is brought to the ED with poor feeding and fewer wet diapers for the past day. He was born via uncomplicated vaginal delivery at term, and went home from the hospital with his mother within 24 hours. He is exclusively breastfed and had been feeding well up until last night, when he became disinterested in feeding. On examination the child is sleeping but rouses easily. His vitals are: temperature 37.5°C (rectal), heart rate 120, respiratory rate 40, and oxygen saturation 96% on room air.



**Q: As you hear this story, what other things are you thinking about asking on history or looking for on physical exam?**

**A:** Given the story, this is potentially quite a concerning situation. Pay close attention to any change in a newborn's normal pattern of behaviour, as this can indicate a possible serious illness. In this age group the signs and symptoms of sepsis can be quite vague and non-specific. Common signs of neonatal sepsis that you should think to look for or ask about include:

- Jaundice
- Hepatomegaly
- Poor feeding
- Vomiting
- Abdominal distension
- Diarrhea



**Q: You make note of the newborn's vital signs and start your physical exam. You remember that the normal vital signs for children depend on their age and you wonder if these are normal. What are the normal vital signs in pediatric patients?**

**A:**



Age	Heart Rate (Beats/Min)	Blood Pressure (mm Hg)	Respiratory Rate (breaths/min)
Premie	120-170	55-75/35-45	40-70
0-3 mo	100-150	65-85/45-55	35-55
3-6 mo	90-120	70-90/50-65	30-45
6-12 mo	80-120	80-100/55-65	25-40
1-3 yr	70-110	90-105/60-75	20-30
3-6 yr	65-110	95-110/60-75	20-25
6-12 yr	60-95	100-120/60-75	14-22
>12 yr	55-85	110-135/65-85	12-18

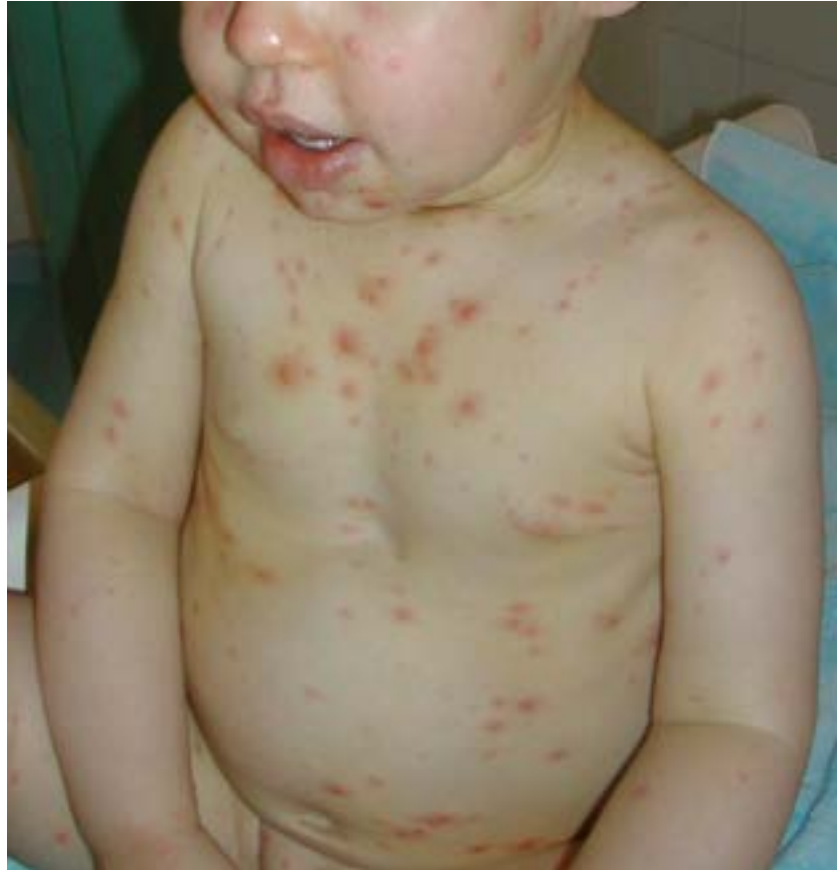### Correcting Vital Signs for Fever

In febrile children, the heart rate increases by approximately 10 beats per minute and respiratory rate increases by five breaths per minute for every 1°C or 1.8°F of fever over 38°C.

In this case, the only particular concern is that the young child is not feeding as well as previously. Given that the rest of the history and a full physical examination are normal, this child is likely not septic but perhaps a bit dehydrated. Supplementation or strategies to aid feeding should be discussed with the family. Given that the family is coping well, is reliable and there are no other concerns, the child can be discharged home with a plan for follow-up and clear discharge instructions to return if the child continues a poor feeding pattern, develops a fever, or becomes lethargic or irritable, or if the parents concerned.

## CASE 2: FROM BAD (AND ITCHY) TO WORSE

A seven-month-old girl has had chicken pox for three days. She develops a temperature of 38.7°C and is crying constantly, and one of the spots on her abdomen has an area of increased redness around it. She was seen at a walk-in clinic and given antibiotics. However, when she was brought home her mother noted her to be limp and unresponsive. She called 911.



**Q: EMS had called you prior to their arrival at the ED with a brief history. As you prepare for the patient's arrival, you remind yourself of the red flags, or risk factors, for sepsis in the pediatric population. What do you listen for on history or look for on physical exam?**

**A:** It can be difficult to recognize sepsis because the signs and symptoms can be so vague. However, there are a few red flags you should look for in every potential case. These include:

1. Age younger than one year, and early adolescence (10–14 years); in particular, children younger than one month old have a high risk
2. Unexplained tachycardia (after correction for fever)
3. Clinical signs of poor perfusion (prolonged capillary refill, lethargy, irritability)
4. Conditions that predispose to sepsis: neuromuscular disease, immunocompromised, respiratory conditions, cardiac disease
5. Recent surgery



In the ED, the patient's vitals are: temperature 39.4°C, heart rate 168, respiratory rate 44, blood pressure 70/35, and oxygen saturation 94%. The child appears ill and is difficult to rouse. She is mottled and has a capillary refill of five seconds.

**Q: You pause during your examination of this child as you recognize that she is sick and you begin to worry. What about her presentation is worrying you?**

**A:** This case describes an extremely unwell child. She is poorly perfused and has an abnormal level of consciousness. Her heart rate is higher than would be expected for her temperature, and her blood pressure is low for her age.

**Case continued:** As you make note of these things, you are recognizing the signs of sepsis: tachycardia out of proportion to the fever, tachypnea, and poor perfusion (capillary refill, lethargic, irritability).



Suspicion of sepsis is a clinical judgment. Up to one-third of patients with clinical sepsis do not fulfill the classic research diagnostic criteria. Severe sepsis is time-critical, so have a high index of suspicion, and initiate sepsis investigations and treatment until sepsis is excluded.



**Pitfall:**

In this case the child is frankly hypotensive, which can be a pre-morbid sign in pediatric sepsis. Hypotension is a late sign of pediatric septic shock and imminent arrest. Do NOT wait for hypotension to make the diagnosis of septic shock.

**Q: You finish your physical examination and are anxious to start your management and treatment. What is your first priority in managing this patient?**

**A:** The first priority in managing the critically ill child is obtaining vascular access to start fluid resuscitation. Two peripheral intravenous lines should be placed. If you cannot obtain IV access within the first 60 seconds, put in an intraosseous line.



## Intraosseous Access

Intraosseous (IO) access can be used in all ages, even in awake patients. Studies show that the pain from the IO comes more from the actual infusion than from the insertion. To reduce pain, consider infiltrating lidocaine into the bone prior to the infusion of fluids. The possibility of pain should not cause hesitation in establishing IO access. The preferred IO sites in kids are the proximal tibia, distal femur, and proximal humerus.

You can administer the same agents through an IO as an IV (fluids, antibiotics, vasopressors).

[Click here to listen to EM Cases Episode 61 for some great pearls and pitfalls on intraosseous line placement.](#)

**Q: You secure a line and start to run your fluids. What specifically are you going to run?**

**A:** Fluids, typically a crystalloid such as normal saline or Ringer's lactate, are given in boluses of 20 cc/kg, repeated up to a total of 60 cc/kg within the first hour, as long as there are no signs of hepatomegaly, crackles in the lungs, or sonographic evidence of pulmonary edema, while monitoring the effects. For younger children (< two years of age) this is done by filling a 30–60 cc syringe with saline and manually bolusing. For older children, use a level 1 infuser. Adequate volume resuscitation is critical to prevent the child from crashing post-intubation or with positive-pressure ventilation.



### Caution:

Intubation and positive-pressure ventilation may increase intrathoracic pressure and decrease venous return, thus worsening shock. It is important to adequately volume resuscitate these kids before intubation to prevent them from crashing.



### **Clinical Pearl:**

A rapid and effective way to administer fluid boluses in children younger than two years of age is to fill large syringes with normal saline and push 20 cc/kg boluses as needed to a maximum of 60 cc/kg.

**Q: You know that early administration of antibiotics is essential in managing sepsis and septic shock. What antibiotic options do you have?**

**A:** For this patient, a reasonable choice of initial antibiotic therapy would be ceftriaxone 75 mg/kg.



### **Empiric Antibiotic Treatment by Age:**

#### **Children > 28 days of age who are normal hosts:**

- Vancomycin (15 mg/kg, maximum 1–2 g, for the initial dose) in areas with high MRSA prevalence
- Plus cefotaxime (100 mg/kg, maximum 2 g, for the initial dose) OR ceftriaxone (75 mg/kg, maximum 2 g, for the initial dose)
- Consider adding an aminoglycoside (e.g., gentamicin) for possible GU source, and/or piperacillin with tazobactam, clindamycin, or metronidazole for possible GI source

#### **Infants zero to 28 days of age:**

- Vancomycin (15 mg/kg for the initial dose) in areas with high MRSA prevalence
- Plus cefotaxime (50 mg/kg for the initial dose)
- Plus gentamicin (2.5 mg/kg for the initial dose)
- Plus ampicillin (50 mg/kg for the initial dose)
- Add acyclovir (20 mg/kg per dose) for suspicion of HSV infection

Note that local resistance patterns may dictate different antibiotic regimens.

**Q: The nurse has now also successfully drawn blood and asks what investigations you would like to order.**

**A:** General investigations for the child with sepsis are blood work for CBC, electrolytes, glucose, kidney function, blood gas, blood cultures, LFTs, ionized calcium, and lactate. Hypoglycemia is relatively common and should be identified early by bedside capillary blood analysis and then treated. In the undifferentiated septic patient, urine cultures are commonly done to identify a possible source. Clinical history guides imaging such as chest X-ray.

Hypocalcemia is commonly seen in critically ill children with sepsis, and it is recommended to treat hypocalcemia even in the absence of clinical manifestations such as seizures and cardiac arrhythmias.

Treat with calcium gluconate 10% 0.5-1 ml/kg up to 20 ml slowly over five minutes (calcium chloride 10% 0.1-0.2 ml/kg up to 10 ml can also be used, but should be given through a central line).



**Clinical Pearl:**

Check capillary glucose early and treat hypoglycemia with D10W 5 cc/kg.

**Q: Your patient received a total of 60 cc/kg of crystalloid fluids as well as an empiric dose of antibiotics. Her heart rate is now 120, blood pressure 80/50, respiratory rate 30. Her extremities are cool and she is mottled with a delayed capillary refill. What is your next move?**



**A:** She is now in fluid-refractory shock. If a patient has received a full 60 cc/kg of crystalloids and is still manifesting clinical signs of septic shock, it is time to consider inotropes/vasopressors. While the choice of initial vasopressor has traditionally been dopamine, current evidence suggests that epinephrine for “cold shock” or norepinephrine for “warm shock” are better choices. In this case, and in most children suffering from septic shock, the type of shock is cold shock, as apposed to warm shock that affects the vast majority of adults suffering from septic shock.



### **Inotropes in Fluid-Refractory Shock**

- Warm shock as seen in most adults in septic shock (warm extremities, flash capillary refill): norepinephrine 0.1-2 mcg/kg/min IV/IO infusion, titrate to desired effect
- Cold shock as seen in most children in septic shock (cool extremities, delayed capillary refill): epinephrine 0.1-1 mcg/kg/min IV/IO infusion, titrate to desired effect



### **Pitfall**

A common pitfall in the management of fluid-refractory septic shock is to delay the initiation of vasopressors when there is no central line in place yet. The lack of a central line should not delay the initiation of vasopressors, which can initially run through a peripheral IV or IO line.

**Q: What about securing the airway for this child in septic shock? When would you consider endotracheal intubation for pediatric patients in septic shock?**

**A:** Consider early intubation in fluid-refractory septic shock (after three boluses of 20 ml/kg IV/IO NS) or in any compromised airway.

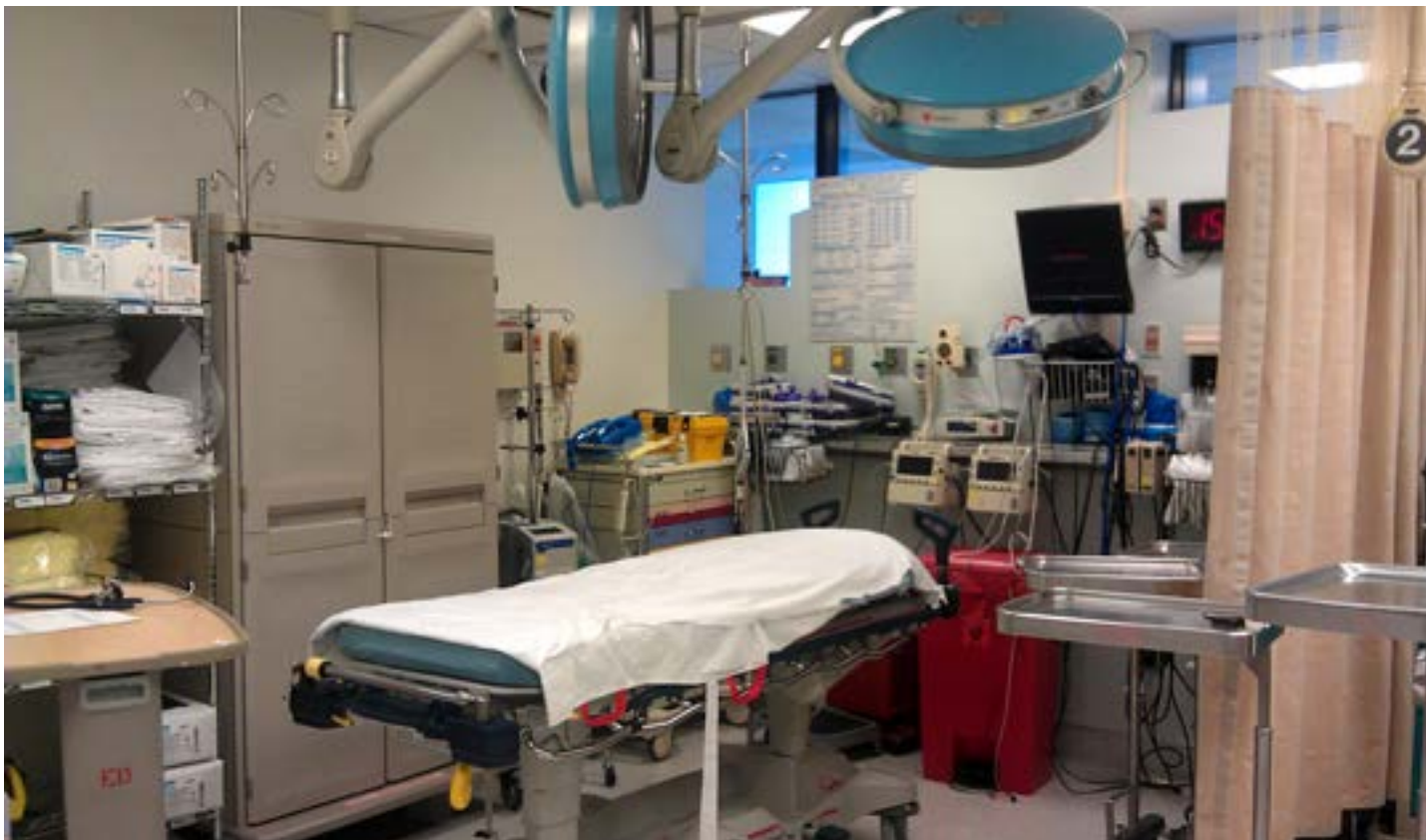Infants or neonates with severe sepsis are more likely to require early intubation. Again, intubation and mechanical ventilation increase intrathoracic pressure, which reduces venous return and leads to worsening shock. Therefore, fluid resuscitation must be done first.

**Case continued:** You start epinephrine and call your colleagues in the pediatric ICU to tell them about the patient and ask for their assistance. They thank you for your good work and arrive in the ED shortly to continue care of our young girl.



## CASE 3: SHOCKED

A nine-year-old girl is brought to the ED with a history of vomiting and diarrhea. Her heart rate is 140, respiratory rate 36, blood pressure 77/40, and temperature 37.8°C, and she is lethargic and difficult to rouse. She is treated with aggressive fluid resuscitation, after which her hemodynamic status does not improve.



**Q: You start to worry when her clinical status does not improve with aggressive fluids. What quick test is vital to obtain at this point?**

**A:** Up to 25% of children with septic shock will have adrenal insufficiency. Many of these patients will have concomitant hypoglycemia, so always check the serum glucose in septic children. Extremes in blood glucose in sepsis are associated with higher mortality in children.



### **Clinical Pearl:**

**ABC + DEFG = ABC and DON'T EVER FORGET GLUCOSE**

**Q: Her capillary glucose is 1.2 and she is treated with D10W 5 cc/kg IV. You then also start an epinephrine infusion, but her hemodynamic status does not improve much. What do you think is causing this, and what else could you try at this point?**

**A:** This patient is in catecholamine-resistant shock. Consideration should be given to administering systemic corticosteroids.



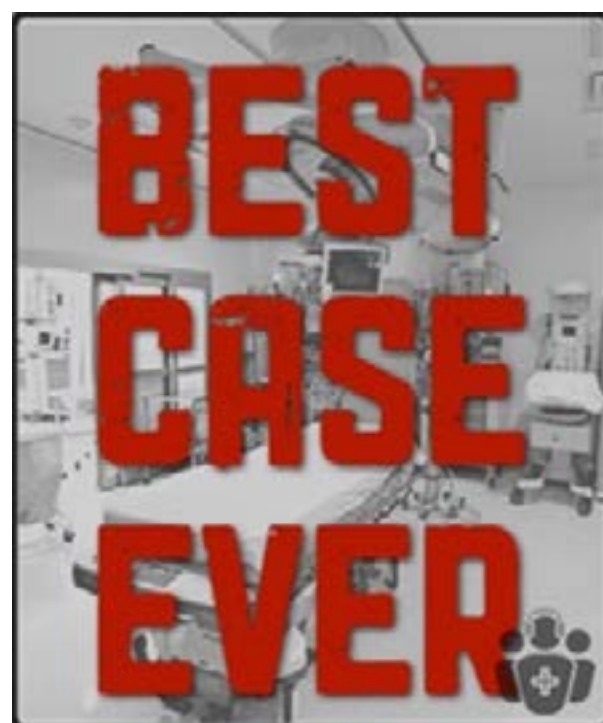
**Clinical Pearl:**

When a child is fluid refractory and catecholamine resistant in shock, think of adrenal insufficiency. Again, up to 25% of kids with sepsis will have adrenal insufficiency either from prior steroid use, from the cause of sepsis itself or from primary adrenal insufficiency. Treatment is hydrocortisone 2 mg/kg IV.

**Q: Great! You start systemic corticosteroids and continue your resuscitation. To stay on top of the resuscitation of this child, you must attempt to achieve certain goals. What markers of a successful sepsis resuscitation are you looking for?**

**A:** You are watching for the following:

- Capillary refill < two seconds
- Normal blood pressure
- Normal pulses with no differential between central and peripheral pulses
- Warm extremities
- Urine output > 1 ml/kg/hr
- Normal mental status
- Normal lactate

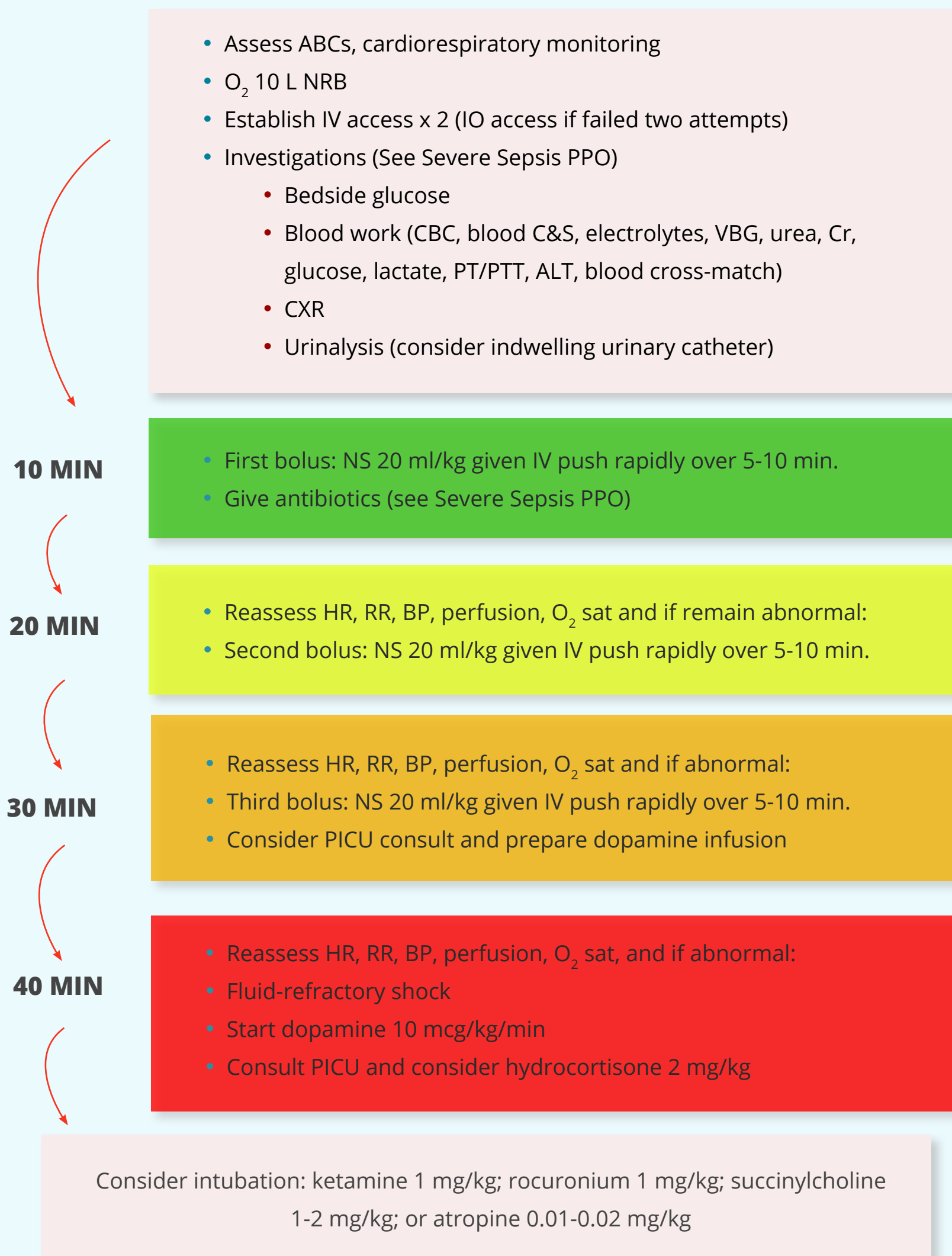


[Click here to listen to Dr. Reid's Best Case Ever for more helpful tips on sepsis and shock.](#)



## Putting it All Together: An Example of an Algorithm for Pediatric Septic Shock

*Children's Hospital of Eastern Ontario Algorithm for Septic Shock: Note that dopamine, although included in this algorithm, is no longer recommended as the initial vasopressor of choice in pediatric septic shock.*





## KEY REFERENCES:

1. Weiss SL, Parker B, Bullock ME, et al. Defining pediatric sepsis by different criteria: discrepancies in populations and implications for clinical practice. *Pediatr Crit Care Med*. 2012; July;13(4):e219-26.
2. Dieckmann R, Brownstein D, Gausche-Hill M (eds): *Pediatric Education for Prehospital Professionals*. Sudbury, Mass, Jones & Bartlett, American Academy of Pediatrics, 2000, pp 43-45.
3. Davies P, Maconochie I. The relationship between body temperature, heart rate and respiratory rate in children. *Emerg Med J*. 2009 Sep;26(9):641-3. doi: 10.1136/emj.2008.061598.
4. Van de Voorde P1, Emerson B, Gomez B, et al. Paediatric community-acquired septic shock: results from the REPEM network study. 2013, *Eur J Pediatr*. 2013; May;172(5):667-74.
5. Dellinger RP. Surviving Sepsis Campaign: International Guidelines for Management of Severe Sepsis and Septic Shock: 2012. *Intensive Care Med*. 2013; 39:165-228.
6. Sá RA, Melo CL, Dantas RB, Delfim LV. Vascular access through the intraosseous route in pediatric emergencies. *Rev Bras Ter Intensiva*. 2012; 24(4):407-414.
7. Weiss SL, Fitzgerald JC, Balamuth F, et al. Delayed antimicrobial therapy increases mortality and organ dysfunction duration in pediatric sepsis. *Crit Care Med*. 2014; 42(11):2409-17
8. Shekerdemian L, Bohn D. Cardiovascular effects of mechanical ventilation. *Arch Dis Child*. 1999; 80:475-480.
9. Han YY, Carcillo JA, Dragotta MA, et al. Early reversal of pediatric-neonatal septic shock by community physicians is associated with improved outcome. *Pediatrics*. 2003; Oct;112(4):793-9.
10. Butt W. Septic shock. *Pediatr Clin North Am*. 2001; Jun;48(3):601-25.
11. Gaines NN, Patel B, Williams EA, Cruz AT. Etiologies of septic shock in a pediatric emergency department population. *Pediatr Infect Dis J*. 2012; Nov;31(11):1203-5.
12. Paul R, Melendez E, Stack A, et al. Improving adherence to PALS septic shock guidelines. *Pediatrics*. 2014; 133(5):1358-1366.
13. Aneja R, Carcillo JA. What is the rationale for hydrocortisone treatment in children with infection-related adrenal insufficiency and septic shock? *Arch Dis Child*. 2007; Feb;92(2):165-9



### Comments?

[Click here to leave a comment or to listen to this podcast.](#)

# CHAPTER 3: PAIN MANAGEMENT

[LISTEN TO THE PODCAST WITH SAMINA ALI AND ANTHONY CROCCO HERE](#)



## Objectives

1. Develop a systematic approach to assessing pain in the pediatric patient
2. Develop a step-wise approach to treating pediatric patient pain in the emergency department
3. Develop an approach to communicating with and treating a pediatric patient who is anxious about a sensitive physical exam or invasive procedure
4. Develop an appreciation of moderate to severe pain treatment modalities in a pediatric patient (e.g., IM, IN, IH)
5. Develop an approach to using different therapeutic agents (acetaminophen, ibuprofen, morphine, fentanyl, ketamine, nitrous oxide)

## CASE 1: PEDIATRIC PAIN ASSESSMENT & TREATMENT APPROACH

A five-year-old boy presents to your emergency department with a 24-hour history of peri-umbilical abdominal pain, vomiting, and low-grade fever. At triage he is given ibuprophen 10 mg/kg po for the pain. When you examine him, he appears to be in a significant amount of pain, and has RLQ rebound tenderness and guarding.



You make the patient NPO, order an IV, give ondansetron for the vomiting, and organize an ultrasound to confirm your suspicion for appendicitis.

**Q: Why is effective ED pain management in children important, and what are the consequences of untreated pain in children?**

**A: Consequences of untreated and undertreated pediatric pain:**

### Short-term detrimental effects:

1. Extended procedure duration
2. Delay in diagnosis
3. Increased length of stay
4. Parental concern and dissatisfaction
5. Slower surgical healing
6. Emotional trauma and suffering

### Long-term detrimental effects:

1. Infant pain may adversely change neural pain processing
2. Avoidance and heightened sensitivity to future medical care
3. Fear and increased pain experienced with future health-care evaluation



Developing a systematic, team-based approach to assessing and managing pediatric pain in a busy emergency department will save time overall.



### Pitfall:

Most clinicians underestimate the extent of pain in a pediatric patient, and do not reassess their therapeutic interventions frequently enough to determine effectiveness.



### Clinical Pearl:

Use of clinical assessment tools can be expedited and standardized by having a pocket or electronic copy with the treating physician, on the chart, or completed and recorded by triage.

**Q: What are the best evidence-based tools to use for pain assessment for this five-year old boy, and in older and younger pediatric patients?**

**A:**



### < Four years old: FLACC Scale

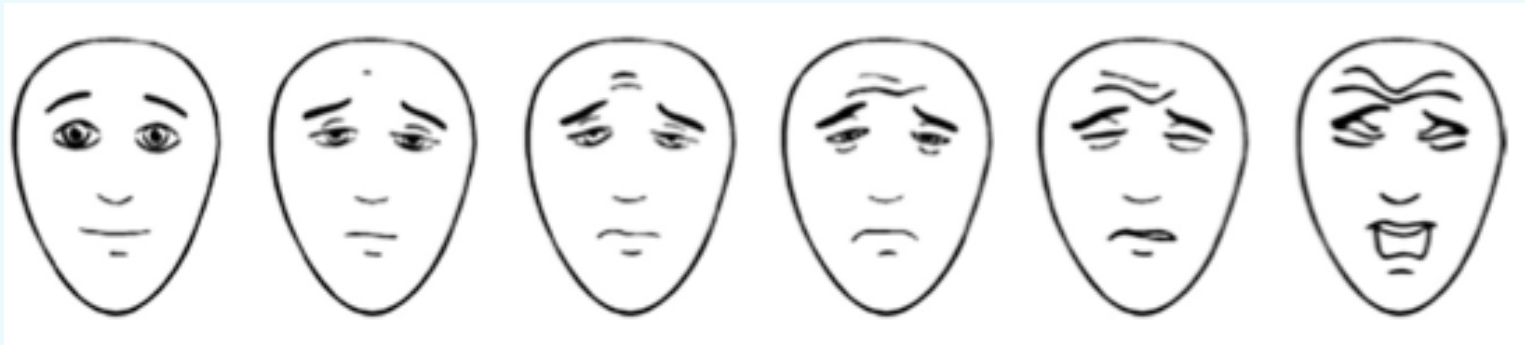FLACC Scale (out of a total score of 10)

Categories	0	1	2
Face expression	No special expression	Slight frowning, grimace	Mop, teeth clenching
Legs	Normal position	Tight, stressful	Kick at anybody
Activity	Calm	Turn around	Hop off, jerk
Cry	No cry	Groan, moaning	Shouting cry, with screams
Consolability	Relaxed	Consoled with hug or touch	Never consoled

FLACC=Face, leg, activity, cry, consolability



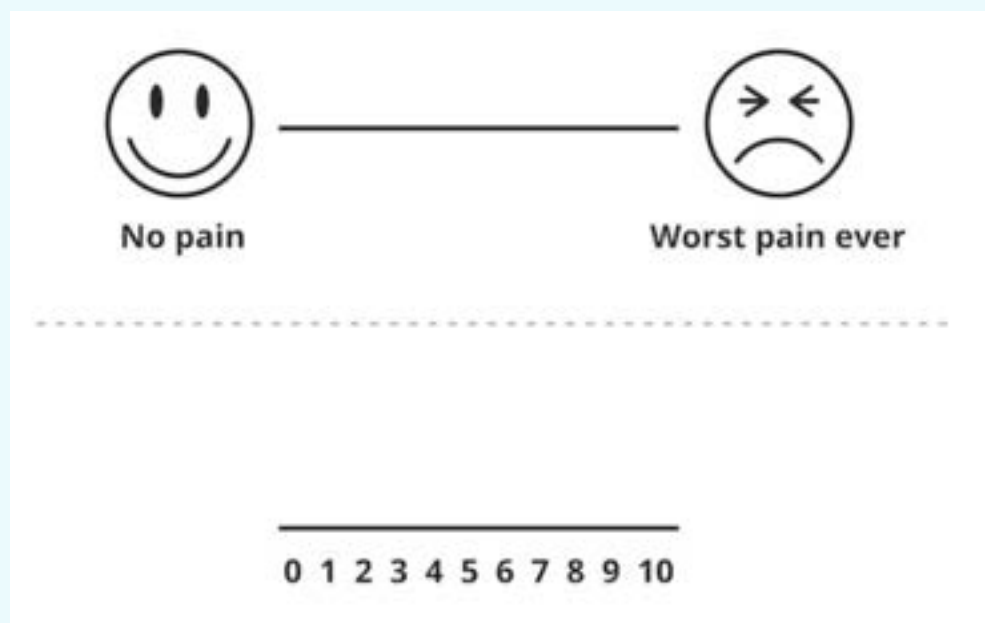
### Four to Eight Years Old: Faces Pain Scale-Revised



The Faces Pain Scale has been validated in different ethnic populations. This may make it more generalizable than the [Wong-Baker FACES Pain Rating Scale](#) due to differing cultural practices and implications with crying; i.e., not all cultural groups express pain and suffering with tears.



### > Eight Years Old: Visual Analog Scale



### Pitfall:

Vital signs do not correlate with pain severity or improvement in pain scores. Assuming minimal pain because the vital signs are normal is a common pitfall.

**Q: What can be done to treat the pain of this five-year-old boy with suspected appendicitis in a timely manner?**



1. Triage is a great place to start. Nurse-driven protocols may expedite pediatric pain identification and management. Alternatively child life specialists, if available, can assist in this process.
2. Many Canadian hospitals employ oral acetaminophen or ibuprofen triage-initiated pain protocols. Some hospitals employ physician-approved intranasal fentanyl and oral opioids at triage.



**Pitfall:**

[One study](#) found that the average wait time for pain treatment of non-musculoskeletal presentations to be approximately two hours.



**Your comments?**

[What is the strategy in your ED to improve the timeliness of pain treatment?](#)

**Q: What analgesic options would you recommend for this five-year-old boy with non-musculoskeletal pain?**

**A:** Treatment of undifferentiated abdominal pain with analgesics does not lead to more complications or negatively affect the accuracy of the physical exam. This is a common myth that has been debunked in the literature and that delays appropriate pain management.

**Graded Analgesic Options for Pain Anticipated to Last Hours**



**Mild-Moderate Pain**

- |                              |              |
|------------------------------|--------------|
| 1. Ibuprofen                 | 10 mg/kg Q6h |
| 2. Acetaminophen             | 15 mg/kg Q4h |
| 3. Ibuprofen + acetaminophen |              |





The combination of ibuprofen + acetaminophen can be an effective pain management tool in the emergency department for pediatric patients. In adults, it has been shown to be superior to either one alone. While it has widespread adoption and anecdotally positive results, it has not been studied adequately in children.



Ibuprofen has been [shown](#) to be superior to and have a longer duration of action than acetaminophen for mild-moderate pain anticipated to last hours.

**Q: You give this five-year-old boy ibuprofen 10 mg/kg po and acetaminophen 15 mg/kg po, and an hour later the nurse calls to tell you the boy is scoring high on the Faces Pain Scale–Revised. What’s your next pain management move?**

**A:**



### **Moderate-Severe Pain**

- |                                |     |  |
|--------------------------------|-----|--|
| 1. Ibuprofen +/- acetaminophen | AND |  |
| 2. Morphine oral suspension    | OR  | 0.2-0.5 mg/kg PO (max 15 mg) Q4-6H     |
| 3. Morphine IV*                |     | 0.1 mg/kg IV push titrated to response |

- IV morphine is recommended for severe pain that is expected to last for hours to days, especially for patients who have been deemed NPO.
- IV morphine is effective in both musculoskeletal and non-musculoskeletal pain when ibuprofen +/- acetaminophen is not providing adequate pain control.
- IV morphine should be given as an IV push (not in a minibag) to facilitate frequent reassessment and titration to effect.
- Physicians who may be hesitant to treat the pediatric population with opioids, or who do not encounter this population frequently, may begin with morphine 0.05 mg/kg IV push. It is essential to reassess the patient’s pain in 10 minutes to titrate appropriately.



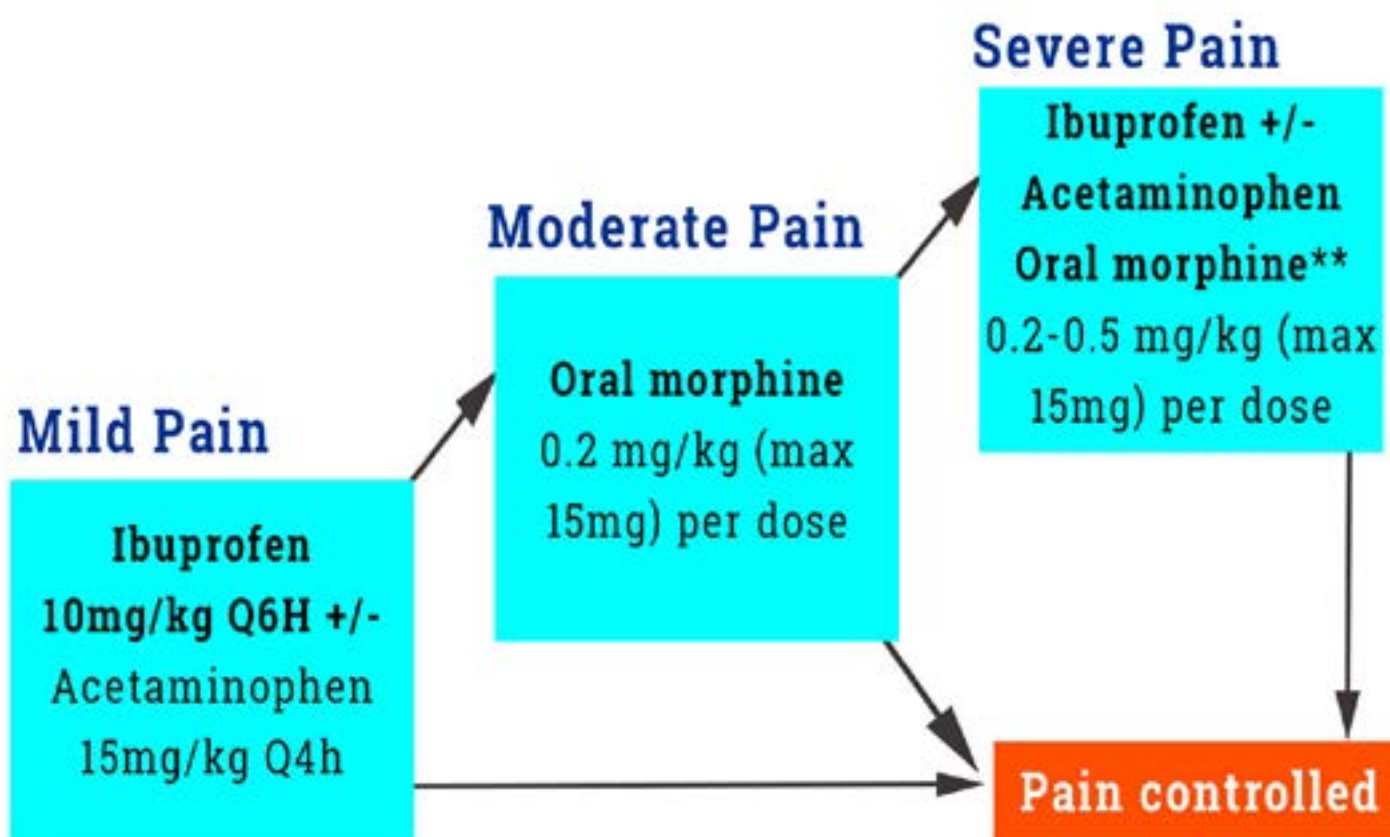
**Caution:**

An oxygen saturation monitor is recommended for children receiving multiple doses of opioids (i.e., with the second dose) to monitor for respiratory depression.

**Case continued:** You get the ultrasound report back that shows no signs of appendicitis, and when you re-examine the boy he scores low on the Faces Pain Scale-Revised and is no longer tender to palpation. You decide to send the patient home and to have him return for a repeat ultrasound the next day.

**Q: What analgesic medications will you suggest to his parents for home?**

**A: Step-Wise Ladder Approach to Outpatient Pain Management**





### Caution:

Outpatient use of acetaminophen concurrently with ibuprofen may lead to dosing errors and inadvertent overdose. Therefore, it should be considered only for children with parents who:

- Are reliable
- Have been **counselled thoroughly**
- Show an appreciation of medication scheduling
- Will commit to **documenting** the drug dosing at home

**Q: How will you counsel the parents of this five-year-old boy regarding the opioid analgesic prescription that you may give them?**

**A:** Often there is considerable parental concern for children being discharged with an opioid prescription. Pre-emptive counselling of parents may include:

- Providing the evidence for and the efficacy of opioid analgesia in children
- Explaining that opioid addiction is rare in children who are being treated for pain
- Reviewing important side effects with patients, including respiratory distress, drowsiness, and constipation
- Having the parents commit to documenting medication regimen
- Having the parents commit to keeping opioid medication (along with all other medications in the home) in a safe place away from children



### Clinical Pearl:

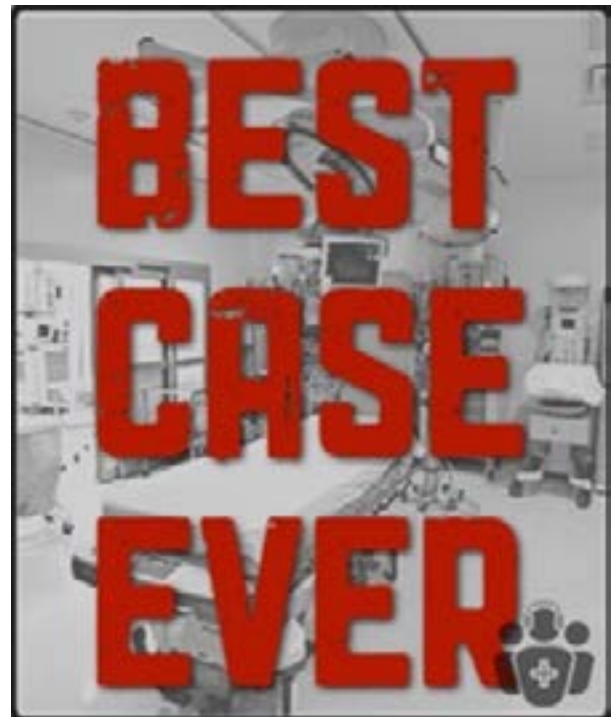
Give the first oral dose in the emergency department prior to discharge. This allows for a better transition from IV to PO pain coverage. It also provides some observation time for an opioid-naive patient receiving it orally.





### **Pitfall:**

Codeine is a pro-drug that gets converted into morphine. Some people are ultra-rapid metabolizers of codeine, and receive a huge surge of morphine systemically along with its adverse effects. Its use in the pediatric population and in breastfeeding mothers should be avoided. It has been linked to adverse effects, [including death](#) (see the story of [Tariq and Rani Jamieson](#)).



[\*For another illustration of the dangers of codeine with ultra-rapid metabolizers listen to Dr. Anthony Crocco's Best Case Ever: The Neonatal Lazy Feeder.\*](#)

---

## **CASE 2: PEDIATRIC PAIN ASSESSMENT & TREATMENT APPROACH**

A three-year-old girl is sent to your ED from one of your community pediatricians with a four-day history of fever and maculo-papular rash. She fulfills the criteria for Kawasaki disease. The pediatrician asks you to place an IV in the ED so that IV IG can be given.

You get a call from the nurse telling you that they're having a difficult time getting the IV. When you enter the room, the child looks terrified and is not co-operating.

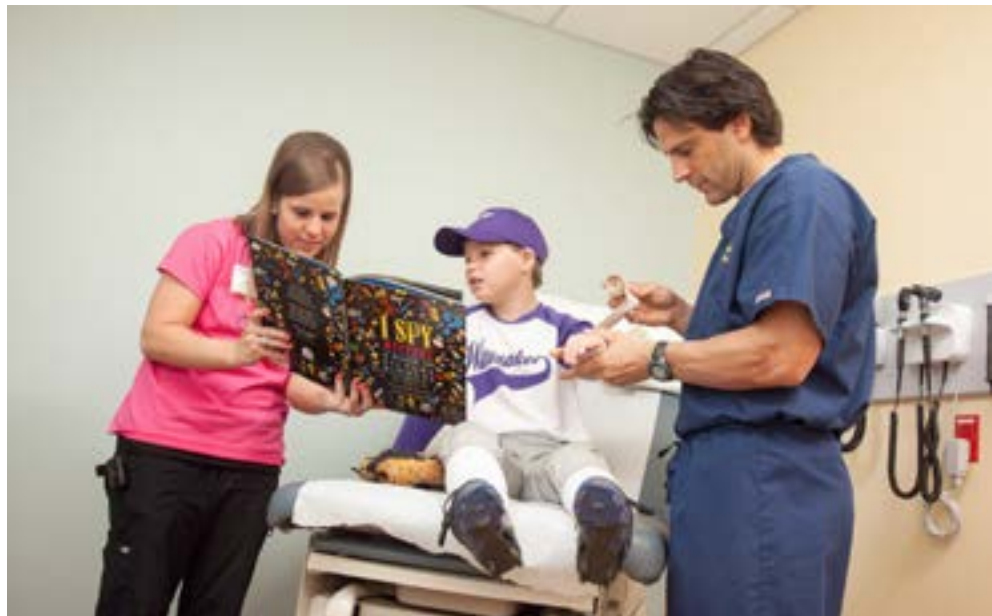

**Q: What non-medical techniques will you use to minimize anxiety and pain in this child?**

**A:** Examples of age-specific distraction techniques:

**Young children:**

- Favourite blanket/toys
- Bubbles
- Books
- Audiotapes
- Videos/movies



**Toddlers and older children:**

- **Music** has been shown to minimize the pain and anxiety associated with painful procedures in children. Simply using a parent's smartphone or tablet device to play a child's favourite music is a low-cost, simple distraction technique.
- **Guided visual imagery** may be of particular benefit to children, as they are generally accepting of the idea of fantasy and suggestion. The dissociative effects of ketamine in particular make it an ideal agent for the adjunctive use of guided imagery.

**Older children/teenagers:**

- Behavioural techniques such as relaxation, biofeedback, breathing
- Physical elements such as heat, cold, positioning

**Q: What if you need to place an IV in a four-month-old? What non-medical techniques have been shown to be effective?**

**A:**

**1. Breastfeeding or breast milk**

- Doesn't eliminate the pain, but it helps temper it
- Not established for repeated painful procedures
- If not available, use glucose/sucrose

**2. Oral sucrose**

- Reduces signs of distress in babies < six months of age
- Most effective in infants (< 28 days of age)
- Improved efficacy in combination with non-nutritive sucking via pacifier

**3. Warming the patient**

- Use an infant warmer or warming blanket



**Clinical Pearl:**

For effective pain reduction associated with venipuncture in infants, give 2 ml of sucrose 22% or more, two minutes before the procedure on the anterior tongue.

If you do not have oral sucrose solution, you can prepare your own by diluting D50 with saline to get D25.



**Clinical Pearl:**

Pain management techniques such as distraction and sucrose can increase procedure success, such as IV placement and lumbar puncture, due to increased patient comfort and co-operation.

**Q: What pharmacologic techniques would you use to decrease pain associated with IV placement?**

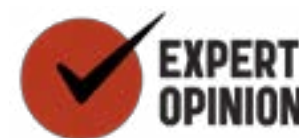

**A: Topical analgesic options for venipuncture:**

Agent	Onset of Action	Comments
<b>EMLA</b> (lidocaine & prilocaine)	60 minutes	More effective if thick layer (2ml) and long duration (>90mins).
<b>Amethocaine 4% gel</b> (Ametop)	30 minutes	Has been shown to be more superior than EMLA for reducing overall needle insertion pain, with less needle attempts required.
<b>Liposomal Lidocaine 4%</b> (LMX-4, Maxilene, ELA-Max)	30 minutes	Good effect for LP in particular.
<b>Vapocolant spray</b>	Immediate	Very short duration, only suitable for procedures that are anticipated to require brief analgesia. Evidence mixed.
<b>J-tip with buffered lidocaine</b> (Zingo)	1-3 minutes	Needle free injector eliminates 'second poke' for venipuncture, decreases the risk of needle stick injury, and decreases the risk of infection transmission. Weak evidence (compared to sham or EMLA that was not on for sufficient time).

Specific agents may be considered for the following situations:

- 1. Lancing an abscess:** Consider vapocolant spray for its very short duration and avoiding pain of injecting local anesthetic.
- 2. Lumbar puncture:** Consider using liposomal lidocaine, as it has been studied specifically with lumbar punctures and showed some benefit.
- 3. Venipuncture:** Consider starting with amethocaine, as it has a short onset of action and has been shown to be superior to EMLA.



### **Clinical Pearl:**

Evidence-based approach to distraction and pain management in infants/children:

- 1.** Music
- 2.** Breastfeeding
- 3.** Sucrose solution
- 4.** Non-nutritive sucking (also to augment sucrose solution)
- 5.** Warm environment

Once non-pharmacologic options are employed, consider one of the following for venipuncture/lumbar puncture:

- 1.** Amethocaine 4%
- 2.** Liposomal lidocaine 4%
- 3.** J-tip with buffered lidocaine

## CASE 3: SENSITIVE EXAMINATIONS AND PROCEDURES

A six-year-old girl comes in after falling off her bicycle with a straddle injury. Her mother reports that she saw blood in the underwear. The child refuses to disrobe despite your reassurance.



**Q: What communication techniques may be used to help relieve anxiety in this child?**

**A:** Anxiety is an important component of and contributor to the pediatric pain experience, especially with sensitive exams such as a genital or perineal exam. Some useful techniques include:

- Ensure parents are in the room; consider examining the patient in their parent's arms if the patient is young and it will not hinder the assessment
- Reassure the child in a reasonable way without making false statements (e.g., "We will take a break if it gets to be too much," as opposed to "We will stop if it gets to be too much")
- Consider lowering yourself physically to the patient's eye level or lower
- Explain the procedure in age-appropriate terms
- Give the patient a realistic choice to empower them (e.g., "I have to look down there; would you rather me do this while you are lying on the bed or sitting on Mom's lap?")
- Procedural sedation may be considered if verbal techniques fail

**Q: What non-pharmacologic treatment options would you use to minimize pain in this patient?**

**A:** Options include:

- Allowing position of comfort
- Applying ice packs
- Wrapping bruising (if present)

**Q: What pharmacologic modalities would you use in this patient?**

**A:** Considerations for patient treatment may include pain and/or anxiety. If pharmacologic agents are chosen, they should reflect the treatment goals.

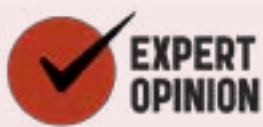Agent	Dose	Onset of Action	Comments
<b>Midazolam</b> (IN, Buccal, IM)	0.3mg/kg-1.0mg/kg	15 min	Usual 0.6mg/kg Max: 12-20mg.
<b>Nitrous Oxide</b>	25-50% with oxygen	5 min Recovery usually < 3 min	

**Midazolam**

- A small percentage of patients get a paradoxical reaction of increased anxiety and agitation.
- Reaction to this benzodiazepine is variable, and as such should be considered second line.

**Nitrous oxide (NO)**

- NO is a relatively weak dissociative anesthetic gas that has several properties including opioid receptor agonism and NMDA and glutamate receptor antagonism. Therefore, it provides mild-moderate anxiolysis, analgesia, and amnesia (a great combination).
- Adverse events seen in 0.03% include vomiting, dizziness, and euphoria/dysphoria, rendering it safe.
- Most hospital protocols do not necessitate fasting prior to use.
- There is no residual effect.
- It has been found to be comparable to IV ketamine for fracture reductions.



Ketamine may cause altered perception and confusion. It should be avoided in sensitive situations such as genital/perineal exams and suspected abuse cases.

## CASE 4: MUSCULOSKELETAL PAIN

A 10-year-old girl comes in after a FOOSH in the playground. She appears very anxious when you examine her. Her X-ray shows a distal radius fracture requiring reduction. She has not received any analgesia. She has no IV established.

**Q: Given her painful injury, to bridge the gap until the sedation starts, what analgesics would you recommend for this patient?**

**A:**

Agent	Dose	Onset of Action
<b>Fentanyl IN</b>	1-1.5mcg/kg (max 100mcg)	2- 3 min
<b>Ketamine IN</b>	1mg/kg	3-7 min
<b>Nitrous Oxide</b>	25-50% with oxygen	5 min Recovery usually <3 min

### Intranasal fentanyl:

- Similar onset of action to intravenous opiates
- Painless administration
- A general rule of thumb is that twice the IV dose is needed
- Less risk for respiratory depression with the appropriate dosing, in the rare event necessitating a reversal agent, such as IN naloxone
- If oral medication is also a therapeutic option, consider administering oral pain medication at the same time as the nasal medication, to time the oral therapeutic effect onset with the IN dose decline



### Clinical Pearl:

- Intranasal limitations: nasal secretions/ congestion
- Do NOT dilute the drugs
- Use both nares (rather than one) for volumes > 0.3 ml (1.5 ml+ each nare)



### Key Reference:

Intranasal ketamine used in children three to 13 years of age with an isolated limb injury and moderate to severe pain was [shown](#) to have similar pain reduction when compared with intranasal fentanyl.



## CASE 5: LACERATION CONSIDERATIONS

A three-year-old boy has fallen while re-enacting a Superman scene. You find a simple laceration on his forehead.

**Q: How can you minimize pain and emotional trauma for this child?**

**A:** Options include:

- Using tissue adhesive, if possible
- Using lidocaine epinephrine tetracaine (LET) prior to using the tissue adhesive
- Using distraction principles mentioned above



Some pediatric emergency departments employ nurse-initiated LET application at triage for all children with lacerations, regardless of the method of laceration closure used. This may expedite assessment, management, and discharge.



Lidocaine epinephrine tetracaine (LET) gel has been shown to decrease pain in children with lacerations that are treated with skin adhesive.



### **Clinical Pearl:**

#### **If using tissue adhesive:**

- Explain that the adhesive will get warm and may “sting”
- Keep adhesive out of the laceration (it is meant to maintain skin together, not fill the defect)
- Consider using LET prior to lidocaine infiltration



### **Comments?**

[Click here to leave a comment or to listen to this podcast.](#)

## KEY REFERENCES:

1. Weisman S, Bernstein B, Schechter NL. Consequences of inadequate analgesia during painful procedures in children. *Arch Pediatr Adolesc Med.* 1998; Feb;152(2):147-149.
2. Kim MK, Strait RT, Sato TT, Hennes HM. A randomized clinical trial of analgesia in children with acute abdominal pain. *Acad Emerg Med.* 2002; Apr;9(4):281-287.
3. McGuire L, Heffner K, Glaser R, et al. Pain and wound healing in surgical patients. *Ann Behav Med.* 2006; Apr;31(2):165-72.
4. Page GG. Are There Long-Term Consequences of Pain in Newborn or Very Young Infants? *J Perinat Educ.* 2004 Summer; 13(3):10-17. doi: 10.1624/105812404X1725
5. Merkel SI, Voepel-Lewis T, Shayevitz JR, Malviya S. The FLACC: a behavioral scale for scoring postoperative pain in young children. *Pediatr Nurs.* 1997; 23(3):293-7.
6. Hicks CL, von Baeyer CL, Spafford PA, van Korlaar I, Goodenough B. The Faces Pain Scale-Revised: toward a common metric in pediatric pain measurement. *Pain.* 2001; Aug;93(2):173-183.
7. Wong DL, Baker CM. Pain in children: comparison of assessment scales. *Pediatr Nurs.* 1998; 14(1):9-17.
8. Bandstra NF, Skinner L, Leblanc C, et al. (2008). The role of child life in pediatric pain management: a survey of child life specialists. *J Pain.* 2008; Apr;9(4):320-9.
9. Ali S, Drendel AL, Kircher J, Beno S. Pain management of musculoskeletal injuries in children: Current state and future directions. *Pediatr Emerg Care.* 2010; Jul;26(7):518-524,
10. Drendel AL, Kelly BK, Ali S. Pain Assessment for Children: Overcoming Challenges and Optimizing Care. *Pediatric Emergency Care.* 27(8):773-81, 2011. PMID: 21822093.
11. Zempsky WT, Cravero JP. American Academy of Pediatrics Committee on Pediatric Emergency Medicine and Section on Anesthesiology and Pain Medicine. Relief of pain and anxiety in pediatric patients in emergency medical systems. *Pediatrics.* 2004; Nov;114(5):1348-56.
12. Kircher J, Drendel AL, Newton AS, Dulai S, Vandermeer B, Ali S. Pediatric musculoskeletal pain in the emergency department: a medical record review of practice variation. *CJEM.* 2014; Nov;16(6):449-57.
13. Poonai N, Paskar D, Konrad SL, et al. Opioid analgesia for acute abdominal pain in children: A systematic review and meta-analysis. *Acad Emerg Med.* 2014 Nov;21(11):1183-92. doi: 10.1111/acem.12509.
14. McGaw T, Raborn W, Grace M. Analgesics in pediatric dental surgery: relative efficacy of aluminum ibuprofen suspension and acetaminophen elixir. *ASDC J Dent Child.* 1987;54(2):106-109.
15. Clark E, Plint AC, Correll R, Gaboury I, Passi B. A randomized, controlled trial of acetaminophen, ibuprofen, and codeine for acute pain relief in children with musculoskeletal trauma. *Pediatrics.* 2007; Mar;119(3):460-7.
16. Kramer LC, Richards PA, Thompson AM, Harper DP, Fairchok MP. Alternating antipyretics: antipyretic efficacy of acetaminophen versus acetaminophen alternated with ibuprofen in children. *Clin Pediatr (Phila).* 2008; Nov;47(9):907-11.
17. Poonai N, Bhullar G, Lin K, et al. Oral administration of morphine versus ibuprofen to manage postfracture pain in children: a randomized trial. *CMAJ.* 2014; Dec 9;186(18):1358-63. doi: 10.1503/cmaj.140907. Epub 2014 Oct 27.



18. Kleiber C, Harper DC. Effects of distraction on children's pain and distress during medical procedures: a meta-analysis. *Nurs Res*. 1999; 48(1), 44-9.
19. Shah PS, Herbozo C, Aliwalas LL, Shah VS. Breastfeeding or breast milk for procedural pain in neonates. *Cochrane Database Syst Rev*. 2012; Dec 12;12:CD004950.
20. Curtis SJ, Jou H, Ali S, Vandermeer B, Klassen T. A randomized controlled trial of sucrose and/or pacifier as analgesia for infants receiving venipuncture in a pediatric emergency department. *BMC Pediatr*. 2007; 7(1):27.
21. Stevens B, Yamada J, Ohlsson A. (2004). Sucrose for analgesia in newborn infants undergoing painful procedures. *Cochrane Database Syst Rev*. 2004; (3):CD001069.
22. Zempsky WT. Pharmacologic Approaches for Reducing Venous Access Pain in Children. *Pediatrics*. 2008; Nov;122 Supple 3:S140-53.
23. Jimenez N, Bradford H, Seidel KD, Sousa M, Lynn AM. A Comparison of a needle-free injection system for local anesthesia versus EMLA® for intravenous catheter insertion in the pediatric patient. *Anesth Analg*. 2006; Feb;102(2), 411-4.
24. Spanos S, Booth R, Koenig H, Sikes K, Gracely E, Kim IK. Jet injection of 1% buffered lidocaine versus topical ELA-Max for anesthesia before peripheral intravenous catheterization in children: A randomized controlled trial. *Pediatr Emerg Care*, 2008; Aug;24(8), 511-5.
25. Zier JL, Liu M. Safety of High-Concentration Nitrous Oxide by Nasal Mask for Pediatric Procedural Sedation. *Pediatr Emerg Care*. 2011; Dec;27(12): 1107-12.
26. National Institute for Health and Clinical Excellence (NICE). Sedation in Children and Young People. London: Royal College of Physicians (UK). *NICE Clinical Guidelines*. 2010; Dec. 30; no. 112.
27. Borland M, Jacobs I, King B, O'Brien D. A randomized controlled trial comparing intranasal fentanyl to intravenous morphine for managing acute pain in children in the emergency department. *Ann Emerg Med*. 2007; Mar;49(3):335-40.
28. Rickard C, O'Meara P, McGrail M, Garner D, McLean A, Le Lievre P, A randomized controlled trial of intranasal fentanyl vs intravenous morphine for analgesia in the prehospital setting. *Am J Emerg Med*. 2007; Oct;25(8):911-7.
29. Graudins A, Meek R, Egerton-Warburton D, Oakley E, Seith R. The PICHFORK (Pain in Children Fentanyl or Ketamine) trial: a randomized controlled trial comparing intranasal ketamine and fentanyl for the relief of moderate to severe pain in children with limb injuries. *Ann Emerg Med*. 2015 Mar;65(3):248-254.e1.
30. Singer AJ, Stark MJ. Pretreatment of Lacerations with Lidocaine, Epinephrine, and Tetracaine at Triage: A Randomized Double-blind Trial. *Acad Emerg Med*. 2000; Jul;7(7):751-6.
31. Harman S, Zemek R, Duncan MJ, Ying Y, Petrich W. Efficacy and pain control with topical lidocaine-epinephrine-tetracaine during laceration repair with tissue adhesive in children: a randomized controlled trial. *CMAJ*. 2013; 185(13):E629-34.

# CHAPTER 4: HEAD INJURY

[LISTEN TO THE PODCAST WITH RAHIM VALANI AND JENNIFER RILEY HERE](#)



## Objectives

1. Outline the classification of pediatric traumatic head injuries
2. Review and compare the PECARN and CATCH clinical decision instruments for minor head injury
3. Explore the role of skull X-rays in children with minor head injury
4. Review Return to Sport guidelines after pediatric head injury
5. Review elevated ICP management in a critically ill child with traumatic brain injury

## CASE 1: MINOR HEAD INJURY

A mother presents to the emergency department with her nine-month-old male infant who fell down four steps onto a concrete sidewalk while in a stroller that had overturned. She reports that he cried immediately, did not vomit, and did not have a seizure. The infant is otherwise healthy, with no previous head injuries or significant medical history.

On examination, he is alert and crying. His heart rate is 132 bpm, blood pressure is 85/50, respiratory rate is 26, temperature is 36.5°C, and oxygen saturation is 99% on room air. His GCS is 15 with equal and reactive pupils. Neck range of motion is normal. He is moving all limbs normally. Full exposure of the infant reveals a 3 cm boggy occipital hematoma. There are no signs of basal skull fracture, and no signs of injury of the chest, abdomen, back, or limbs.

**Q: How would you classify this head injury—trivial, minor, moderate, or severe?**

### **Trivial head injury:**

- GCS 15
- No loss of consciousness, low energy mechanism
- Small frontal hematoma, no other signs of traumatic brain injury (TBI)
- Older than one year

### **Minor head injury:**

- Eighty-five per cent of non-trivial head injury
- GCS 14–15
- Loss of consciousness, amnesia, or confusion
- Disorientation
- Other symptoms/signs (vomiting, headache)
- Impact seizure

### **Moderate–severe head injury:**

- GCS  $\leq 13$  or deteriorating GCS
- Penetrating head injury
- Focal neurologic findings
- Late seizure (not impact)
- Known child abuse

**Q: Does this infant require a CT scan of the head to rule out significant TBI?**

**A:** In general, the incidence of clinically significant TBI requiring intervention in children with minor head injury is low. While the yield of CT in minor head injury for any intracranial lesion is approximately 5%, neurosurgical lesions occur in only 0.5%.

Proportion of all-comers with minor head injury who will require intervention:

- Normal mental status: 0.8%
- AND no signs of skull fracture: 0.5%
- AND no history of vomiting: 0.2%
- AND no history of persistent headache: 0%

Select populations have very low risk of TBI:

- Isolated vomiting
- Isolated LOC
- Isolated amnesia

**Radiation considerations in pediatric head injury imaging**

The fastest-growing group of patients getting CT scans is pediatric patients, with an estimated 600,000 CT scans done annually on children under the age of 15 years in the United States. The lifetime risk of cancer due to CT scans (which have been estimated in the literature using projection models based on atomic bomb survivors) is about one case of cancer for every 1,000 people who are scanned. For head CTs in children in particular, a retrospective cohort study assessing leukemia and brain tumour risk from pediatric head CT estimated that one case of leukemia and one brain tumour will result from every 10,000 children scanned. Radiation exposure in infancy may effect IQ later in life.



## **Pediatric Emergency Care Applied Research Network (PECARN) Study:**

### **Clinical decision instruments for pediatric head injury**

Based on a PECARN study, the validated predictors of clinically important TBI in children younger than two years include:

1. Altered mental status
2. Non-frontal scalp hematoma
3. Loss of consciousness for at least five seconds
4. Severe mechanism of injury
5. Palpable skull fracture
6. Not acting normally, according to the parent

The risk of clinically important TBI in a child with none of these six predictors was found to be 0.02%. In prospective validation, both the sensitivity and negative predictive value for the detection of TBI was 100% for children younger than two years old.

For children with one or more of these predictors, either CT scan or observation may be appropriate, depending on several factors, such as physician experience, with a lower threshold to image children with multiple, more severe, or worsening signs or symptoms. Clinicians should not use these criteria to trigger a scan in a child whom they otherwise would not image. Extra caution is still advisable in children younger than three months, in whom clinical evaluation is less reliable.

The PECARN group also performed a secondary analysis of a prospective observational cohort of children with minor head injury and a GCS of 14–15 who had isolated vomiting

*For the CATCH study clinical prediction instrument and comparison to the PECARN rule, see Case 2.*

**Q: What is the significance of a scalp hematoma in an otherwise asymptomatic head-injured infant?**

**A:** Among asymptomatic head-injured infants, the risk of skull fracture and associated intracranial injury is correlated with scalp hematoma size > 2cm and location (non-frontal).

**Q: Is there any role for a skull X-ray in ruling out clinically significant TBI?**

**A:** Background: Eleven per cent of children under the age of two years will sustain a skull fracture associated with head trauma. Fifteen to 30 per cent of these will have TBI; therefore, in a child under the age of two years, a skull fracture is a predictor of TBI. Children with skull fractures require a head CT to rule out significant intracranial injuries.



While there is little evidence for the role of skull X-rays in ruling out clinically significant TBI, in practice locations where CT is not readily available, consider a skull X-ray for children under the age of two years who present with a significant scalp hematoma with no other signs of TBI as a screening test for skull fracture. Ensure a radiologist's interpretation, as emergency physicians' interpretations of pediatric skull X-rays have been shown to have poor accuracy for detecting skull fractures.





### **Clinical Pearls in Pediatric Minor Head Injury:**

- 1.** Isolated loss of consciousness or amnesia: In one study of 2,043 children with minor head injury, isolated LOC, and/or amnesia with no other signs or symptoms, none had a positive CT and none required surgery.
- 2.** Persistent irritability is always a worrisome sign in a head-injured child under the age of two years.
- 3.** Isolated vomiting is rarely associated with significant TBI. Some experts believe that post-head-injury vomiting may be more related to a personal history of recurrent vomiting; on the other hand, persistent vomiting associated with other symptoms of TBI does have a significant positive predictive value for TBI.

[Click here for an analysis of studies of isolated vomiting in pediatric minor head injury.](#)

## CASE 2: MODERATE HEAD INJURY

A six-year-old boy was walking with his family on a windy evening. As they passed a construction site, a truck driver opened a large metal gate, which swung out of control and hit the child in the head. The child was thrown back approximately six feet and landed on the back of his head on the edge of a cement curb. There was a loss of consciousness of three to five minutes, and upon awakening the child was confused and had two episodes of vomiting. He arrives in the emergency department with paramedics. On further questioning he is amnestic; however, he does recall walking with his parents prior to the event. In the ED, he is perseverating.

On examination:

Heart rate is 110 bpm, blood pressure is 118/60, respiratory rate is 20, temperature is 36.5°C, and oxygen saturation is 98% on room air.

A: Patent

B: Breathing spontaneously, good air entry bilaterally

C: Cap refill three seconds, pedal pulses present

D: Pupils are equal and reactive at 4 mm, GSC is 13

There is a large hematoma to the forehead as well as a large occipital hematoma. There are no signs of basal skull fracture. Abdomen is soft and non-distended, bowel sounds are present. The pelvis is stable. Extremities are normal. There is no tenderness over the spine. Neurological examination is normal, aside from the GCS of 13.

The patient is otherwise healthy; all of his immunizations are up to date.

**Q: Does this child require a CT scan?**

**A:** As you know from Case 1, the PECARN study helps us to decide whom not to CT scan. In addition, we can use the CATCH study to help us decide whom to CT scan.



## **CATCH Study:**

### **The Canadian Assessment of Tomography for Childhood Head Injury (CATCH)**

Head CT is required only for **minor head injury** patients with any one of these findings:

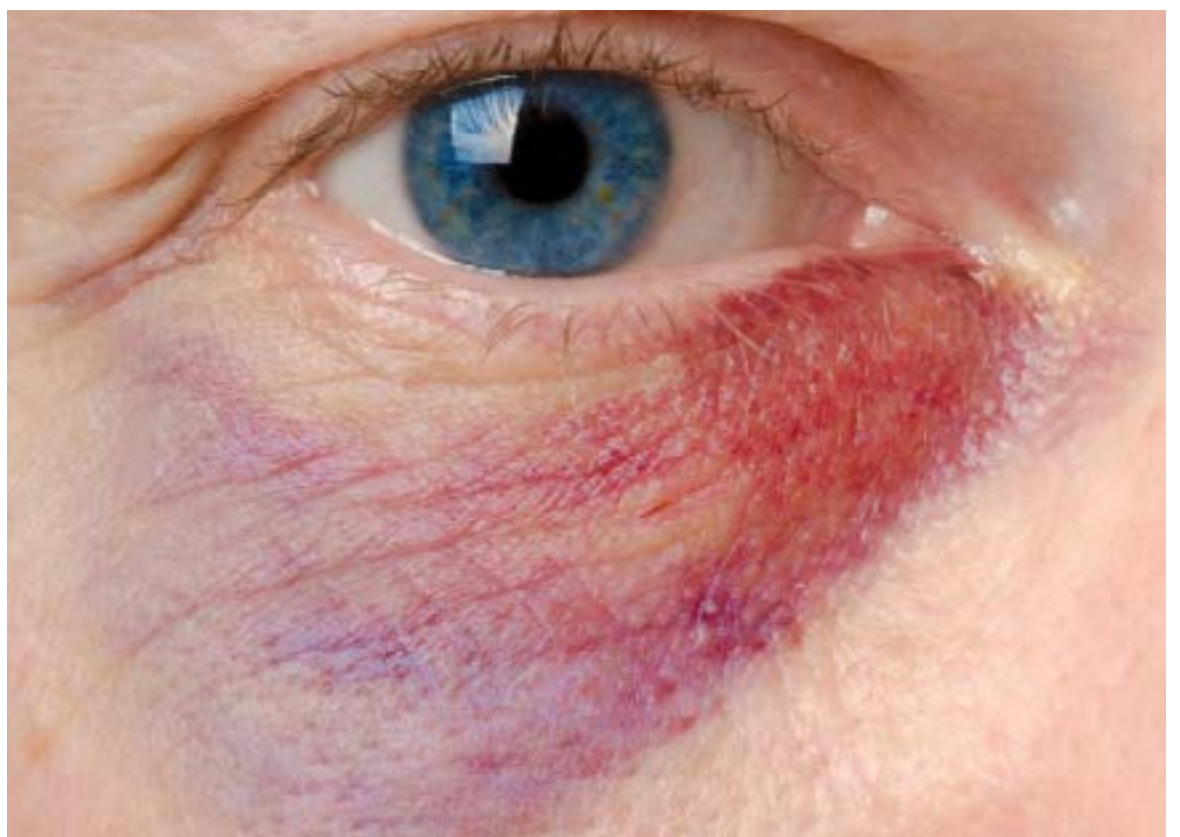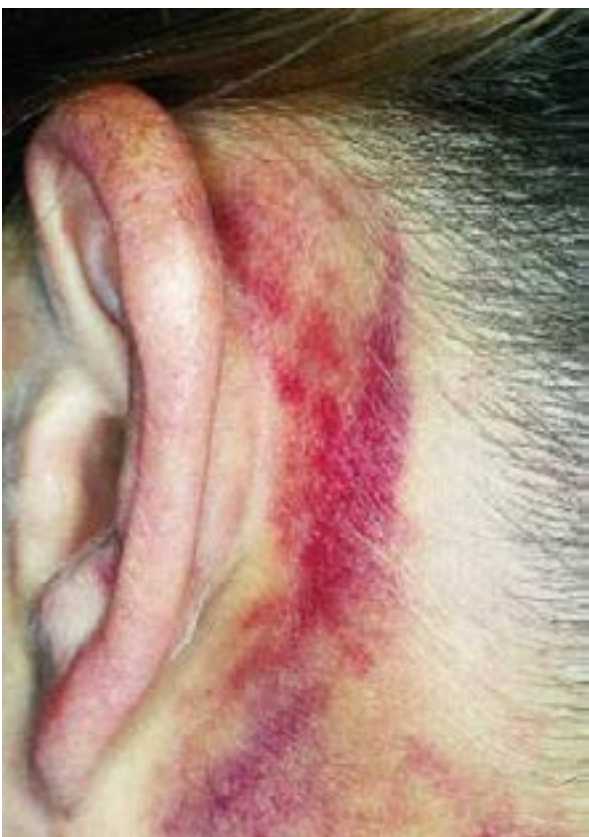- Minor head injury is defined as injury within the past 24 hours associated with witnessed loss of consciousness, definite amnesia, witnessed disorientation, persistent vomiting, or persistent irritability (in a child younger than 2 years of age) with a GCS of 13–15.
- **High risk (100% sensitive for neurological intervention):**
  1. GCS score < 15 at two hours post-impact
  2. Suspected skull penetration or depressed fracture
  3. Worsening headache on history
  4. Irritability on exam
- **Medium risk (98% sensitive for any lesion on CT scan):**
  1. Any sign of basilar skull fracture
  2. Large, boggy scalp hematoma
  3. Dangerous mechanism, such as:
    - a) Fall from height  $\geq 3$  feet or  $\geq$  five stairs
    - b) Motor vehicle-related
    - c) Fall from bicycle with no helmet

[A prospective study](#) comparing the sensitivity and specificity of the PECARN and CATCH rules, as well as a third set of rules called the CHALICE, found the PECARN rules to be the most sensitive (100%), while the CATCH rules were found to be 91% sensitive. This is to be expected, as the PECARN rules are meant to rule out the need for a CT in minor injuries, as opposed to rule in the need for one. The CHALICE rule was identified as the least sensitive.

**Q: What are the signs of basilar skull fracture?**

**A:**

- Hemotympanum
- Periorbital ecchymosis (raccoon eyes)
- Mastoid bone ecchymosis (Battle's sign)
- Cerebrospinal fluid leak from the nose or ears (otorrhea/rhinorrhea)



Signs of basilar skull fracture

**Q: What are the key differences between the adult CT Head Rule and the CATCH rule?**

**A:** The CATCH rule does not include vomiting and amnesia, but instead includes irritability in a child younger than two years old, or worsening headache in the older child, and the presence of a large boggy scalp hematoma.

**Q: How long should a child with mild or moderate head injury who is deemed unsuitable for a CT scan be observed in the emergency department?**

**A:** If the child has any of the following, then guidelines suggest either a four- to six-hour observation period, or going straight to CT scan: history of loss of consciousness, amnesia, confusion, lethargy or persistent vomiting, severe or persistent headache, or immediate post-traumatic seizure.

**Q: What discharge instructions should be given to children with minor head injuries or moderate head injuries who are deemed suitable to go home?**

**A:**

- The first six hours post-injury are referred to as the “red zone,” and the subsequent 24 hours are the “yellow zone.”
- Waking up the patient every two hours is probably not necessary (and if the clinician believes the patient to be high risk, he/she should be kept in the department longer).
- Partially waking up the patient once during the night to assure reasonable behaviour might be reasonable, especially if within the “red zone” time.

### **Q: When can the patient return to sport?**

**A:** A variety of guidelines exists to help answer this question, but every athlete needs an individual approach to prevent second-impact syndrome. A reasonable general guideline includes refraining from all activity until one week post-resolution of post-concussive symptoms (headache, amnesia, dizziness), and then using a step-wise approach: mild exertion to increase heart rate, sport-related activity with no contact, progressive return to full practice, and then return to game situations. If symptoms develop at any of these stages, go back to the previous stage and consult the primary caregiver of the patient. [See CPS summary on evaluation of concussion and Return to Play guidelines here.](#)

**EM Cases cross-link:** [For Dr. Joel Yaphe's review of the guidelines "Concussions and their consequences: current diagnosis management and prevention" \(published in CMAJ in 2013\) from Whistler's Update in EM Conference 2014, go here.](#)

### **Q: How do pediatric head injuries differ from adult head injuries?**

**A:**

- Children's skull sutures are not closed yet, so their skulls tend to be more distensible than those of adults. This leads to less TBI after head trauma with comparable mechanism of injury.
- Children sustain fewer mass lesions and fewer hemorrhagic contusions.
- Children sustain more diffuse brain swelling and can "talk and deteriorate" with edema alone.
- Children sustain more diffuse axonal injury.
- Children sustain more hypoxia.
- Children have more seizures.



## CASE 3: MAJOR HEAD INJURY

A five-year-old girl was the front-seat passenger in a motor vehicle crash. The child was wearing her seat belt, but no airbags were deployed. The collision occurred when the driver lost control of the car on the highway, hitting the concrete divider on the left side of the vehicle. It was unknown whether the child lost consciousness. At the scene, the child was confused and combative. Unfortunately, the driver of the vehicle did not survive.



On examination, the vitals are as follows:

Heart rate is 100 bpm, blood pressure is 130/90 mmHg, respiratory rate is 24, temperature is 36.6°C, and oxygen saturation is 98% on oxygen.

- A: Patent
- B: Breathing, good air entry bilaterally
- C: Cap refill three seconds, pedal pulses present
- D: Pupils are equal and reactive at 4 mm, GSC is 7 (E3V2M2);  
no focal neurological findings.

There are multiple abrasions, a contusion over one eye, a lip laceration, and a chipped tooth. There is a seat belt bruise on the abdomen, and the abdomen is tender. There are stellate lacerations of 3 cm and a hematoma over the right parietal region, with no palpable skull depression. There are no signs of basilar skull fracture. In addition, there is an open, complex fracture of the right ankle.

As you are examining the child, her conditions worsen: The GSC drops to 3, while the heart rate and blood pressure remain steady at 95 bpm and 140/95, respectively. The right pupil remains at 4 mm while the left pupil is now 7 mm.

**Q: Assuming that you want to intubate this patient and send her for an immediate CT, how would you best sedate the child for intubation and CT scanning?**

**A:** Although the literature is sparse and controversial for the effectiveness of pre-medication to blunt the effects of intubation on raised intracranial pressure (ICP) in the pediatric population, consider pre-medication of fentanyl or lidocaine as part of rapid-sequence intubation (RSI) algorithm. It is important to note that these medications need to be given a full two to three minutes before intubation to be effective, therefore they are not suitable in a “crash” intubation situation.

The induction agent should aim to prevent a drop in blood pressure, given that  $CPP = MAP - ICP$  (cerebral perfusion pressure equals mean arterial pressure minus intracranial pressure). Etomidate probably remains the agent of choice. However, there is evidence that ketamine is a safe and suitable alternative for sedation in TBI, with recent systematic reviews failing to demonstrate increased ICP after ketamine use. Ketamine may offer neuroprotective effects secondary to its effects on NMDA receptor activity.

For sedation to enable CT scanning in the young pediatric patient, agents that decrease blood pressure should be avoided. Ketamine is an ideal agent for this purpose, as it has been shown not to raise intracranial pressure, it is an effective analgesic and amnesic, it may be neuroprotective, and it does not lower the blood pressure. Ketamine can be given intravenously, intramuscularly, or by the intranasal route.



**Expert Tip:**

To enable CT scan sedation, keep the very young child awake as long as possible before going to the CT scanner, and perform the CT scan when the child falls asleep. Feeding the child and then performing the CT scan during the post-feed nap can also be an effective way to enable sedation.

**Q: What signs should I be watching for if I am worried about elevated ICP?**

**A:** Elevated ICP occurs in up to 80% of children with TBI. Clinical clues of increased ICP include worsening headache, visual or neurologic complaints, and persistent vomiting, as well as abnormal pupillary reflexes, decreasing level of awareness, lateralizing features, and Cushing's triad.

**Q: How do I manage elevated ICP?**

**A:** Methods for acutely decreasing ICP in the emergency department include elevation of the head of the bed 30 degrees, with the head mid-line, intravenous mannitol or hypertonic saline administration and hyperventilation, which is used only as a temporizing measure in a patient who shows evidence of brain herniation or who is being imminently transferred to the operating room (target  $pCO_2$  is 30–35 mmHg).

Mannitol works by creating an intravascular osmotic pull, hence decreasing blood viscosity and increasing intravascular osmolarity. This helps to decrease brain edema by setting up an osmotic gradient across an intact blood-brain barrier (BBB). Mannitol is dosed as a bolus of 0.25-1 g/kg.

**Q: Is there an alternative to mannitol for the treatment of elevated ICP?**

**A:** Hypertonic saline (3%) was shown to be more effective than mannitol in lowering raised ICP in one meta-analysis of adult studies, and is recommended especially if the patient is hypotensive as it has no osmotic diuretic effect. It is given as a bolus of 2-6 ml/kg, followed by an infusion of 0.1-1 ml/kg/hr.

**FOAMed link:** [\*For a detailed analysis of elevated ICP management, see Dr. Scott Weingart's suggestions on EMCrit.\*](#)



**Comments?**

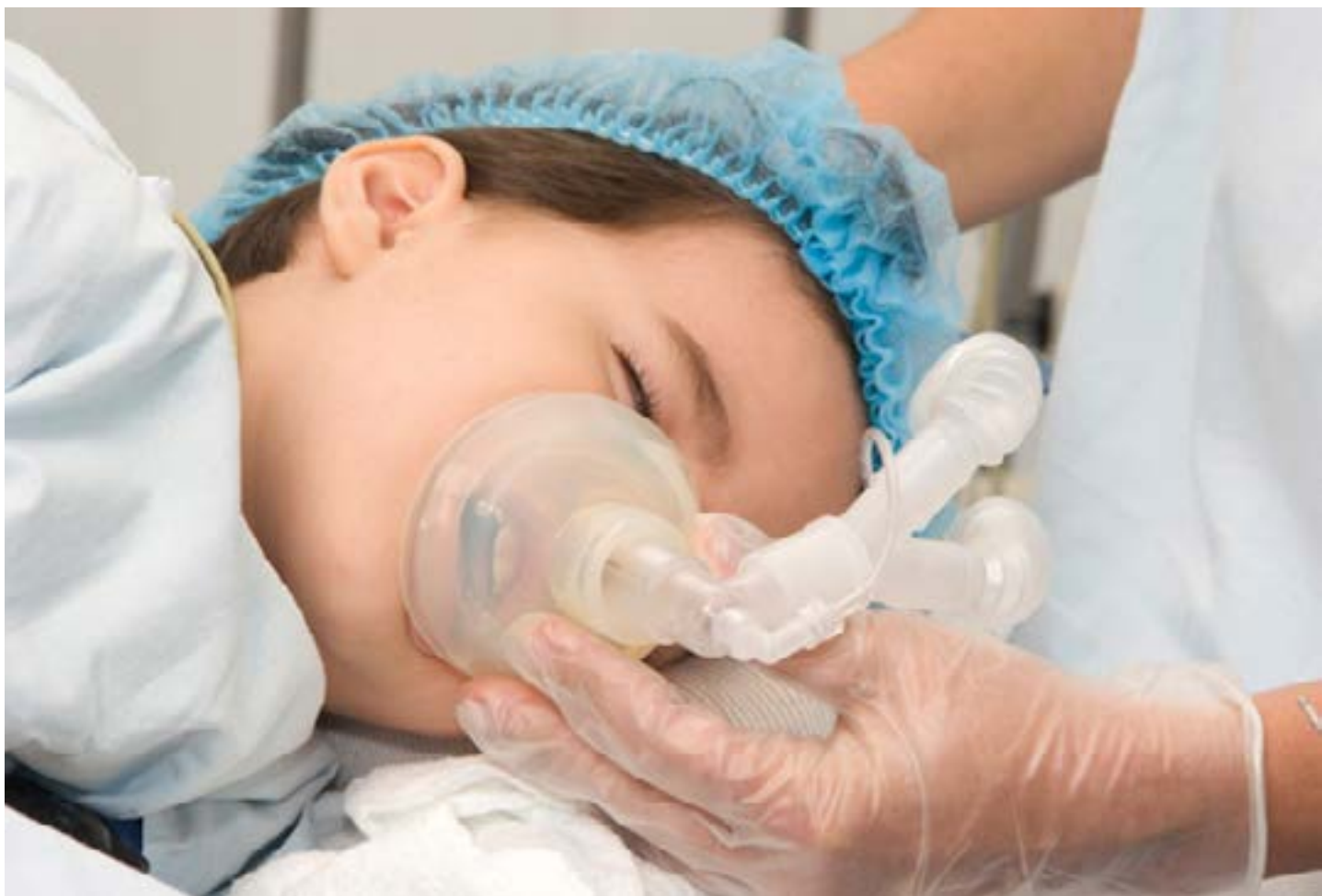[\*Click here to leave a comment or to listen to this podcast.\*](#)

## KEY REFERENCES:

1. Kuppermann N, Holmes JF, Dayan PS, et al. Identification of children at very low risk of clinically-important brain injuries after head trauma: a prospective cohort study. *Lancet*. 2009; 374(9696):1160-70.
2. Greenes DS, Schutzman SA. Clinical significance of scalp abnormalities in asymptomatic head-injured infants. *Pediatr Emerg Care*. 2001; Apr;17(2):88-92.
3. Hall P, Adami HO, Trichopoulos D, et al. Effect of low doses of ionising radiation in infancy on cognitive function in adulthood: Swedish population based cohort study. *BMJ*. 2004; Jan; 328(7430):19.
4. Brenner DJ, Hall EJ. Current concepts - Computed tomography - An increasing source of radiation exposure. *New Engl J Med*. 2007; Nov;357(22):2277-84.
5. Palchak MJ, Holmes JF, Vance CW, et al. Does an isolated history of loss of consciousness or amnesia predict brain injuries in children after blunt head trauma? *Pediatrics*. 2004; June;113(6):e507-13.
6. Osmond MH, Klassen TP, Wells GA, et al. CATCH: a clinical decision rule for the use of computed tomography in children with minor head injury. *CMAJ*. 2010; Mar;182(4):341-8.
7. Easter JS, Bakes K, Dhaliwal J, Miller M, Caruso E, Haukoos JS. Comparison of PECARN, CATCH, and CHALICE rules for children with minor head injury: a prospective cohort study. *Ann Emerg Med*. 2014; Aug;64(2):145-52.
8. Tator CH. Concussions and their consequences: current diagnosis management, and prevention.. *CMAJ*. 2013; Aug;185(11):975-979.
9. Filanovsky Y, Miller P, Kao J. Myth: Ketamine should not be used as an induction agent for intubation in patients with head injury. *CJEM*. 2010; Mar;12(2):154-7.
10. Dayan PS, Holmes JF, Atabaki S, et al. Traumatic Brain Injury Study Group of the Pediatric Emergency Care Applied Research Network (PECARN). Association of traumatic brain injuries with vomiting in children with blunt head trauma. *Ann Emerg Med*. 2014; Jun;63(6):657-65.
11. Pearce MS, Salotti JA, Little MP, et al. Radiation exposure from CT scans in childhood and subsequent risk of leukaemia and brain tumours: a retrospective cohort study. *Lancet*. 2012; Aug 4;380(9840):499-505.
12. Farrell CA, Canadian Paediatric Society Acute Care Committee. Management of the paediatric patient with acute head trauma. *Paediatr Child Health*. 2013; 18(5):253-8.
13. Kamel H, Navi BB, Nakagawa K, Hemphill JC 3rd, Ko NU. Hypertonic saline versus mannitol for the treatment of elevated intracranial pressure: a meta-analysis of randomized clinical trials. *Crit Care Med*. 2011; Mar;39(3):554-9.

# CHAPTER 5: PEDIATRIC PROCEDURAL SEDATION

[LISTEN TO THE PODCAST WITH AMY DRENDEL HERE](#)



## Objectives

1. Develop an approach to pediatric procedural sedation for fracture reduction, dislocation, and other painful procedures
2. Develop an approach to pediatric procedural sedation for patients requiring anxiolytics for minor procedures and imaging
3. Develop an approach to pediatric procedural sedation for patients requiring a lumbar puncture
4. Understand the important pharmacological properties, benefits, and precautions of the various medications for pediatric procedural sedation (ketamine, propofol, fentanyl, etomidate, nitrous oxide, midazolam)

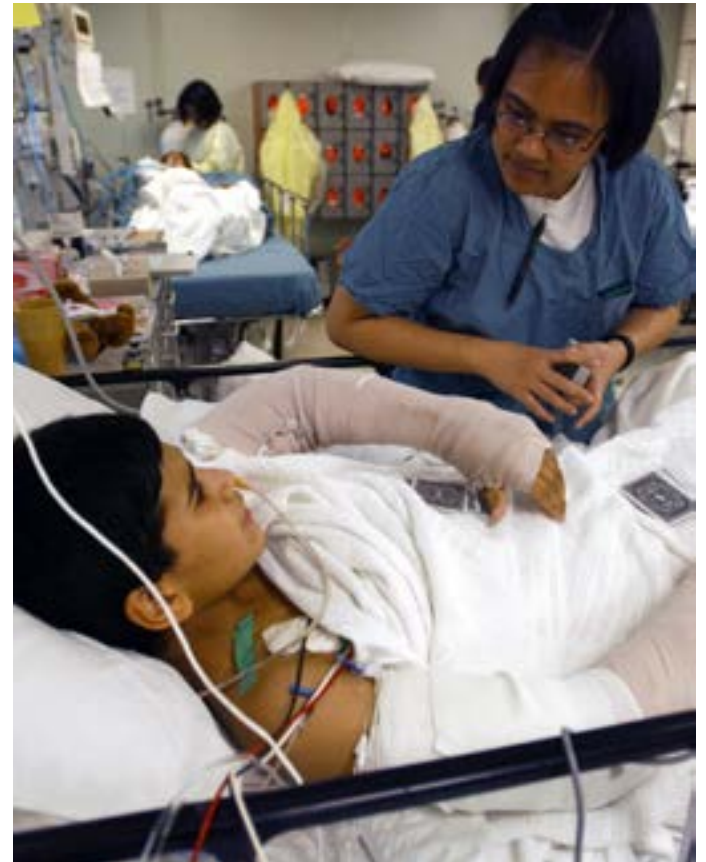

## CASE 1: PROCEDURAL SEDATION FOR PAINFUL PROCEDURES

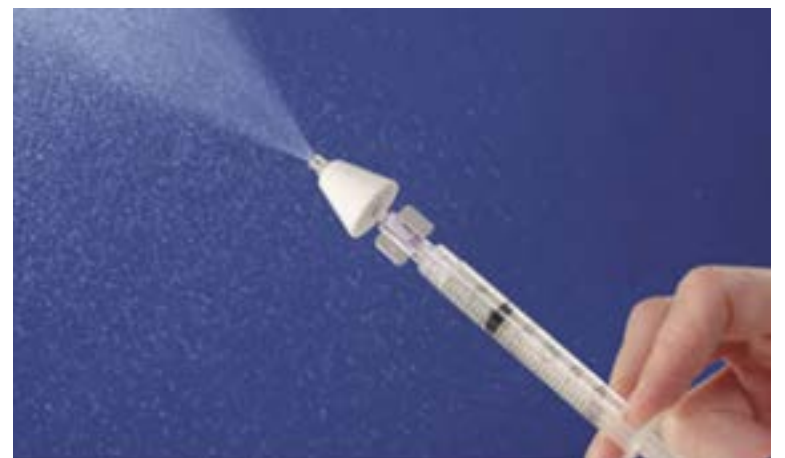A 10-year-old morbidly obese boy presents to the emergency department after a FOOSH in the playground. After a full history, exam, and X-ray, you diagnose him with a distal radius fracture, requiring reduction. The boy appears very anxious.

**Q: The child has not received any medications at home or at triage. It will take about an hour to assemble the team for the procedural sedation. What analgesics would you consider giving in the meantime?**

**A:** A great starting choice for a patient in this scenario would be intranasal (IN) fentanyl. Fentanyl is an effective analgesic and works quickly, with an onset of action of about three minutes (a faster onset compared with intravenous opiates), and negates needing an IV.



Fentanyl IN is given at a dose of 1-2 mcg/kg with a maximum dose of 100 mcg. Use a mucosal atomizing device to deliver this dose intranasally.







### **Clinical Pearl: Using Intranasal Fentanyl**

- Use the most concentrated formulation and do not dilute it
- Use both nostrils for volumes > 0.3 ml to double the absorptive surface and reduce runoff
- Consider administering oral pain medication concurrently for continued pain management after the fentanyl has worn off
- Respiratory depression is rare with correct dosing; however, naloxone is also effective intranasally if needed as a reversal agent

*[For evidence, explanations and tips on Intranasal medications and medication delivery, click here to visit intranasal.net.](http://intranasal.net)*

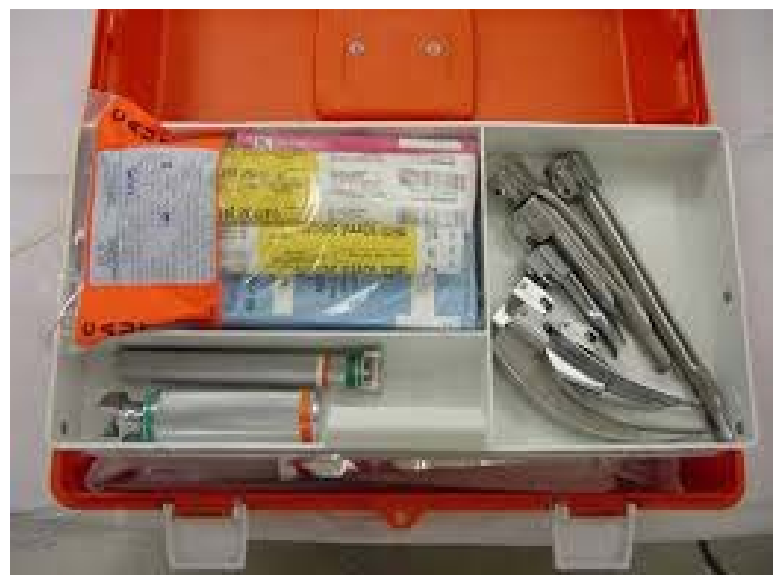**Q: As you are preparing the medication, the parents appear to be worried and ask you whether needles are required. How would you involve the parents in your procedural sedation plan?**

**A:** The EM literature has shown over and over that families prefer staying at the bedside for procedures. Parents' use of distraction techniques with music or videos from smartphones or tablets, and even helping out in the procedure, can improve parental satisfaction and decrease the child's anxiety. So, generally speaking, it's a good idea to have Mom or Dad at the bedside helping out. However, we've all been in the situation when Mom or Dad starts freaking out during the procedure—and usually we can anticipate which family members will react this way—so for those folks, you may elect to ask them to step out of the room during the procedure. You may also consider using other distraction techniques as outlined in this chapter.

**Q: You decide to have the parents nearby soothing the child and distracting him with their games on their smartphone. Now it's time to prepare for the sedation. What do you consider in preparing to mitigate any potential risks during the procedure?**

**A:** Always do a full assessment, paying attention to any prior procedural sedations and their success. Include any past medical history, allergies, and any current illnesses, as these may affect your choice of medication. In the past medical history, be sure to screen specifically for asthma, viral respiratory infections and obstructive sleep apnea as these are important risk factors for complications. Also conduct a thorough focused examination of the child and, in particular, the child's airway and oral cavity.

Have a procedural sedation tray or procedure tray nearby, and have the child on a cardiac monitor with frequent vital signs, including a pulse oximeter. If it is available, use capnography as it has been shown to pick up respiratory depression earlier than an oxygen saturation probe. Ensure you have at least one dedicated nurse during the procedure. Also, have all of your age-appropriate airway equipment (including suction and oxygen) on hand in case of complications.



### **Pitfall:**

Pediatric patients are at a higher risk of airway obstruction due to anatomical factors such as large occiput and tongue, and narrower, more pliant airways.

Patients younger than three months of age should be sent to anesthesiology due to more complex neurodevelopmental considerations with sedation.

**Q: As part of your history, you ask the parents when the child last had anything to eat or drink, and they tell you that he ate a hamburger two hours prior. Are you safe to go ahead with the sedation, or do you need to wait another few hours?**

**A:** It is helpful to know when the patient last ate, but the literature does not support mandatory fasting to prevent complications of aspiration in procedural sedation. A large study addressing this question found no difference in adverse events among children who had been fasting two, four, six, or eight hours. A conservative approach based on the American Society of Anesthesiologists' fasting guidelines would be to wait three to four hours after their last meal, but there is no indication to wait if you urgently need to perform a procedure.

**Q: Now that you have a good grasp on the patient's history and physical exam and you have prepared all of your equipment, you consider the options available to you for sedation of the patient. What are your options for sedating this patient?**

**A:** You have a variety of options that each have their own strengths and risks. Consider each in relation to your specific clinical scenario. Different agents may influence the risk of emesis. For example, ketamine is the most commonly used medication, but may increase the risk of emesis. Nitrous oxide also has similar risk of emesis, while propofol may have a decreased risk but may not be suitable for younger or unstable patients. Consider adding an antiemetic, such as ondansetron, prior to the sedation. There is evidence to support the use of ondansetron in conjunction with ketamine to reduce the risk of emesis (NNT= 9). While the addition of midazolam to ketamine may reduce the likelihood of emesis, it increases the risk of respiratory depression and will prolong the recovery time.

Ketamine has become the most common agent for pediatric procedural sedation. It provides the desired trifecta of analgesia, sedation, and amnesia in a single agent.



## Ketamine Sedation

	<b>Ketamine IV</b>	<b>Ketamine IM</b>	<b>Ketamine + Midazolam IV</b>
<b>Dose</b>	1-2 mg/kg slow IV push.	4-5 mg/kg IM	Ketamine 1-2 mg/kg + Midazolam 0.01-0.5mg/kg IV
<b>Onset</b>	1-5 min	4-5 min	Same as IV
<b>Duration</b>	Approx. 20min	Approx. 25 min	> 25 min
<b>Benefits</b>	1. Provides Analgesia, Sedation and Amnesia 2. Predictable onset and offset. 3. Does not decrease respiratory drive.	Same as IV	1. Theoretically postulated to reduce emergence reaction → no evidence to support this. 2. Good for long procedures. 3. Reduced emesis
<b>Side-effects</b>	Emesis Laryngospasm Emergence reaction	Similar IV but higher rate of emesis	Prolongs recovery time
<b>Recovery</b>	Approx. 60 min	Approx. 90-120 min	> 120 min



### Pitfall:

Using ketamine in children younger than three months of age has an increased rate of respiratory complications, and animal studies have implicated NMDA antagonists as a cause of apoptosis and neurodegeneration in developing brains.



**IV ketamine is generally preferred over IM ketamine.** IM ketamine has a longer recovery period and a higher rate of emesis, and is difficult to titrate if more sedation is needed.



**Rapid push dose of IV ketamine at 0.8 mg/kg** as an alternative to slow IV push ketamine has been evaluated by Chinta et al. in a pilot study of 20 children. The preliminary data are encouraging, as the success of adequate sedation and adverse reactions seen were comparable to the standard dose and slow IV push while having a shorter recovery time. However, rapid-push dose IV ketamine cannot be recommended for pediatric procedural sedation until a large, validated RCT has shown definitive results.



### **Clinical Pearl:**

**Benzodiazepines** are useful for treating the rare emergency reactions that are associated with ketamine, but they do not decrease the likelihood of an emergency reaction occurring. Furthermore, co-administration of midazolam increases the risk of respiratory complications, even though the risk of emesis is reduced.

**Q: What other medication options besides ketamine would you consider?**

**A:**

### **Etomidate**

Etomidate has been shown to be safe for procedural sedation in the pediatric population. Its benefits include a favourable hemodynamic profile and short duration of action. Consider how much time you anticipate the procedure to last, as etomidate is best suited for short procedures.



### **Etomidate**

**Etomidate dosing for pediatric procedural sedation:** 0.1 to 0.2 mg/kg slow IV push

## Propofol

The risks of respiratory depression with propofol are much higher than with ketamine. In addition, propofol does not have any analgesic properties, so it is recommended that it be combined with an analgesic such as fentanyl.



## Propofol

**Propofol dosing for pediatric procedural sedation:** 0.5 to 1 mg/kg slow IV push

## Nitrous oxide (NO)

Nitrous oxide is a weak dissociative anesthetic and it gives a rapid, reliable change in depth of analgesia and sedation with a rapid recovery. Effective analgesia can often be obtained with local lidocaine or regional nerve blocks, but we still require a calm and sedated child to complete the procedure. Nitrous oxide is especially well-suited for the patient who requires more **anxiolysis** than pain control. Examples of procedures where nitrous oxide would be a reasonable option include genital lacerations and reduction of forearm fractures.



## Nitrous Oxide (NO)

**Dosing NO:** Nitrous oxide is delivered by nebulizer via a gas system, usually 50% NO as a baseline dose. Some machines will allow you to adjust the percentage of nitrous the patient is inhaling so you can titrate the depth of sedation. You can add an opioid or benzodiazepine to achieve a deeper sedation.

**Time of onset:** approximately three to five minutes

**Recovery:** approximately three to five minutes



Studies have shown that nitrous oxide sedation, in conjunction with a hematoma block for forearm fractures, was just as effective as IV ketamine and midazolam, and had a faster recovery time.



**Q: One of your senior EM doc colleagues pokes his head in the room and asks, “Why don’t you just use good old fentanyl and midazolam? I’ve been using that for conscious sedation on kids for 30 years.” Are fentanyl and midazolam a good choice for procedural sedation?**

**A: Fentanyl + midazolam**

A combination of fentanyl and midazolam used to be a popular cocktail for procedural sedation. This combination is **no longer recommended** as it has been associated with a high incidence of adverse events, including respiratory depression and apnea.

**Q: Then your student asks, “What about ‘ketofol’—the combination of ketamine and propofol?”**

**A:** Using ketamine and propofol in combination has a theoretical decreased risk of adverse events due to decreased dosing of each agent. “Ketofol” has been shown to have a shorter recovery time compared with either agent alone. Some experts argue that in the event the patient has an allergic reaction, one doesn’t know which agent caused the reaction, and therefore neither agent can be used again in that patient, leaving fewer options available the next time they require sedation. In combination, the recommended doses for ketofol are ketamine 0.5 mg/kg followed by propofol 0.5-1 mg/kg, or both drugs mixed into the same syringe and given at once together.

**Q: You begin the procedural sedation and the patient begins to desaturate. What are the risk factors for a failed sedation (hypoxia, apnea)?**

**A:**



**Clinical Pearl:**

- Active upper respiratory tract infection
- > ASA class 2+
- Obesity or sleep apnea, or history of snoring
- Older than seven years

**Q: With some supplemental oxygen and repositioning, the patient improves. The parents come back in the room and ask you how long they have to wait until they can go home. After uncomplicated procedural sedations, how long should you continue to observe the patient for?**

**A:** The length of observation time depends on the agents used and the patient's reaction to the medications. When the patient has returned to their normal developmentally appropriate motor, cognitive, and social functions; when they can tolerate PO; if they have a reliable monitoring plan at home (and the family is comfortable with this plan), they are safe to go home.



### Dosing Pocket Guide

Agent	Actions	Dose (add = additional)	Onset of Action (min)	Duration of Action (min)
<b>Ketamine</b>	Sedative Analgesic Amnestic	<b>IV</b> 1-2mg/kg slow push add 0.5-1mg/kg	1-5	10-15
		<b>IM</b> 4-5mg/kg add 2-2.5mg/kg	5	20
<b>Propofol</b>	Sedative	<b>IV</b> 0.5-1mg/kg slow push add 0.5mg/kg	0.5	5
<b>Etomidate</b>	Sedative	<b>IV</b> 0.1 mg/kg	1	3-5
<b>Midazolam</b>	Sedative Amnestic	<b>IN</b> 0.2-0.3 mg/kg	3-5	30-60
	Anxiolytic	<b>IV</b> 0.05-0.1 mg/kg	3-5	
<b>Fentanyl</b>	Analgesic Sedative	<b>IV</b> 0.5-1 mcg/kg add 0.5mcg/kg	Immediate	30-60
		<b>IN</b> 1.5 mcg/kg	1-2	
<b>Nitrous Oxide</b>	Anxiolytic Amnestic Analgesic	Titrated up to a max of 70%	3	2-3 (post discontinuation)

## CASE 2: PROCEDURAL SEDATION FOR SHORT, NON-PAINFUL PROCEDURES

An 11 month-old boy falls out his mother's arms as she trips down the stairs. She saw him hit his head. He had a loss of consciousness of one minute and vomited several times after the event. He presents with a GCS of 13 and no signs of basal skull fracture, and point-of-care ultrasound shows no skull fracture. He is agitated, but appears to be suffering from a minimal amount of pain.

**Q: After a full clinical assessment with consideration of the PECARN clinical decision aid (see Chapter 4 on Head Injury), you decide to send the child for a CT scan of his head. You are concerned he will not be able to tolerate the scan and feel that he needs to be sedated. What strategies can you use in this scenario?**

**A:** Non-painful short procedures can begin with distraction techniques (see Chapter 3 on Pain Management). If distraction techniques are ineffective, intranasal midazolam is recommended as the first-line therapy for sedation. If IN midazolam is not available, oral midazolam is recommended.



### Midazolam Dosing

**Intranasal dose:** 0.3 mg/kg (max 10 mg); time of onset: seven to 10 minutes

**Oral dose:** 0.7 mg/kg (max 20 mg); time of onset: 15–20 minutes



### Pitfall:

Before administering midazolam, consider the recovery time and that it may cloud your physical and neurological assessments of the patient. Perform a good neurological exam before the sedation, or else you won't be able to give the neurosurgical team an accurate report if they are consulted!

## CASE 3: PROCEDURAL SEDATION FOR LUMBAR PUNCTURE

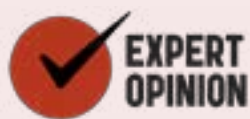A three-year-old male infant presents to the ED with a temperature of 39.7°C, heart rate of 190, and mottled skin. There is no travel history and no identifiable source of infection; however, he is unimmunized. You begin your management with a full septic workup, IV fluids, and broad-spectrum antibiotics.

**Q: You are concerned that this patient could have meningitis, and you want to do a lumbar puncture. Is there anything you can do to make your patient more comfortable to help him tolerate the procedure?**

**A:** First, consider having the parents stay in the room to console the patient, if they are able to and they understand the procedure. Family presence has not been shown to increase the miss rates of the lumbar puncture.

An important intervention used to maximize the chances of success with lumbar puncture is adequate local pain control. Anesthetising the skin with topical lidocaine (LMX 4%) can be helpful in this regard without having to resort to the discomfort of injected lidocaine. LMX has an onset within 30 minutes with reliable anesthetic effect at about seven minutes, and was shown to increase success of lumbar puncture in two prospective observational studies of 428 and 1,474 patients.

Local pain control, along with distraction techniques, can often obviate the need for systemic sedation. For young infants who cannot be distracted, **sucrose has been shown to be an effective sedative.** Sucrose can often achieve the desired level of sedation such that other less safe medications are not required in infants younger than three months of age.



## Medications of Choice for Sedation for Lumbar Puncture

< Six months old:	Sucrose
Six months to five years:	IN midazolam (or oral midazolam if IN is not available)
> Five years:	Inhaled nitrous oxide or midazolam

For more on local puncture site management, go to Chapter 3: Pain Management.

**FOAMed link:** [Click here for the TREKK Summary and Recommendations for procedural sedation.](#)



### Comments?

[Click here to leave a comment  
or to listen to this podcast.](#)

---

## KEY REFERENCES:

1. <http://www.intranasal.net/PainControl/INpaincontroldefault.htm#Introduction>
2. Borland M, Jacobs I, King B, O'Brien D. A randomized controlled trial comparing intranasal fentanyl to intravenous morphine for managing acute pain in children in the emergency department. *Ann Emerg Med.* 2007; Mar;49(3):335-40.
3. Agrawal D, Manzi SF, Gupta R, Krauss B. Preprocedural fasting state and adverse events in children undergoing procedural sedation and analgesia in a pediatric emergency department. *Ann Emerg Med.* 2003; Nov;42(5):636-646.
4. Evered L, Bhatt M. TREKK Bottom Line Recommendations: Procedural Sedation. 2015. <http://cme02.med.umanitoba.ca/assets/trekk/assets/attachments/69/original/bottom-line-summary-procedural-sedation.pdf?1435343376>.
5. Krauss B, Green SM. Procedural sedation and analgesia in children. *Lancet.* 2006; Mar;367(9512):766-80.

6. Chinta SS, Schrock CR, McAllister JD, Jaffe DM, Liu J, Kennedy RM. Rapid administration technique of ketamine for pediatric forearm fracture reduction: a dose-finding study. *Ann Emerg Med*. 2015; Jun;65(6):640-648.
7. Cote CJ, Wilson S, the Work Group on Sedation. Guidelines for monitoring and management of pediatric patients during and after sedation for diagnostic and therapeutic procedures: an update. *Pediatrics*. 2006; Dec;118(6):2587-2602.
8. Krauss BS, Brauss BA, Green SM. Procedural Sedation and Analgesia in Children. *N Engl J Med*. 2014; 370:e23.
9. Foster D, Upton R, Christrup L, Popper L. Pharmacokinetics and pharmacodynamics of intranasal versus intravenous fentanyl in patients with pain after oral surgery. *Annals of Pharmacotherapy*, 2008; 42(10):1380-1387.
10. Wathen JE, Roback MG, Mackenzie T, Bothner JP. (2000). Does midazolam alter the clinical effects of intravenous ketamine sedation in children? A double-blind, randomized, controlled, emergency department trial. *Ann Emerg Med*. 2000; Dec;36(6):579-588.
11. Langston WT, Wathen JE, Roback MG, Bajaj L. Effect of ondansetron on the incidence of vomiting associated with ketamine sedation in children: a double-blind, randomized, placebo-controlled trial. *Ann Emerg Med*. 2008; Jul;52(1):30-34.
12. Shah A, Mosdossy G, McLeod S, Lehnhardt K, Peddle M, Rieder M. A blinded, randomized controlled trial to evaluate ketamine/propofol versus ketamine alone for procedural sedation in children. *Ann Emerg Med*. 2011; May;57(5), 425-433.
13. Grunwell JR, McCracken C, Fortenberry J, Stockwell J, Kamat P. Risk factors leading to failed procedural sedation in children outside the operating room. *Pediatr Emerg Care*. 2014; Jun;30(6), 381-387.
14. Langston WT, Wathen JE, Roback MG, Bajaj L. Effect of ondansetron on the incidence of vomiting associated with ketamine sedation in children: a double-blind, randomized, placebo-controlled trial. *Ann Emerg Med*. 2008; Jul;52(1):30-34
15. Andolfatto G, Willman E. A prospective case series of pediatric procedural sedation and analgesia in the emergency department using single-syringe ketamine-propofol combination (ketofol). *Acad Emerg Med*. 2010; Feb;17(2):194-201.
16. David H, Shipp J. A randomized controlled trial of ketamine/propofol versus propofol alone for emergency department procedural sedation. *Ann Emerg Med*. 2011;57:435-441
17. Deasy C, Babl FE. Intravenous vs intramuscular ketamine for pediatric procedural sedation by emergency medicine specialists: a review. *Paediatr Anaesth*. 2010; Sep;20(9):787-96.
18. Nigrovic LE, McQueen AA, Neuman,MI. Lumbar puncture success rate is not influenced by family-member presence. *Pediatrics*. 2007; Oct;120(4), e777-782.



# CHAPTER 6: ORTHOPEDIC INJURIES

[LISTEN TO THE PODCAST WITH SANJAY MEHTA AND JONATHAN PIRIE HERE](#)



## Objectives

1. Develop an approach to managing a child with an acute knee injury
2. Have an age-appropriate differential diagnosis for the limping child
3. Review the evidence for the diagnosis of septic arthritis in a child
4. Develop an approach to closed ankle injuries in children
5. Be able to assess children with a FOOSH
6. Be able to diagnose a supracondylar fracture and properly assess it

## CASE 1: KNEE INJURY

A mother presents to the emergency department with her 12-year-old son. While playing basketball in gym class, he planted his foot and rotated his left leg following a jump, resulting in a fall to the ground. He had to be carried off the court. He complains of severe pain in his left knee and says he cannot put weight on it. He says he may have heard a “pop” as he planted. He denies any other injury and is previously healthy with no medications or significant medical history.

On exam, his vitals are within normal limits. His left knee is swollen, with a ballotable effusion and is very tender to the touch diffusely. He is unable to extend completely and can flex only to about 45 degrees. There appears to be anterior laxity of the knee. He is unable to bear weight.

**Q: This history and physical exam are classic indicators of what diagnosis?**

**A:** The mechanism for an anterior cruciate ligament (ACL) rupture is classically rotation of the knee against an immobile foot, with sudden deceleration, often in sports such as basketball, tennis, and soccer. Often a “pop” is felt or heard, and significant swelling usually occurs within the first hour after injury with minimal ability to bear weight.

**Q: What is the most sensitive physical exam manoeuvre for ACL rupture?**

**A:** A meta-analysis from 2003 showed that the pivot shift test was the most sensitive (88.8%), followed by the Lachman test (77.7%), with the anterior drawer test having a sensitivity of only 22.2%. All three of these tests have a specificity of more than 95%.



### **Clinical Pearl:**

Always do a straight leg raise to rule out injury of the extensor mechanism of the knee for any knee injury.

**Video:** [Click here for a video on how to perform physical exam manoeuvres for ACL tears.](#)

**Q: For a patient with a suspected ACL tear, is an X-ray required? Does the clinical decision rule, the Ottawa Knee Rules, apply to children?**

**A:**



### **The Ottawa Knee Rules**

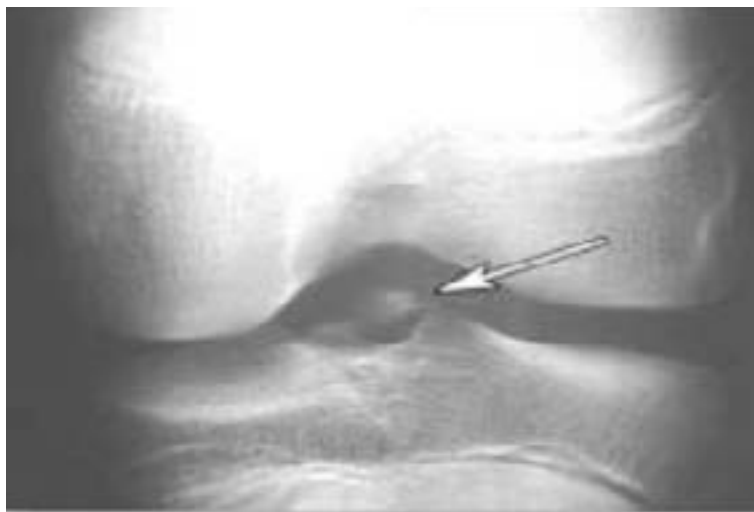A knee x-ray is indicated if ANY of the following is present:

- Age > 55 (clearly can be omitted in pediatrics )
- Pain at the fibular head
- Isolated patellar tenderness
- Inability to flex the knee to 90 degrees
- Inability to walk four weight-bearing steps both immediately and in the ED

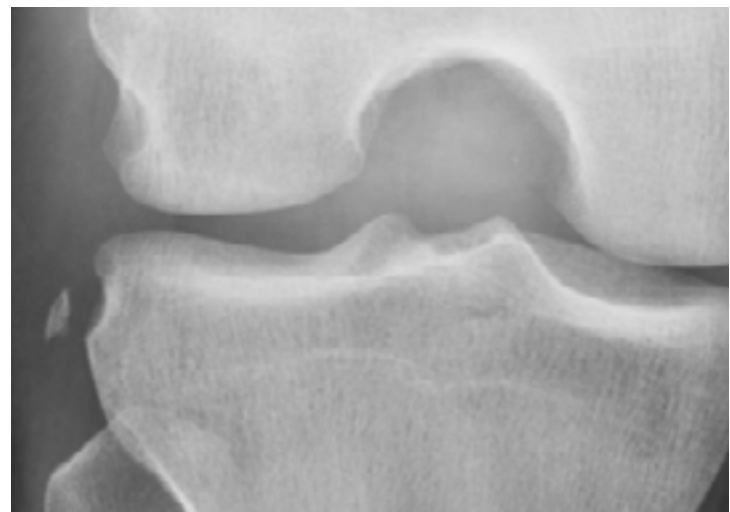
[The Ottawa Knee Rules](#) are 100% sensitive in children for clinically significant fractures and help reduce X-rays by 31%. Note that the patient in our case would require an X-ray per the Ottawa Knee Rules regardless of a suspicion of an ACL tear, because of the inability to bear weight.

**A:** Associated with ACL injuries, particularly in younger patients, are:

1. Tibial spine fracture
2. Second fracture, a vertically oriented avulsion fracture off the lateral proximal tibia



Tibial spine fracture



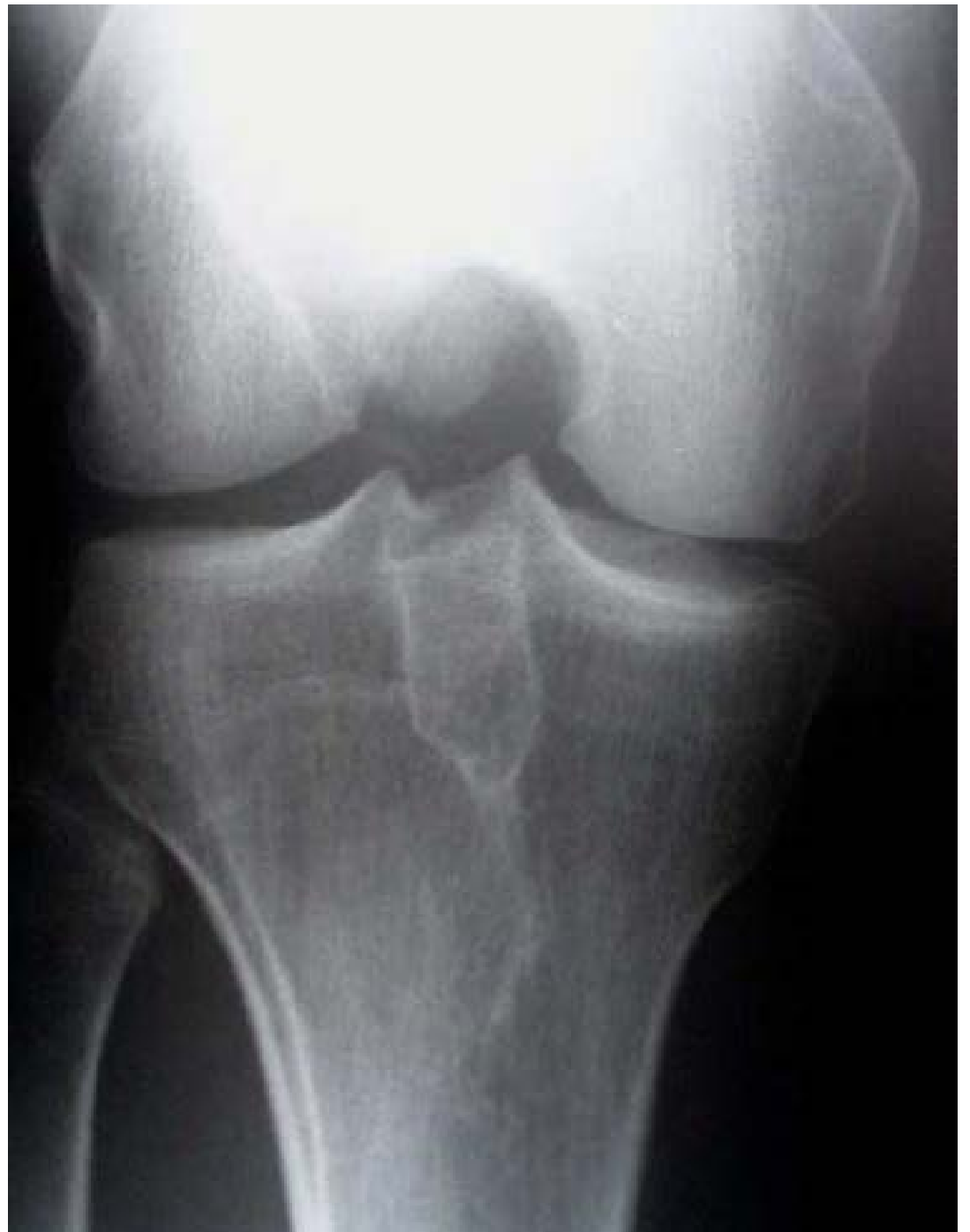Second avulsion fracture

**! Caution!**

In general, children's ligaments are stronger than their bones, and so fractures are more likely than sprains. Therefore, have a low threshold for ordering X-rays in children. Through adolescence and adulthood the opposite is true, as bones become stronger than ligaments, and so sprains are more likely than fractures.

**Q: What additional X-ray views should I consider obtaining aside from the A-P and lateral, for suspected tibial spine and plateau fractures?**

**A:** Tibial spine and tibial plateau fractures are best seen on a **"tunnel view."**



**Q: What is the ED management of suspected ACL rupture?**

**A:** Removable splint as needed, crutches, and ROM exercises as tolerated until the patient can be re-examined in two to three days or up to five days later, once the swelling and pain have improved.

In general, patients with ligamentous injuries of the knee (not only ACL injuries but also MCL injuries, or patients whose injuries you are unsure of but whose X-rays are negative and you suspect a ligament or meniscus injury) should be encouraged to remove their immobilizers and begin gentle range-of-motion exercises in two to three days to avoid quadriceps atrophy, which would lead to prolonged rehabilitation.

ACL tears are being repaired more frequently in pediatrics than in the past. However, there's no rush to get them to the surgeon, as most surgeons recommend delaying surgery until full range of motion has been recovered.

Any displaced fractures or fractures with an impaired extensor mechanism associated with a suspected ACL rupture need urgent orthopedic consultation.



Some experts recommend no immobilizers for these so-called “soft tissue injuries,” with weight bearing as tolerated.



**Clinical Pearl:**

Children who present with knee pain often have a diagnosis arising from the hip as a source of their pain, so look proximally if the clinical picture doesn't fit.

## CASE 2: THE CHILD WITH A LIMP

A two-and-half-year-old girl who attends daycare presents to the ED with a two-day history of limp and refusal to weight bear. Her parents report a temperature of 38.2°C at home for the past two days and say that she's not eating and drinking as much as usual. They brought her in because today, when they attempted to move the child's leg, she started to cry. There has been no significant recent trauma, except for a minor trip and fall while running on the sidewalk three days prior. She has had a runny nose and cough for the past three days, but no difficulty breathing, and no vomiting, diarrhea, or rash. There has been no recent travel and no contacts. She has no significant past medical history.

On exam, the child appears alert but anxious and in pain on Mom's lap, with no apparent respiratory distress. Vital signs reveal a temperature of 37.9°C, a heart rate of 124, a respiratory rate of 30, and an oxygen saturation of 99% on room air.

Her ENT exam is normal except for nasal discharge. Chest is clear. There are a few scattered bruises on the shins. When you attempt any movement of the right knee, the child cries. Palpation of the right hip also elicits crying. The child refuses to bear weight when you attempt to examine her gait.



### **Approach to a child with a limp**

1. Rule out septic arthritis
2. Look for fractures—ask about traumas (can be subtle)
3. Look for signs of systemic illness, such as a rash, fever, bruising
4. Consider age-specific diagnoses as appropriate





### **Clinical Pearl:**

If the initial physical exam is not revealing due to an unco-operative child, give analgesia and re-examine the patient in 30 to 60 minutes.

### **Q. Does this child have a septic arthritis?**

**A:** Septic arthritis should cross your mind for any monoarthropathy, particularly in the hip, which is the most common site in children. There is no single tool or piece of information that can reliably rule out or rule in septic arthritis without obtaining a synovial fluid sample. However, there are tools available to assist in making the decision whether to perform a joint tap.

**Case continued:** WBC count comes back at 14.5, CRP at 20, and ESR at 40.

### **Q. Can we use the information we have so far in this case to rule in or out septic arthritis?**

**A:** [The Kocher Criteria](#) can be a helpful tool to help risk stratify a patient whom you suspect might have septic arthritis. It is best used as a rule in and is not a very sensitive test on prospective validation. When all four criteria are present, the probability of septic arthritis is 99.6%.



### **The Kocher Criteria**

1. Non-weight-bearing on the affected side
2. ESR > 40 mm/hr
3. Fever
4. WBC count > 12,000

### **Q. How useful is CRP in risk stratifying patients with suspected septic arthritis?**

**A:** [On a retrospective review](#) of 311 children with a hip effusion, those with a CRP > 20 mg/l had an odds ratio of 81.9 of having a septic arthritis. However, like other factors, it is neither specific nor sensitive enough to rule a septic arthritis in or out. In the context of a low pre-test probability, negative CRP and ESR have a fairly good negative predictive value.

**Treatment:** In patients in whom you suspect septic arthritis, usually you can wait to start empiric IV antibiotics until after the joint can be aspirated. However, if there will be a significant delay to joint aspiration, start antibiotics on speculation.

### **Q. What is transient synovitis of the hip?**

**A:** Transient synovitis of the hip is a self-limited inflammation of the synovial lining. It is often preceded by a viral infection, and should resolve in three to 10 days. However, concurrent illness can make diagnosis challenging. Pay attention to vital signs, general appearance and symptom progression. The presence of an effusion on ultrasonography does not differentiate between septic arthritis and transient synovitis.

**FOAMed link:** [For more information on differentiating synovitis from septic arthritis, see this post on Academic Life in EM blog here.](#)

### **Q. What is the role of ultrasound in the workup of suspected septic arthritis?**

**A:** Most effusions can be detected by ultrasonography; however, effusions do not differentiate septic arthritis from transient synovitis.

The sensitivity of ultrasound for an effusion is 95-100%. However, up to 5% of septic hip ultrasounds can be negative initially, which typically occurs in early presentations, less than 24 hours into the disease course.



## Investigating Septic Arthritis

Some experts suggest the following ultrasound-based algorithm:

### **Low pre-test probability + negative ultrasound:**

Careful outpatient follow-up

### **Moderate pre-test probability + < 24 hours symptoms**

Ultrasound

- If negative, then repeat ultrasound in 12 hrs or MRI
- If positive then arthrocentesis for synovial fluid analysis

### **Moderate pre-test probability + > 24 hours symptoms**

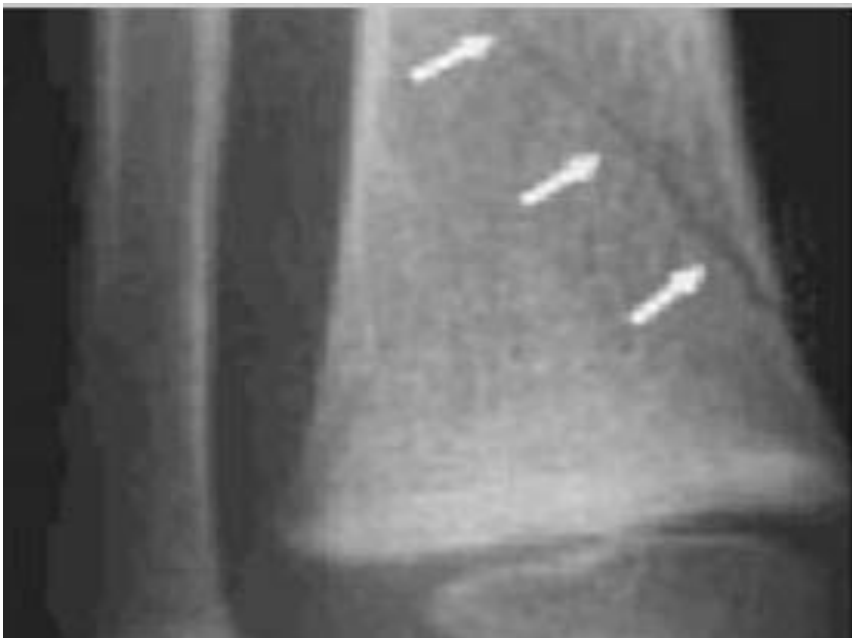
Ultrasound

- If negative, then discharge with follow-up
- If positive, then arthrocentesis for synovial fluid analysis

**Q: Next in the approach to the child with a limp after differentiating transient synovitis from septic arthritis is looking for fractures. What is the most commonly missed fracture that presents in a toddler with a limp?**

**A:** A commonly missed occult fracture is the **toddler's fracture** (spiral fracture in children nine to 36 months, usually of distal tibia). The mechanism of injury is often minor (simple twisting mechanism) or there is no report of injury at all! It can present with subtle physical exam and X-ray findings. There is usually minimal or no swelling and subtle, difficult to localize point tenderness. Pain with ankle dorsiflexion or calf rotation should raise suspicion. Oblique views can help visualize the fracture and increase X-ray sensitivity.

Toddler's fractures are treated with an **above-knee immobilizing splint with the knee in slight flexion**, and orthopedic follow-up. However, if X-rays are normal and symptoms are mild, consider follow-up without a cast after discussing pros/cons with parents. If you have a high suspicion despite a normal X-ray, consider a long leg splint with close follow-up. Ultrasound can sometimes pick up the fracture if clinical suspicion is high but X-rays are normal.



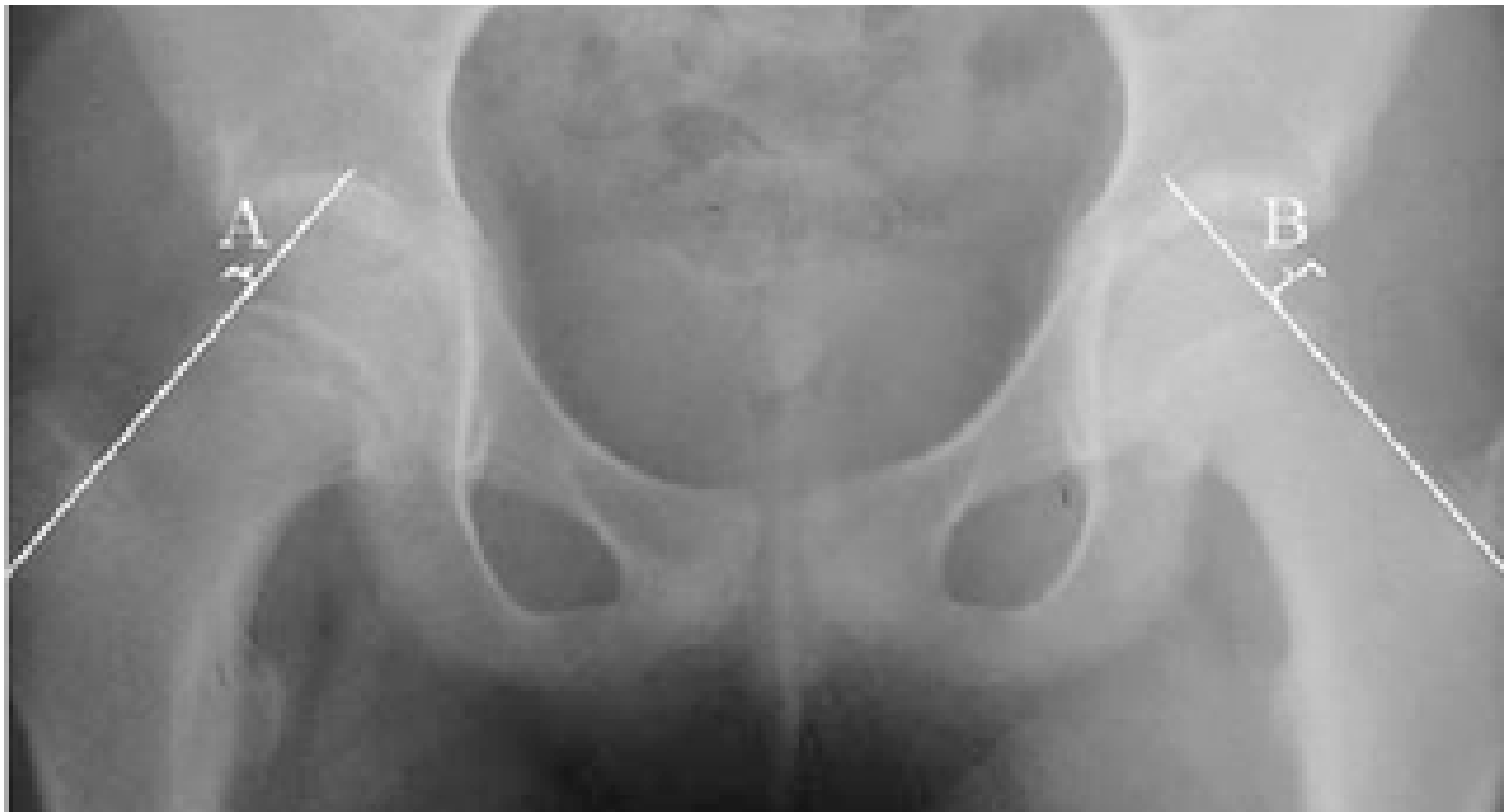Toddler's fracture

**Q. Next in the approach to the child with a limp is ruling out systemic illness. This can usually be assessed with a careful history and a physical for signs and symptoms of systemic illness such as rash, lethargy, etc. Finally, age-specific diagnoses should be considered. Which age-specific diagnoses should we consider in the child presenting with a limp?**

**A: Legg-Calvé-Perthes disease (LCPD)** is an avascular necrosis of the femoral head, typically seen in children ages four to 10. It can present insidiously or may follow an injury. The initial X-ray can be normal or show a very subtle change in femoral head appearance. Speak to the radiologist on call to carefully review the images, and follow with a bone scan or MRI if very suspicious.

**Slipped capital femoral epiphyses (SCFE)** is easy to miss! It can present subtly, with pain that radiates into the thigh or knee. Typical patients are older children and those who are overweight, but also skeletally immature. On exam, pain is usually greatest with internal rotation of the hip, and they can present with the hip held in external rotation.

- Get X-rays of both hips, including frog's-leg view in addition to standard views. Draw a **Kline's line** from the external part of the femoral neck, which should intersect part of the femoral head. As it slips, the femoral head becomes medial to that line. Compare both sides, but remember SCFE can be bilateral.
- If suspicious, call orthopedics—these cases need surgical management and SCFE will worsen if patients continue to bear weight.



Kline's line for SCFE





## Non-accidental Trauma

Some fractures should always raise suspicion for non-accidental trauma (i.e., posterior rib fractures). However, non-accidental trauma can result in any type of fracture pattern. Always remember to be systematic when taking histories, and document carefully! Clues include:

- 1. Delay in presentation
- 2. Vague or inconsistent explanation of mechanism
- 3. Mechanism described that is inconsistent with injury
- 4. Injury inconsistent with developmental stage of child

**FOAMed link:** [Click here for a short lecture on child abuse injury patterns from Academic Life in EM.](#)

**Q: Before leaving the subject of the acutely limping child, what discharge instructions should be given to the parents for the limping child with an unclear diagnosis?**

**A:** Avascular necrosis of the hip can be missed early in its course, so repeat imaging may be required if there is no improvement of symptoms.

Septic arthritis can be missed early in its course, so arthrocentesis may be required if fever progresses, systemic symptoms and signs develop, or pain increases.

Toddler's fracture can be easily missed on X-ray, so a repeat X-ray may be required if symptoms persist.

## CASE 3: ANKLE FRACTURES

A six-year-old boy is running during recess at school and twists his ankle. He's unable to walk afterward. On exam he's tender and swollen maximally over the distal fibula. The X-ray is normal.

**Q: Do the [Ottawa Ankle Rules](#) apply in children?**



**A:** Yes, [a 2009 meta-analysis](#) showed 98.5% sensitivity for ankle and mid-foot fractures in children older than five years, with nearly all the missed fractures being Salter-Harris I or classified as insignificant fractures.

[A 2001 prospective study](#) showed 100% sensitivity in ruling out clinically significant fractures in children using a “low-risk examination” technique where pain and swelling are limited only to the distal fibula and its associated ligaments.



### **The Ottawa Ankle Rules**

If any one of the following is present, the patient requires a radiograph:

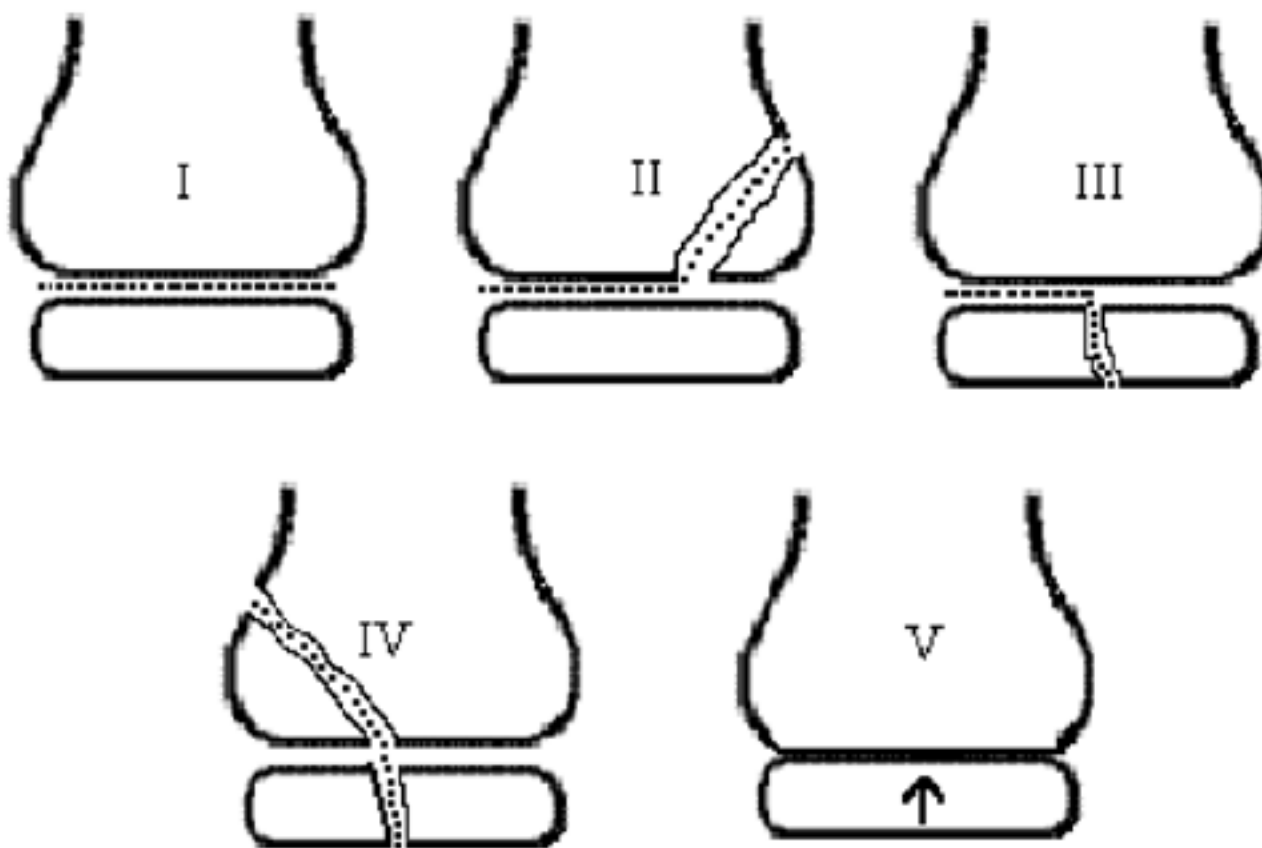
- 5.** Tenderness of the posterior edge of distal 6 cm of the fibula
- 6.** Tenderness of the posterior edge of distal 6 cm of the tibia
- 7.** Tenderness of the head of the fifth metatarsal
- 8.** Tenderness of the navicular
- 9.** Unable to bear weight immediately and at the emergency department

**EM Cases Cross-link:** [For images and explanations on clinical decision rules, click here for EM Cases' Stiell Sessions 1: CDRs and risk scales.](#)

**Q: What is the Salter-Harris pediatric fracture classification?**

**A:** The **Salter-Harris (SH)** system classifies fractures involving the growth plate of a long bone. These are common in the distal fibula. Fractures are classified from I to V and can be remembered by the mnemonic SALTR:

- I – **S** = **Slip**. Fracture of the cartilage of the physis (growth plate)
- II – **A** = **Above**. Fracture above physis
- III – **L** = **Lower**. Fracture below the physis in the epiphysis
- IV – **T** = **Through**. Fracture is through the metaphysis, physis, and epiphysis
- V – **R** = **Rammed**. The physis has been crushed/heavily damaged



SH I and II fractures are the most common and rarely result in growth arrest.

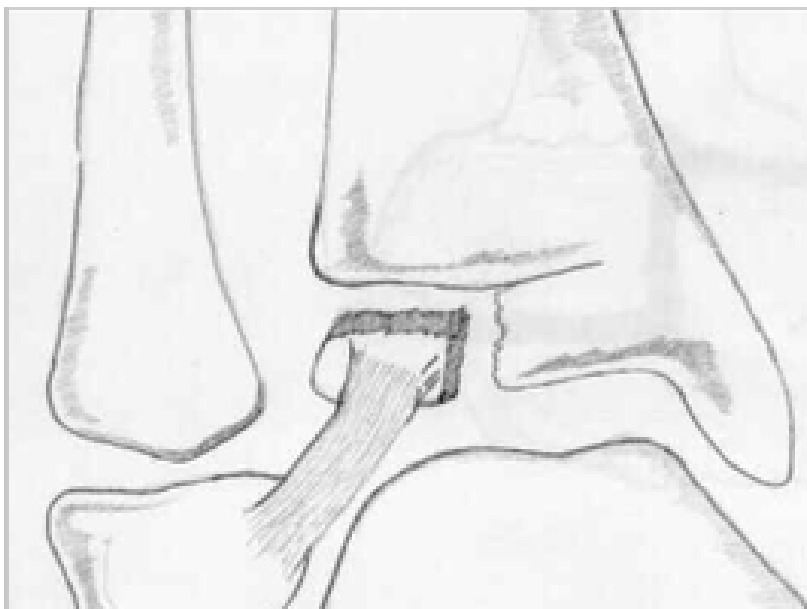MRI evidence suggests SH-I fractures are similar to a sprain, and do well when treated as such. Non-displaced SH-II lateral malleolar fractures (isolated non-displaced lateral malleolus fractures) heal as well in a removable over-the-shoe ankle air-stirrup brace with weight bearing as tolerated as in a cast or boot, but patients prefer an ankle air-stirrup brace, and mobilize earlier.

[Click here for the Canadian Paediatric Society statement on pediatric ankle sprains.](#)

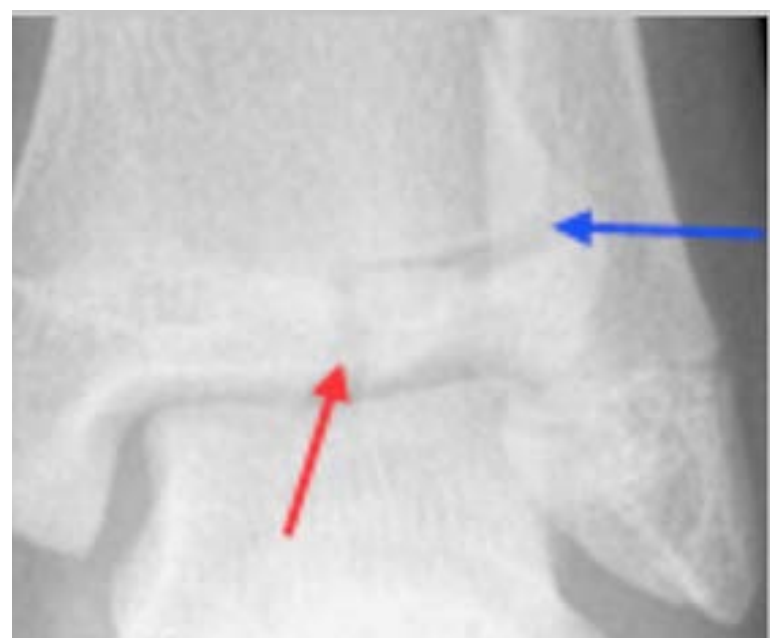

**Two specific SH fractures are easy to miss in the pediatric population:**

- 1. Tillaux fracture** is an intra-articular SH-III with avulsion of the anterolateral tibial epiphysis, often from a low-energy mechanism of external rotation of the foot or medial rotation of the leg on a fixed foot in children with partial growth plate fusion (ages 11–15). Pain and tenderness are at the anterior joint line of the ankle.
- 2. Look carefully for a distal tibia triplanar fracture** in adolescents (an unstable combination of SH-I, II and III), which requires operative management.



Tillaux ankle fracture of the distal tibia



Triplanar ankle fracture of the distal tibia

## CASE 4: THE FAST FOOSH

A 12-year-old boy was running on the sidewalk. He tripped and fell on his outstretched right hand. He complains of pain at his wrist only. Examination from the elbow to the snuffbox reveals slight tenderness at the distal radius. He is neurovascularly intact.

On X-ray there is a buckle fracture of the distal radius.

**Q: What is a buckle fracture and how is it managed, compared with a greenstick fracture and a transverse fracture of the distal radius?**

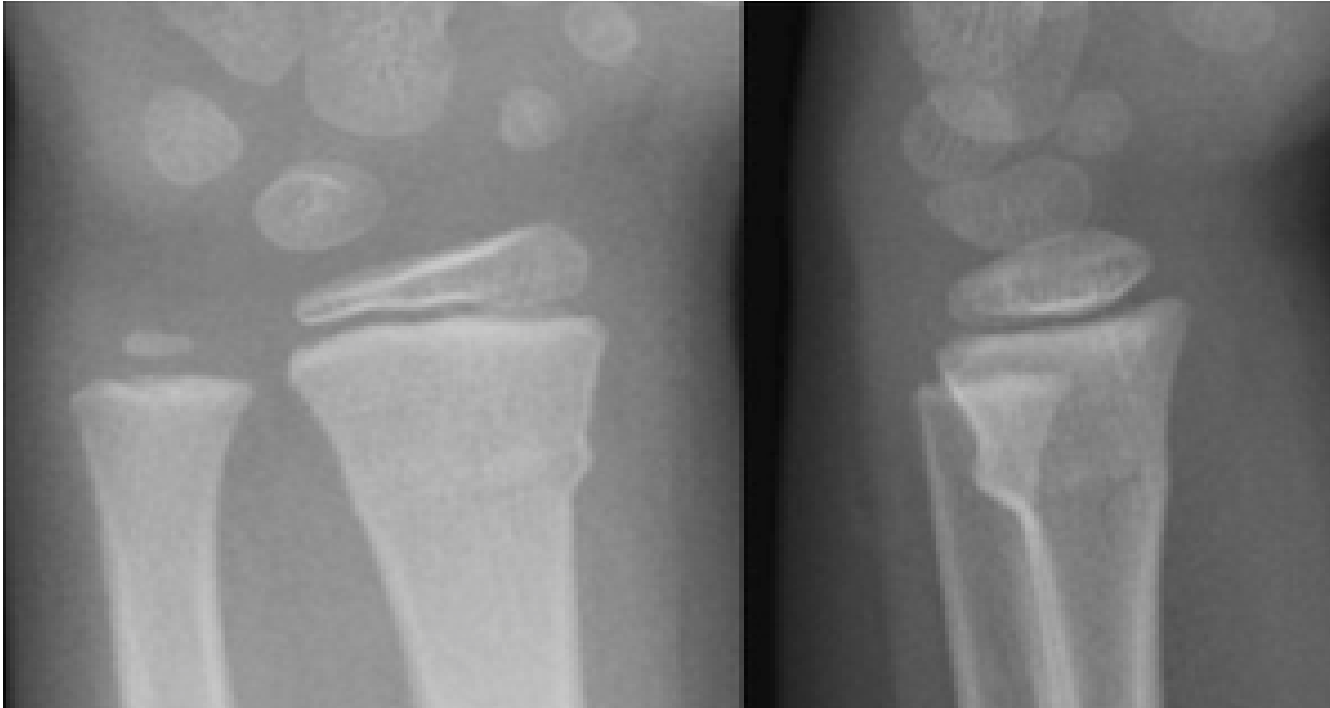
**A:** A **buckle fracture**, also known as a torus fracture, is an incomplete fracture of a long bone that is commonly identified by bulging of the cortex. The main mechanism is axial compression of soft, immature bones in children.

Buckle fractures of the distal radius heal well in a removable splint, and studies show that patients prefer this over a cast. A randomized, controlled trial showed better physical function, less difficulty with activities, the ability to return to sports sooner, and pain scores that are either not significantly different when compared with a short arm cast or are lower than with casting. There is even a study with just a soft bandage showing similar outcomes compared with a short arm cast.

Not only that, but studies have shown that the removal of the splint can safely be done at home rather than at a fracture clinic, guided by the child's symptoms. This of course assumes that the parents are agreeable, and are given good discharge instructions with regard to when they might need to seek medical care. In addition, parents prefer the removal of the splint at home over having to follow up at a fracture clinic.



Minimally angulated greenstick fractures (one cortex broken, the other intact) also do well with minimal splinting. Even minimally angulated transverse distal radius fractures of less than 15 degrees can also be treated effectively with a removable splint.



Minimally angulated buckle fracture of the distal radius

**Q: What are the acceptable degrees of angulation in pediatric distal radius fractures?**

**A:**

- < Five years old: up to 30 degrees is acceptable
- Five to 10 years old: up to 20 degrees is acceptable
- Ten to 12 years old: up to 15 degrees is acceptable

**! Caution!**

Bone in children remodels well in the dorsal/volar plane but not in the radial/ulnar plane, so if there is any displacement in the radial/ulnar plane, it usually needs to be reduced. On the other hand, if there is displacement in the dorsal/volar plane, you can accept more angulation and the bone will remodel well.

## CASE 5: THE FULL FOOSH

A 12-year-old boy was running on the sidewalk. He tripped and fell on his outstretched right hand. He complains of pain at his wrist only. Examination from the elbow to the snuffbox reveals slight tenderness at the distal radius. He is neurovascularly intact.

**Q: What are the most common fractures in general we can expect to see with a FOOSH mechanism?**

**A:** From distal to proximal: scaphoid, distal radius, radial head, suprachondylar, proximal humerus, and clavicle fractures.

**Q: Suprachondylar fractures are the most common elbow fractures in children and are rarely seen in patients older than 15 years. How should we assess neurologic status in children suspected of a suprachondylar fracture?**

**A:** Suprachondylar fractures have a high risk of neurologic and vascular injuries.

Brachial artery injury is reported in up to 20% of displaced fractures, with 80% of these regaining pulses after closed reduction.



### **Clinical Pearl:**

Five per cent of children with elbow fractures will have a second fracture at a distal site (at the wrist, for example), so it is imperative to examine the joint above and below the elbow for all children with elbow injuries.



### **Clinical Pearl:**

If the distal pulses are not palpable after a suprachondylar fracture, the child will usually be holding their arm in extension. Try flexing at the elbow 15 to 20 degrees and splint while waiting for emergency reduction.

The anterior interosseous nerve injury is the most common nerve injury in extension-type injuries, while ulnar neuropathy is the most common in flexion-type injuries.

To test motor function of the anterior interosseous nerve, look for weakness in flexors of IP joint of thumb and DIP joints of index and middle fingers by observing how the patient pinches using their thumb and index finger. Normally when an individual pinches something between their index finger and thumb, the MP and IP joints of the thumb and index finger are flexed; with nerve damage, the distal phalanges of the thumb and index finger are extended or hyper-extended.



Abnormal



Normal



## Upper Extremity Peripheral Nerve Testing

Ask the child to do hand signals to test motor function of each nerve.

- Radial nerve: make a “thumbs up”
- Median nerve: make a fist, and pinch a piece of paper with a pincer grip
- Ulna nerve: make scissors with the index and middle finger, or a “peace” sign

For the sensory examination, test the first dorsal webspace (radial), and the dorsum of the second or third fingertip (median) and fifth fingertip (ulna).



### Pitfall:

Avoid multiple attempts at closed reduction, given the vulnerable position of the neurovascular structures.

**Q: Compartment syndrome is a potential complication of suprachondylar fractures. How can the chances of compartment syndrome be minimized, and what would make you suspect compartment syndrome in a child with a suprachondylar fracture?**



### Pitfall:

Flexing the elbow to 90 degrees when immobilizing a patient with a suprachondylar fracture who has significant swelling may increase the risk of compartment syndrome, as this will decrease blood flow.

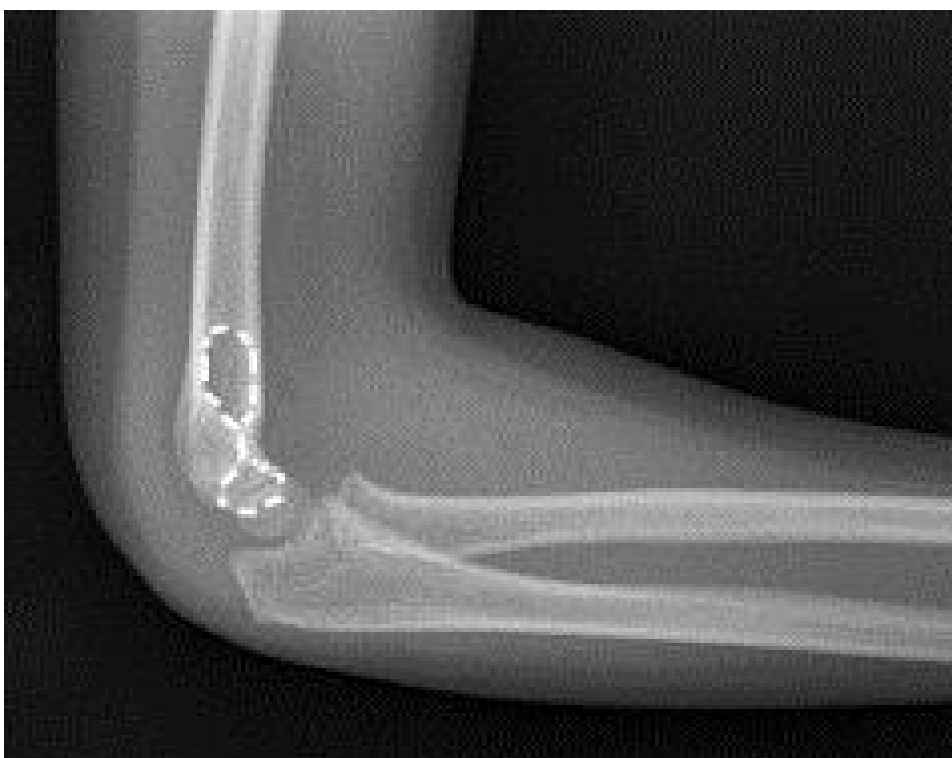**Q: What is your approach to the pediatric elbow X-ray?**

1. **“Figure of eight sign”**: Confirms a true lateral (see image)
2. **Anterior fat pad (“sail sign”)**: An enlarged, sail-shaped hypodensity should raise suspicion of a fracture
3. **Posterior fat pad**: Any hypodensity posterior to the humerus should raise suspicion of a fracture
4. **Radio-capitellar line**: A line through the middle of the radius normally bisects the capitellum; any disruption of this line should raise suspicion of a fracture
5. **Anterior humeral line**: A line along the anterior border of the humerus should bisect the middle third of the capitellum; any disruption should raise suspicion for a fracture
6. **CRITOE**: Capitellum, Radial head, Internal epicondyle, Trochlea, Olecranon, External epicondyle; review each ossification centre, which appears approximately every two years from ages two to 13 to rule out an avulsion fracture masquerading as an ossification centre

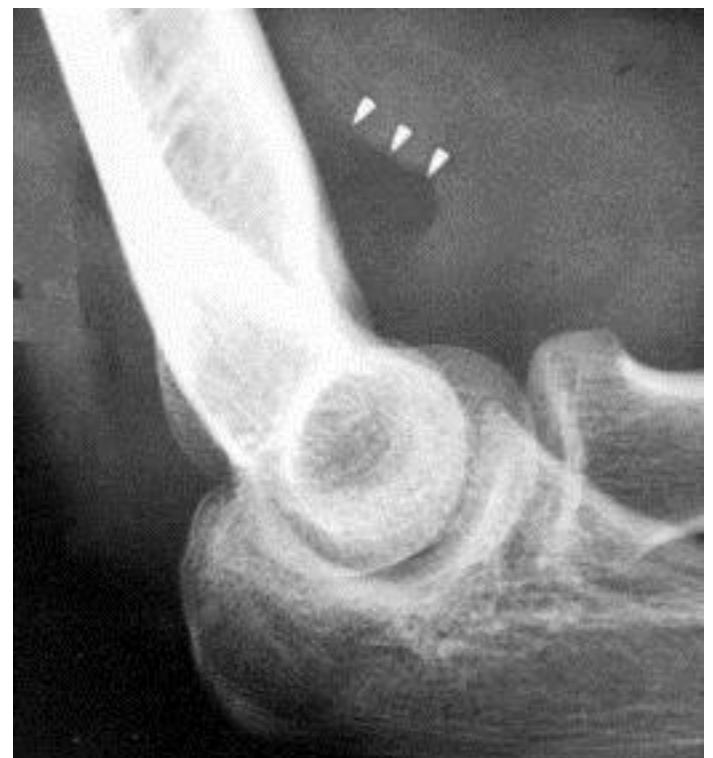

**Clinical Pearl:**

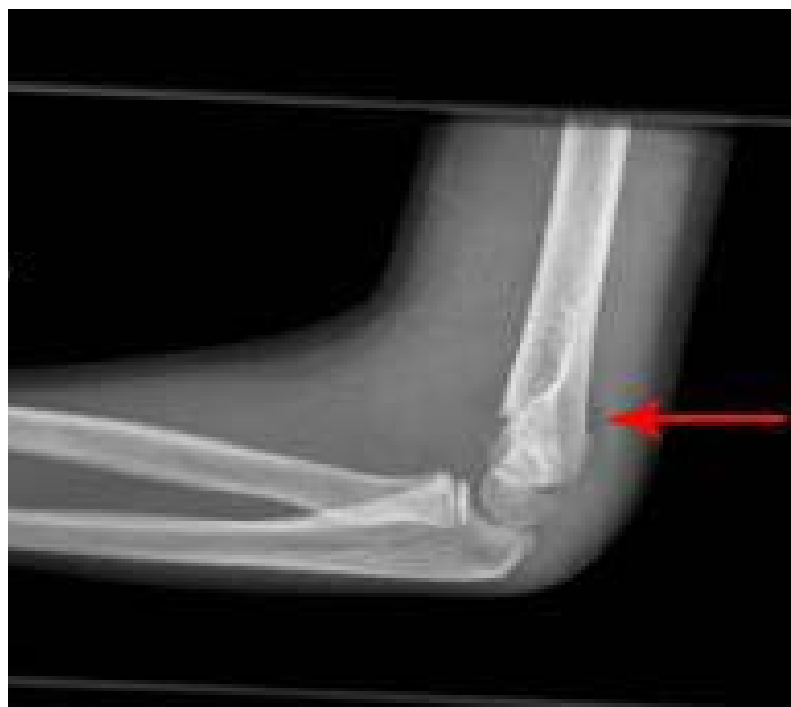Consider X-ray of opposite elbow for comparison.



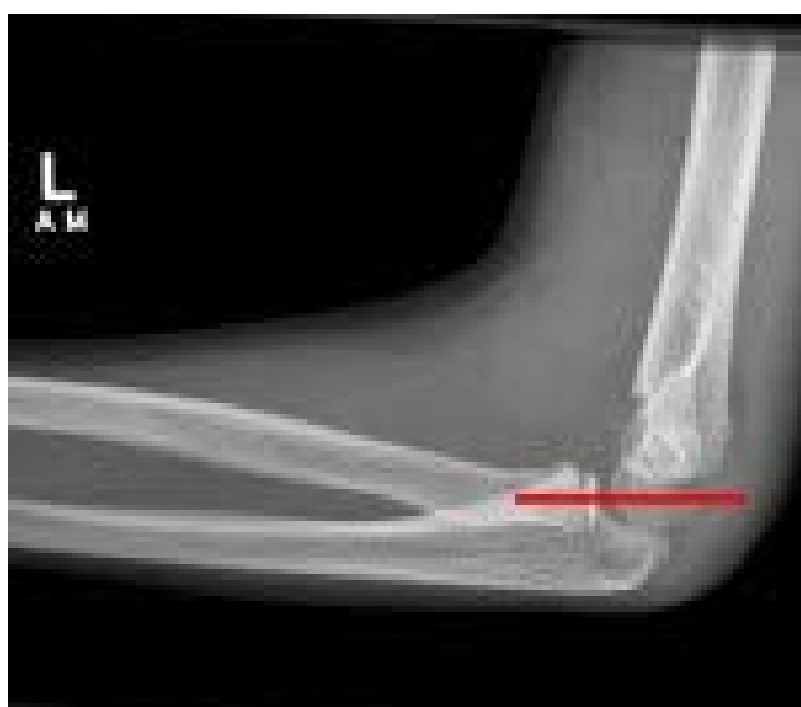1. “Figure of eight sign” confirms a true lateral



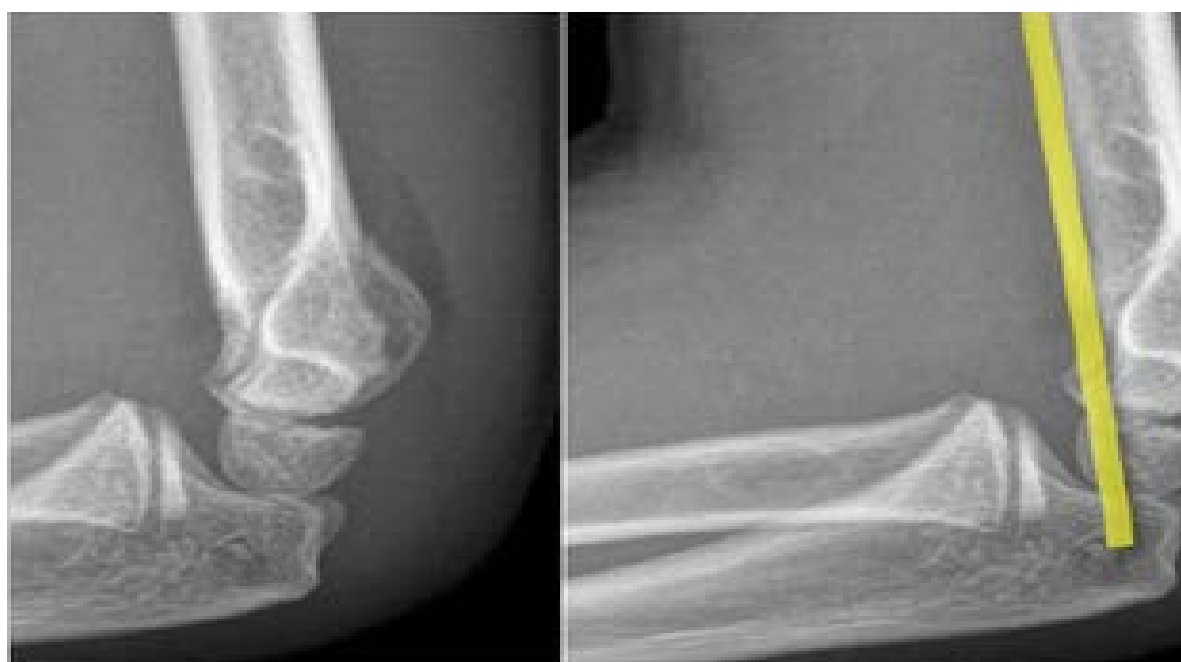2. Anterior “sail sign”



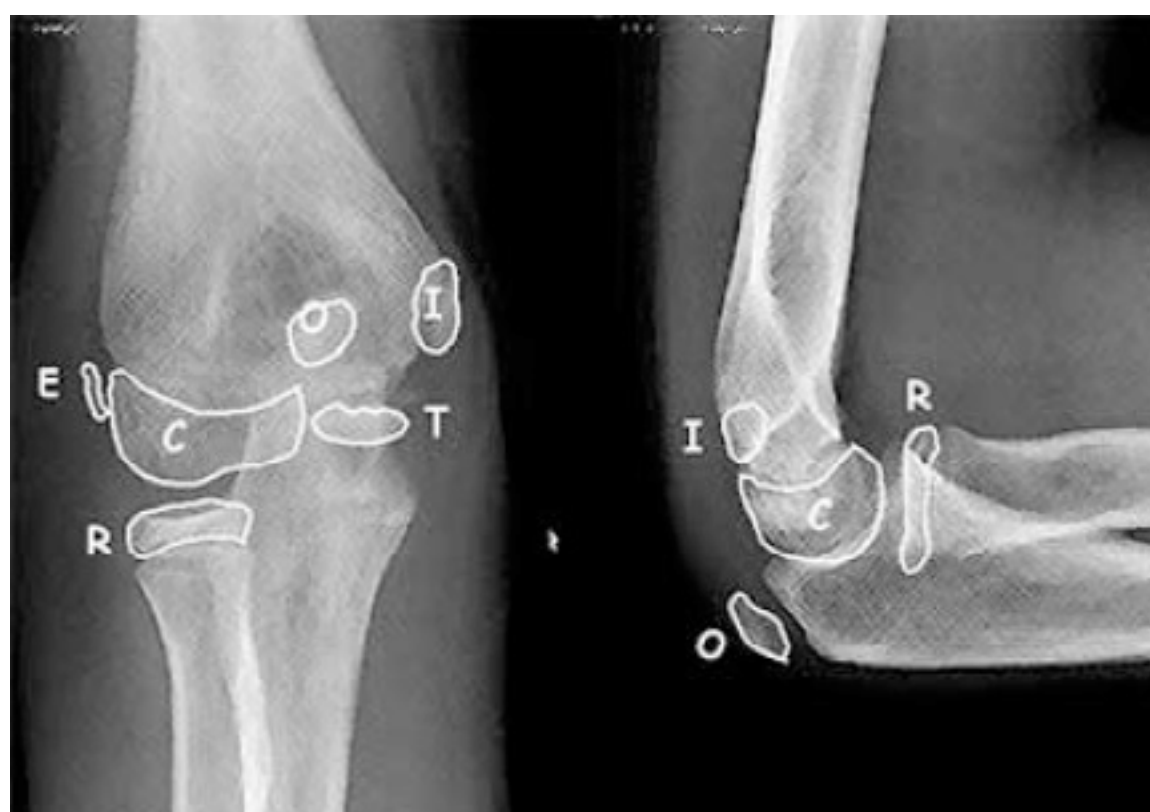3. Posterior fat pad



4. Radio-capitellar line



5. Suprachondylar fracture with posterior fat pad (left) and anterior humeral line (right)



6. CRITOE mnemonic for elbow growth plates

**C**apitellum  
**R**adial head  
**I**nternal (medial) epicondyle  
**T**rochlea  
**O**lecranon  
**E**xternal (lateral) epicondyle



**Q: How should suprachondylar fractures be managed in the ED?**

**A:** Suprachondylar fractures should be immobilized in an above-elbow splint with the elbow at  $> 90$  degrees of flexion and lots of padding. Orthopedic consultation in the ED is necessary for all displaced suprachondylar fractures. Non-displaced fractures can be immobilized and followed up by an orthopedic specialist.

**FOAMed Link:** [Click here for a video tutorial on suprachondylar fractures on Radiopaedia.](#)



**Pitfall:**

Do NOT apply a circumferential cast for suprachondylar fractures as it increases the risk for neurovascular damage and compartment syndrome.

Flexing the elbow to 90 degrees when immobilizing a patient with a suprachondylar fracture who has significant swelling may increase the risk of compartment syndrome, as this will decrease blood flow.



**Comments?**

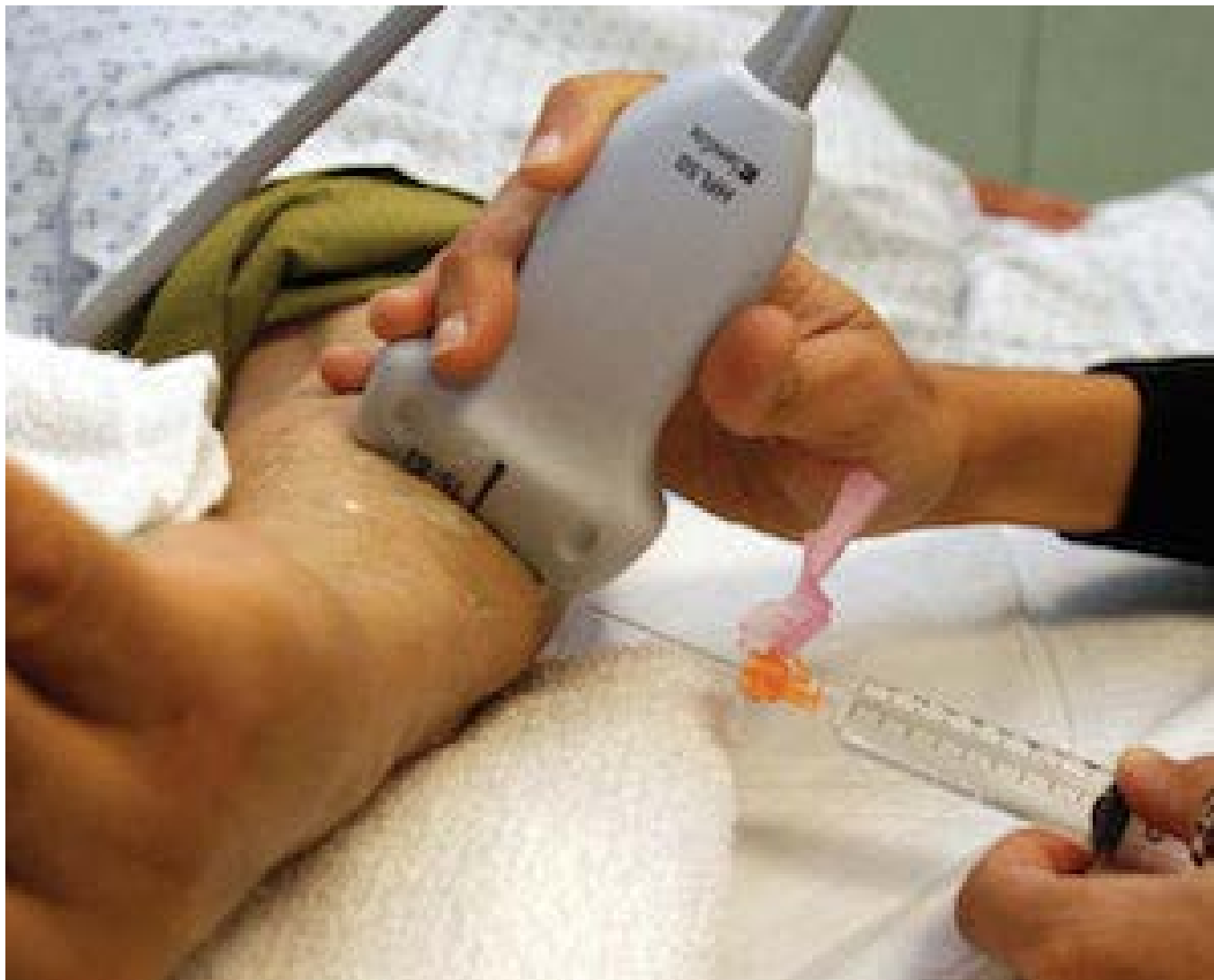[Click here to leave a comment or to listen to this podcast.](#)

## KEY REFERENCES:

1. Scholten RJ, Opstelten W, van der Plas CG, Bijl D, Deville WL, Bouter LM. Accuracy of physical diagnostic tests for assessing ruptures of the anterior cruciate ligament: a meta-analysis. *J Fam Pract.* 2003; Sep;52:689-694.
2. Stiell IG, Wells GA, Hoag RH, et al. Implementation of the Ottawa Knee Rule for the use of radiography in acute knee injuries. *JAMA.* 1997; Dec;278(23):2075-9.
3. Bulloch B, Neto G, Plint A, et al. Validation of the Ottawa Knee Rule in children: a multicenter study. *Ann Emerg Med.* 2003; Jul;42(1):48-55.
4. Kocher MS, Zurakowski D, Kasser JR. Differentiating between septic arthritis and transient synovitis of the hip in children: an evidence-based clinical prediction algorithm. *J Bone Joint Surg Am.* 1999; Dec;81(12):1662-70.
5. Kocher MS, Mandiga R, Zurakowski D, Barnewolt C, Kasser JR. Validation of a clinical prediction rule for the differentiation between septic arthritis and transient synovitis of the hip in children. *J Bone Joint Surg Am.* 2004; Aug;86-A(8):1629-35.
6. Singhal R, Perry DC, Khan FN, et al. The use of CRP within a clinical prediction algorithm for the differentiation of septic arthritis and transient synovitis in children. *J Bone Joint Surg Br.* 2011; Nov;93(11):1556-61.
7. Stiell IG, Greenberg GH, Mcknight RD, Nair RC, McDowell I, Worthington JR. A study to develop clinical decision rules for the use of radiography in acute ankle injuries. *Ann Emerg Med.* 1992; Apr;21(4):384-90.
8. Dowling S, Spooner CH, Liang Y, et al. Accuracy of Ottawa Ankle Rules to exclude fractures of the ankle and midfoot in children: a meta-analysis. *Acad Emerg Med.* 2009; Apr;16(4):277-87.
9. Boutis K, Komar L, Jaramillo D, et al. Sensitivity of a clinical examination to predict need for radiography in children with ankle injuries: a prospective study. *Lancet.* 2001; Dec;358(9299):2118-21.
10. Boutis K, Willan A, Babyn P, Goeree R, Howard A. Cast versus splint in children with minimally angulated fractures of the distal radius: a randomized controlled trial. *CMAJ.* 2010; Oct;182(14):1507-12.
11. Plint AC, Perry JJ, Correll R, Gaboury I, Lawton L. A randomized, controlled trial of removable splinting versus casting for wrist buckle fractures in children. *Pediatrics.* 2006; Mar;117:691-697.
12. West S, Andrews J, Bebbington A, Ennis O, Alderman P. Buckle fractures of the distal radius are safely treated in a soft bandage: a randomized prospective trial of bandage versus plaster cast. *J Pediatr Orthop.* 2005; 25(3):322-5.
13. Al-Ansari K, Howard A, Seeto B, Yoo S, Zaki S, Boutis K. Minimally angulated pediatric wrist fractures: is immobilization without manipulation enough? *CJEM.* 2007; Jan;9(1):9-15.

# CHAPTER 7: POCUS NERVE BLOCKS

[LISTEN TO THE PODCAST WITH JASON FISCHER HERE](#)



## Objectives

1. Understand the indications for performing forearm nerve blocks
2. Identify the radial, ulnar, and median nerve with POCUS
3. Perform the steps of POCUS-guided forearm nerve blocks of the radial, ulnar, and median nerve
4. Understand the complications and pitfalls of performing nerve blocks

## **? Q: Why should you care?**

**A:** Pain relief is one of the most important roles an emergency physician can perform, especially on a child. If a child has a painful experience in the emergency department, it is likely they will fear future pain, doctors, and hospitals. A properly performed forearm nerve block may not only completely eliminate a child's pain, but may also prevent future negative attitudes toward hospitals and health-care providers.

## **CASE 1: THE CASE OF PUTTING OUT FIRES WITH POCUS**

**Q: A four-year-old boy is brought into the emergency department after a firecracker exploded in his closed hand. Among other investigations and treatment, the child needs quick and effective pain relief. What are some of your options?**

**A:** While analgesics such as IN fentanyl and IV morphine have a rapid onset of action of a few minutes, they rarely eliminate the pain completely and often wear off before a definitive repair of injuries is performed in the operating room. A properly performed forearm nerve block will rapidly and completely eliminate all of the pain for hours until the patient can be taken to the operating room for surgical repair.



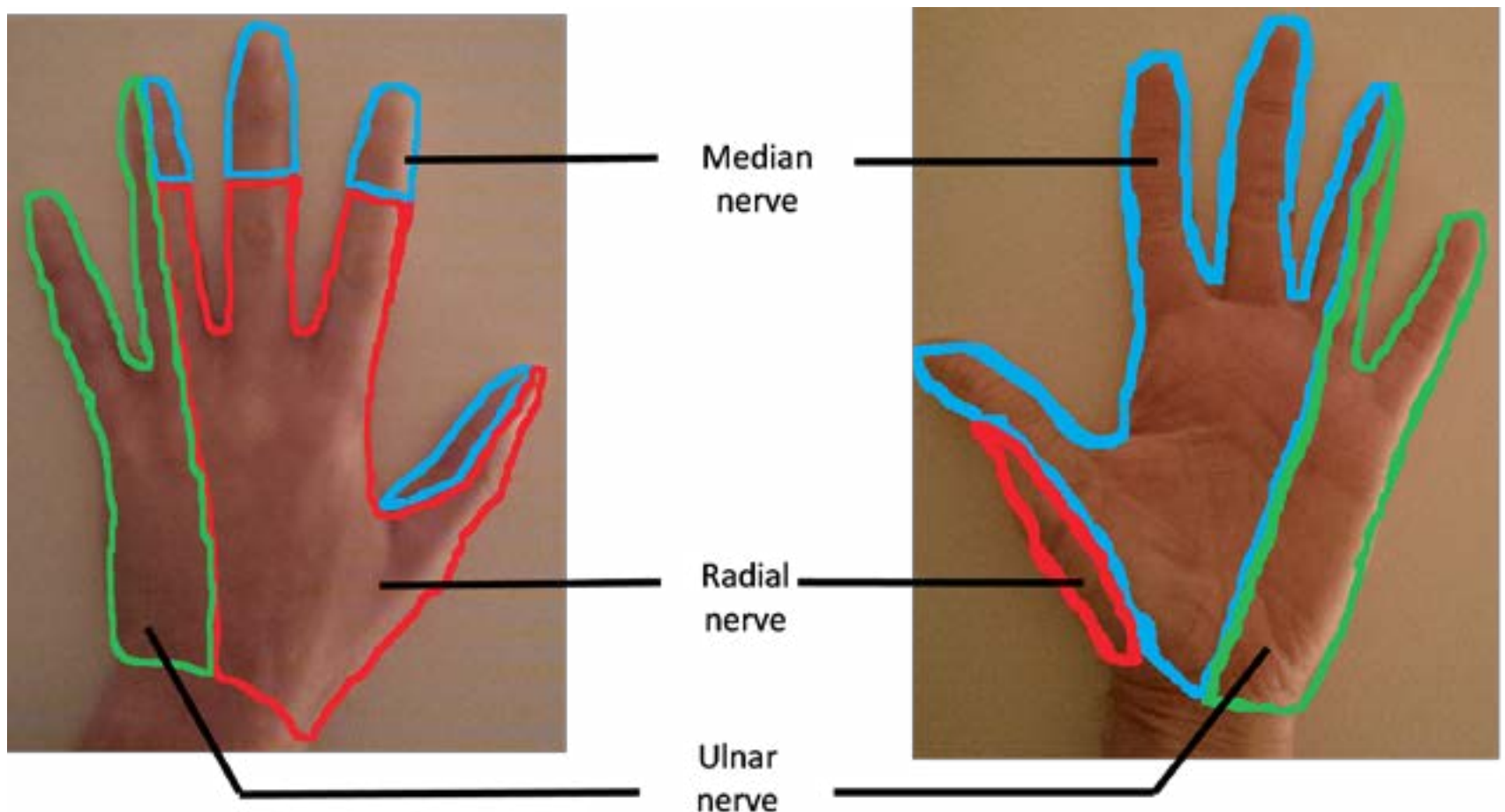
**Q: This case is a great example of a good indication for a forearm nerve block. What other situations would a forearm block be ideal for, where pain control might otherwise be challenging?**

- A:**
- Boxer's fractures
  - Multiple lacerations or complex lacerations
  - Burns requiring debridement and bandaging
  - Crush injury
  - Abscess incision and drainage



### Caution:

Forearm nerve blocks provide analgesia only to the hand, not the forearm. They are indicated only for significant hand injuries, not for forearm injuries.



**Q: You agree that an ultrasound-guided forearm nerve block is the best option for pain relief in this case. How do you prepare for a forearm nerve block?**

### **A: Step 1: Position**

The patient should be placed in a position of comfort that allows the target limb to be accessible to the ultrasound probe. This is usually achieved by having the patient sit in a chair with their arm prone on a bedside table. The ultrasound screen and the injection site should be aligned in the operator's direct line of vision to reduce unnecessary head movement.



### **Clinical Pearl:**

Use of tape, trays, or papoose to reduce the child's movements (especially infants and toddlers) may be necessary to keep the targeted limb immobilized for the procedure.

## **Step 2: Preparation**

To minimize the anxiety and pain experienced by this four-year-old boy, apply a topical anesthetic to the area where the needle is to be inserted. Also, providing an intranasal analgesic such as ketamine or fentanyl may help the child tolerate the procedure.

For more on topical anesthetics and intranasal medications in pediatric pain management, go to [Chapter 3 on Pain Management](#) or [Chapter 5 on Procedural Sedation](#).

**Q: Now that you've prepared for the procedure, it's time to identify the nerves you'd like to block. How do you identify the radial, ulnar, and median nerves?**

### **A: Step 3: Nerve identification**

Peripheral nerves have a "honeycomb" appearance, round or elliptical, with *hypoechoic* fascicles in a *hyperechoic* homogenous background. Using the high-frequency linear probe placed in the transverse plane at the level of the wrist, identify either the radial or ulnar artery. Then move proximally up the arm to locate the nerve.





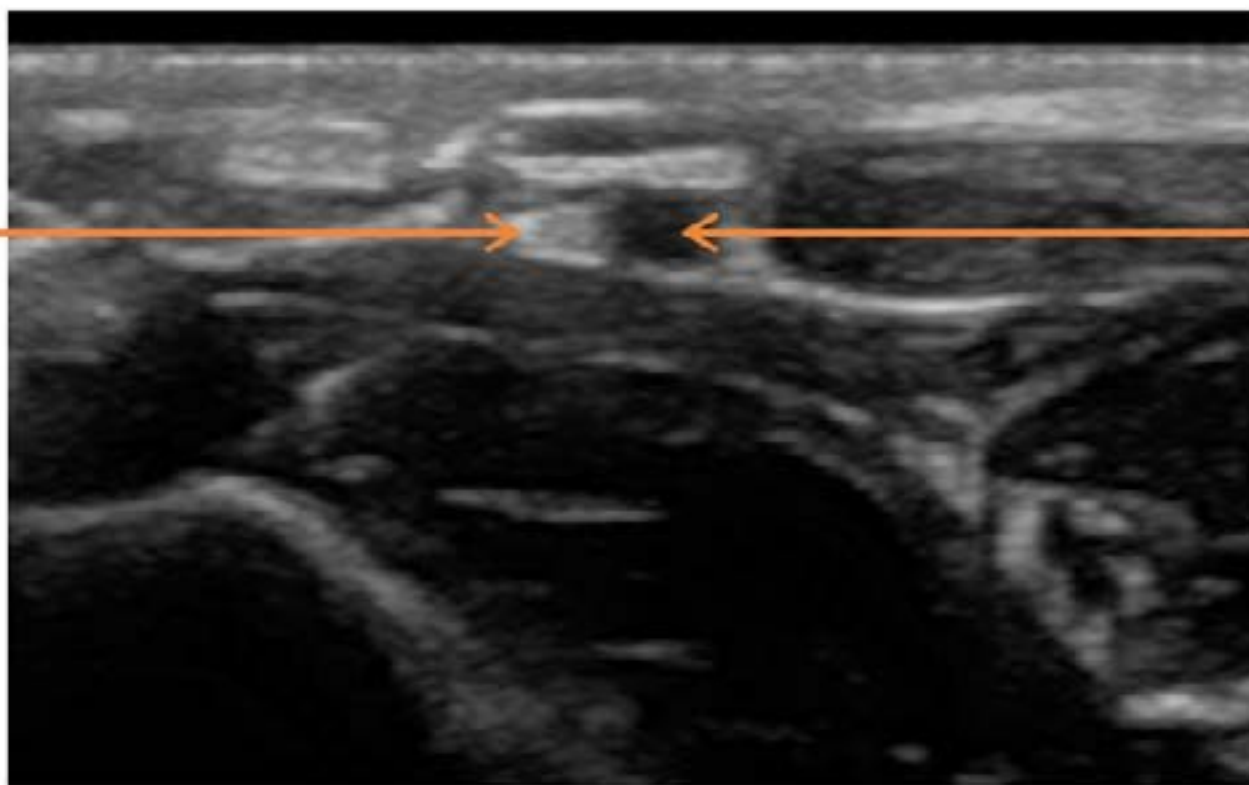
**AH-HA** The radial nerve will lie “radial” to the radial artery.

Radial  
nerve

Radial  
artery

Radial  
side

Ulnar  
side



Radial Nerve



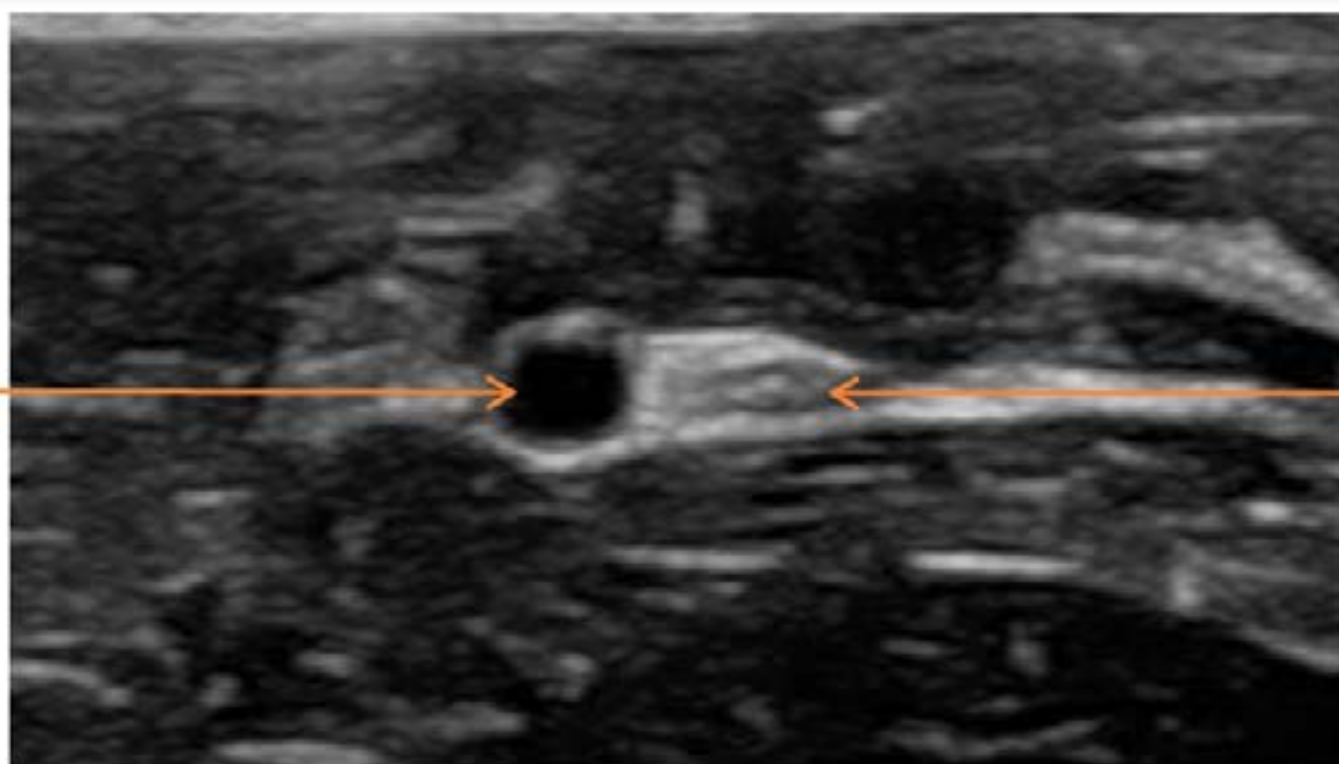
**AH-HA** The ulnar nerve will lie “ulnar” to the ulnar artery.

Ulnar  
artery

Ulnar  
nerve

Radial  
side

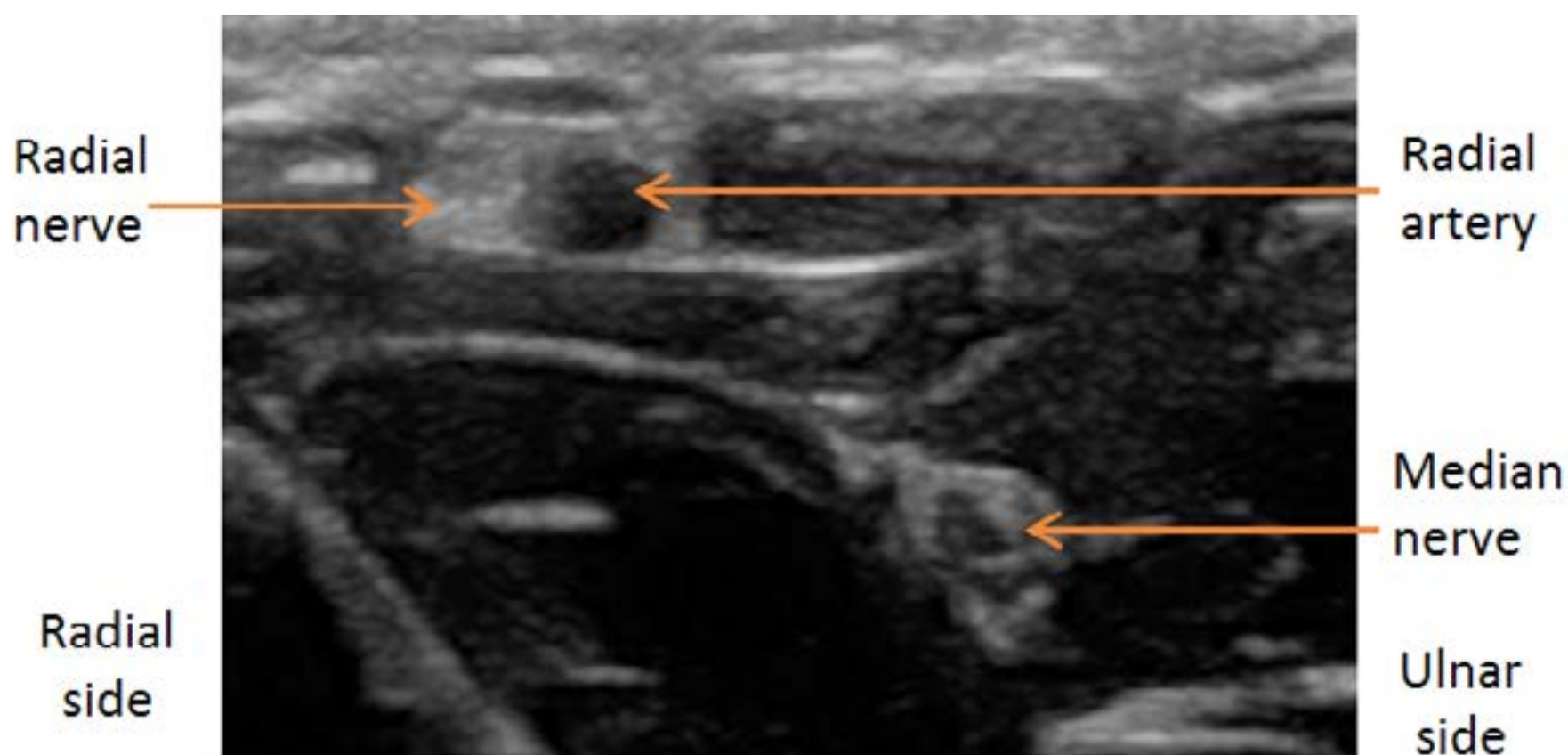
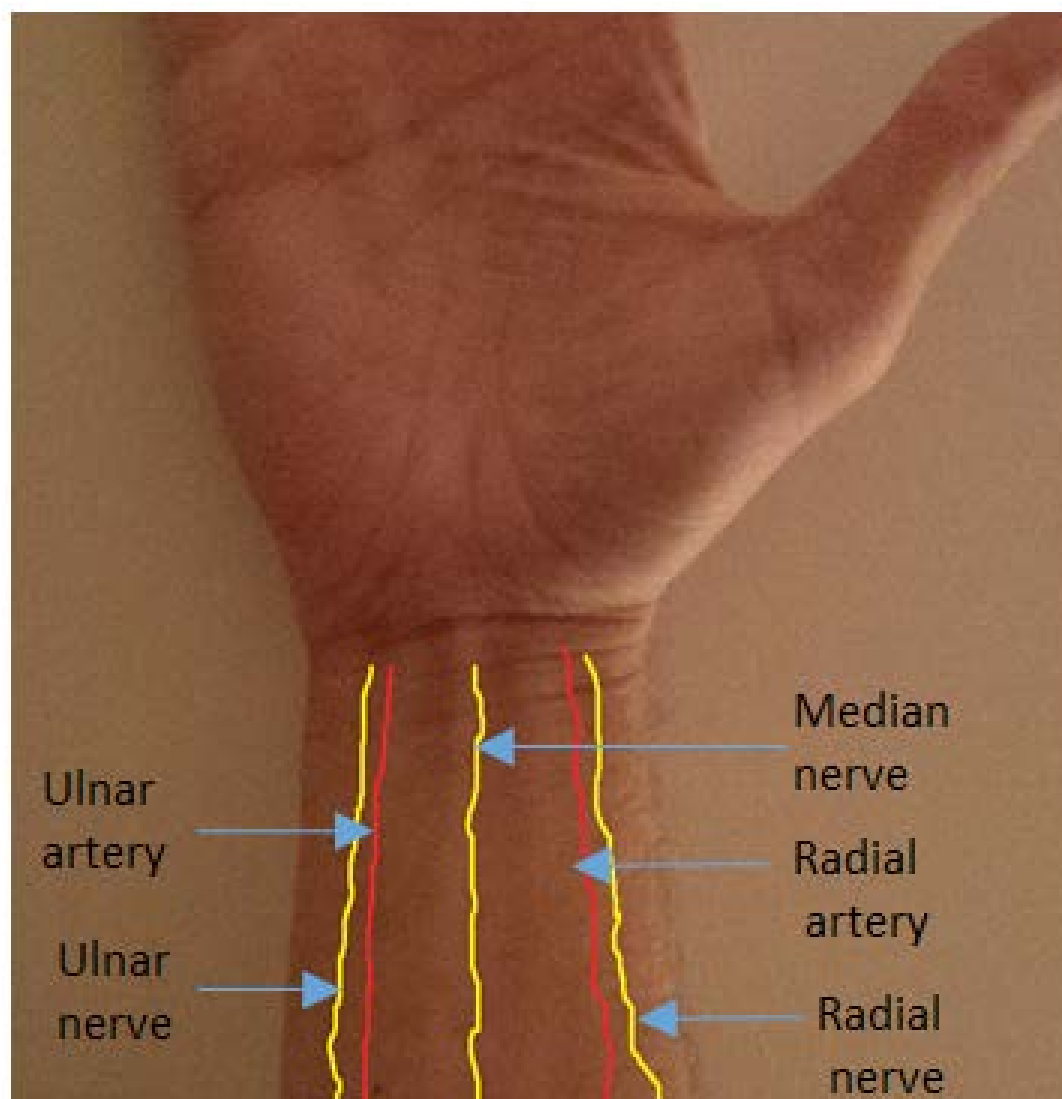
Ulnar  
side



Ulnar nerve



The median nerve does not have an associated artery, but is located in the mid-forearm (between the radial and ulnar nerve) in the flexor digitorum muscle bundles.



Median and Radial Nerve



## FOAMed Resource and Videos

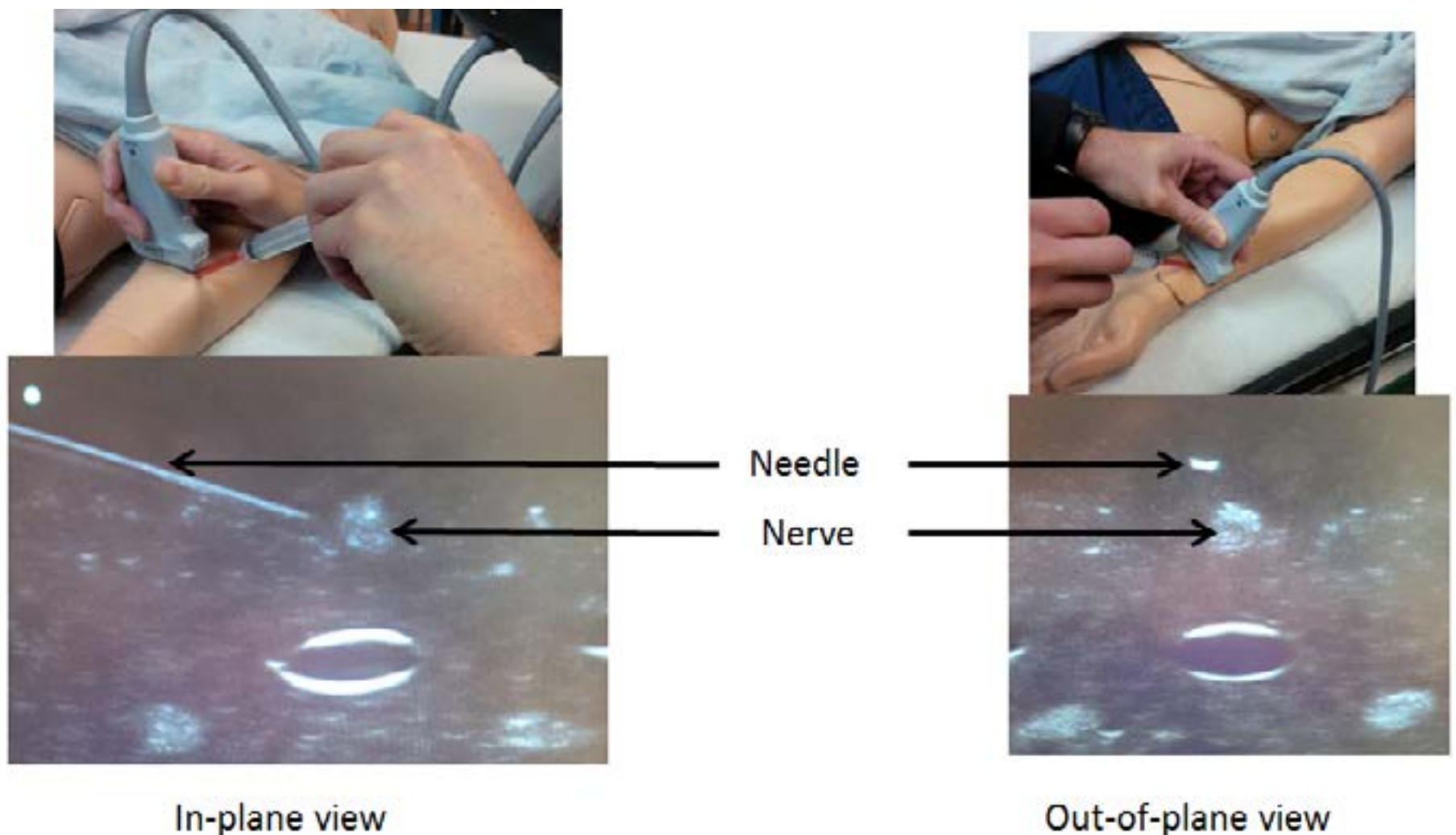
For more FOAMed resources and video instruction on how to identify the forearm nerves with POCUS, please visit:

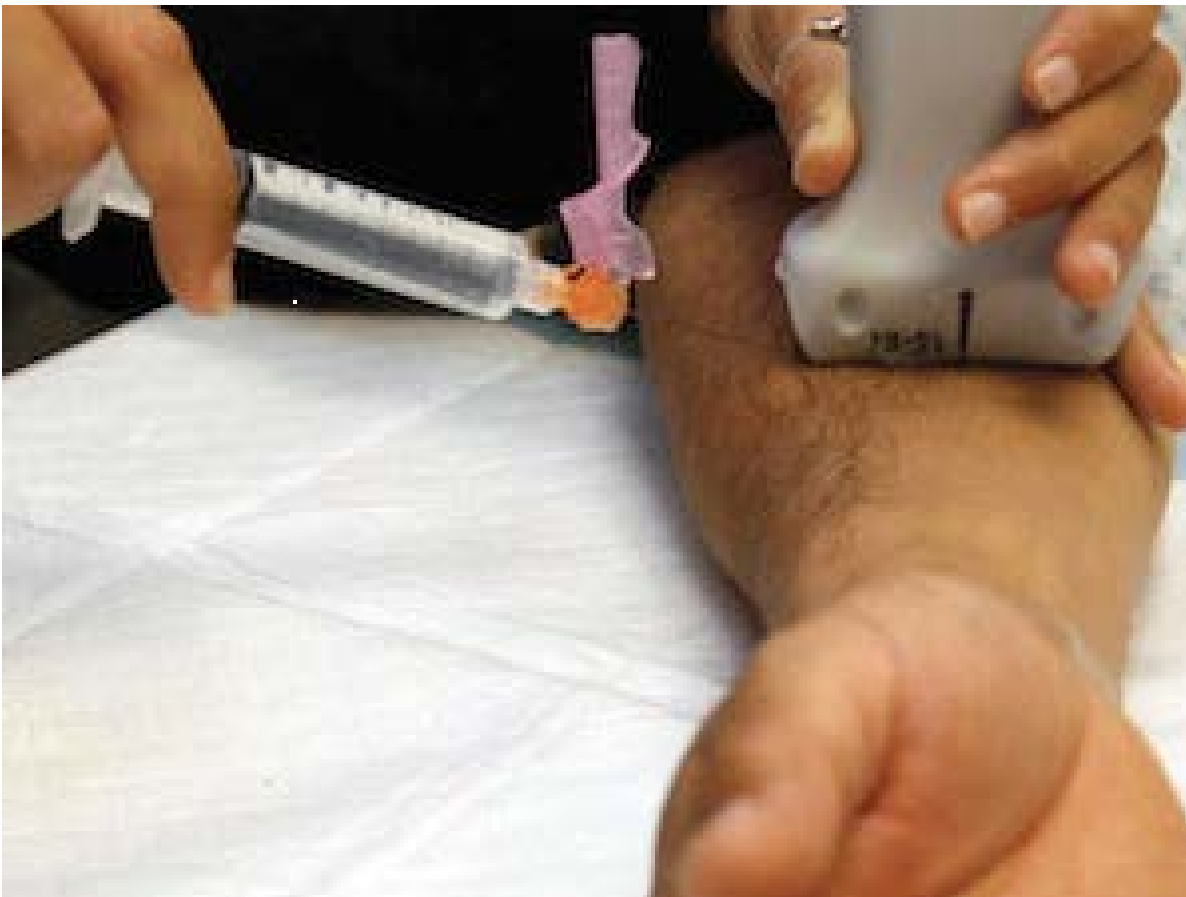- [\*How to identify the radial nerve - video by Dr. Mike Stone\*](#)
- [\*How to identify the ulnar nerve - video by Dr. Mike Stone\*](#)
- [\*How to identify the median nerve - video by Dr. Mike Stone\*](#)

### Step 4: Anesthesia delivery

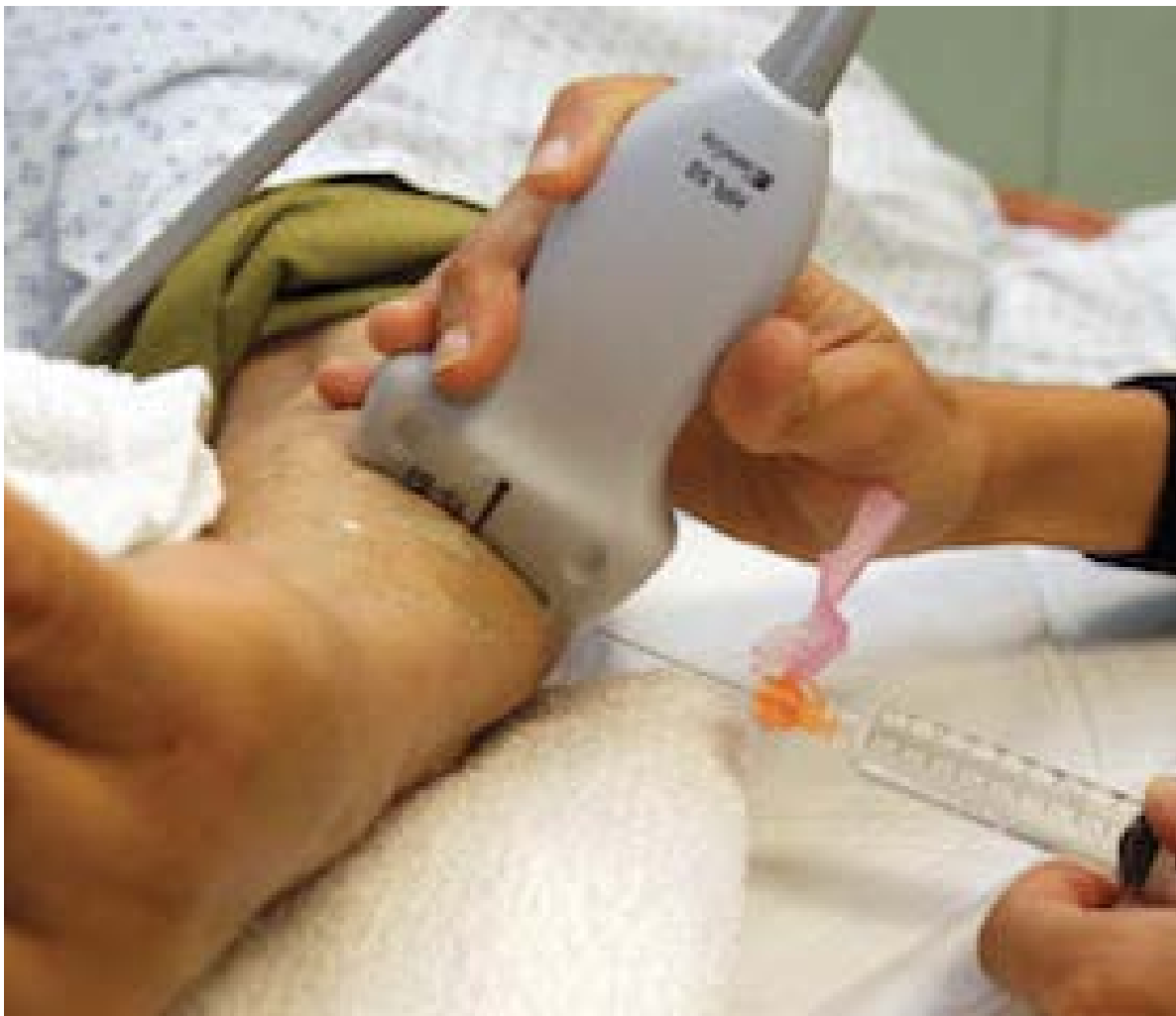**Q: It's time to inject the anesthetic. Which "plane" is used when performing a forearm nerve block to best identify the needle tip?**

**A:** Advance the needle tip "in-plane" toward the target nerve. This provides superior visualization of both the nerve and the needle over the "out-of-plane" view (see image).





Radial nerve



Ulnar nerve



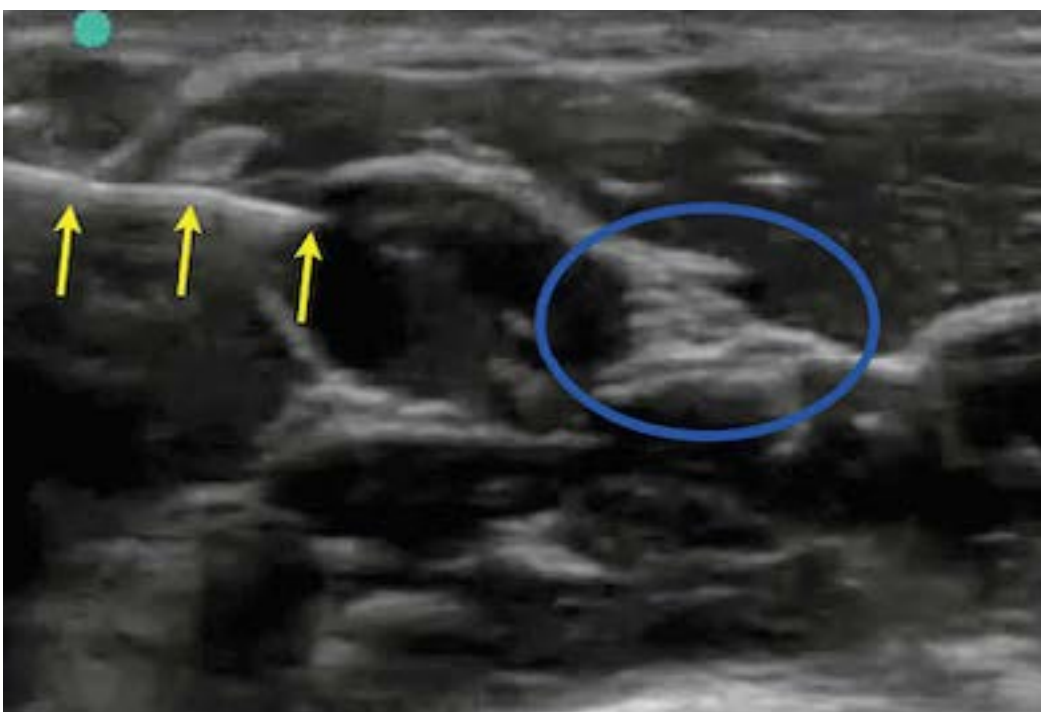
**Clinical Pearl:**

Buffer your lidocaine with bicarbonate to make injecting the lidocaine less painful.



**Q: How is the anesthetic delivered to ensure that the nerve will be bathed in anesthetic without injuring the nerve, and what should the ultrasound screen look like after delivery of the anesthetic?**

**A:** When the needle tip is adjacent to the nerve (but not in the nerve), inject the anesthetic so it surrounds the nerve circumferentially. If the nerve is bathed circumferentially with anesthetic (an anechoic area completely surrounding the nerve), clinically the patient should feel fully anesthetised in that nerve distribution. Multiple redirections of the needle may be necessary to bathe the nerve adequately. Visualization of the needle tip should be continuous throughout the procedure to avoid accidental puncture of vascular structures.



Lidocaine (blue arrow pointing at black area) from the needle (yellow arrows) accumulating around the nerve (blue circle)



**Caution:**

Ensure you have performed a full neurological exam of the child's distal extremity before you perform a nerve block, and document it for your colleagues who may take over care. Once the anesthetic has been administered, the neurologic exam will be compromised (loss of ability to check two-point discrimination). Also ensure that compartment syndrome has been ruled out before performing the nerve block.



Lidocaine is a safer drug for nerve blocks than bupivacaine, and adding epinephrine to the lidocaine will provide a prolonged analgesic effect compared with lidocaine alone.



### **Caution:**

#### **Toxic dose of lidocaine:**

- 5 mg/kg with epinephrine
- 3 mg/kg without epinephrine

**Q: In this case, the four-year-old boy is moving his arm a bit and you lose visualization of the needle on the screen. What are the best ways to troubleshoot this?**

**A:** Complications arise from losing the needle tip (damaging other structures, hitting vessels, going through a nerve). Try to visualize the needle tip on screen at all times before advancing it and always withdraw the plunger on the syringe to confirm that the needle is not inside a vessel before injecting the local anesthetic. If you lose your needle tip, don't panic. Move only one component at a time to re-identify your needle. You can either hold the ultrasound probe still while re-direct your needle back into view by moving it more "in-plane" with the probe, or you can hold your needle still and slowly move your ultrasound probe to visualize your needle on the screen.

**Case resolution:** Immediately after you block the radial, ulnar and median nerves of this four-year-old boy, he rates his pain on the Faces Pain Scale-Revised as 0 out of 5. Three hours later, as he is rolled into the operating room, he is smiling and chatting with the surgeon without any signs of pain.



### **Comments?**

[Click here to leave a comment or to listen to this podcast.](#)

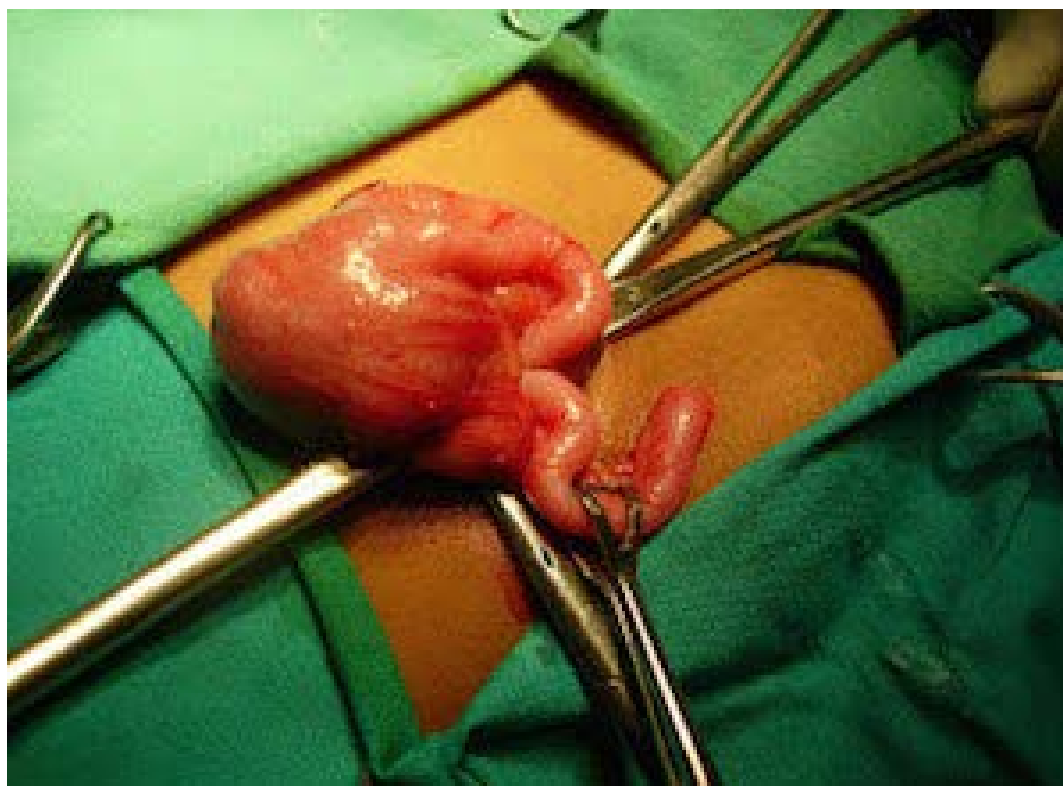


## KEY REFERENCES:

1. Frenkel O, Mansour K, Fischer JW. Ultrasound-guided femoral nerve block for pain control in an infant with a femur fracture due to non-accidental trauma. *Pediatr Emerg Care*. 2012; Feb;28(2):183-4.
2. Liebmann O, Price D, Mills C, et al. Feasibility of forearm ultrasonography-guided nerve blocks on the radial, ulnar, and median nerves for hand procedures in the emergency department. *Ann Emerg Med*. 2006; Nov;4(5):558-562.
3. Herring AA, Stone MB, Fischer J, et al. Ultrasound-guided distal popliteal sciatic nerve block for ED anesthesia. *Am J Emerg Med*. 2011; Jul;29(6): 697.
4. Ganesh A, Gurnaney HG. Ultrasound guidance for pediatric peripheral nerve blockade. *Anesthesiol Clin*. 2009; Jun;27(2):197-212.
5. Ivani G, Mosseti V. Pediatric regional anesthesia. *Minerva Anesthesiol*. 2009; Oct;75(10):577-583.
6. Tsui BC, Suresh S. Ultrasound imaging for regional anesthesia in infants, children, and adolescents: a review of current literature and its application in the practice of extremity and trunk blocks. *Anesthesiology*. 2010; Feb;112(2):473-492.

# CHAPTER 8: ABDOMINAL PAIN & APPENDICITIS

[LISTEN TO THE PODCAST WITH ANNA JARVIS & STEPHEN FREEDMAN HERE](#)



## Objectives

1. Develop an approach to assessing acute abdominal pain in the pediatric patient
2. Recognize the common pitfalls in accurately diagnosing appendicitis among pediatric patients
3. Understand the role of laboratory investigations in assessing a pediatric patient with acute abdominal pain
4. Develop an approach to the selection of imaging investigations for the pediatric patient suspected of appendicitis
5. Understand how to interpret equivocal ultrasound results
6. Describe effective ways to provide analgesia for pediatric patients
7. Review the management of appendicitis in the ED

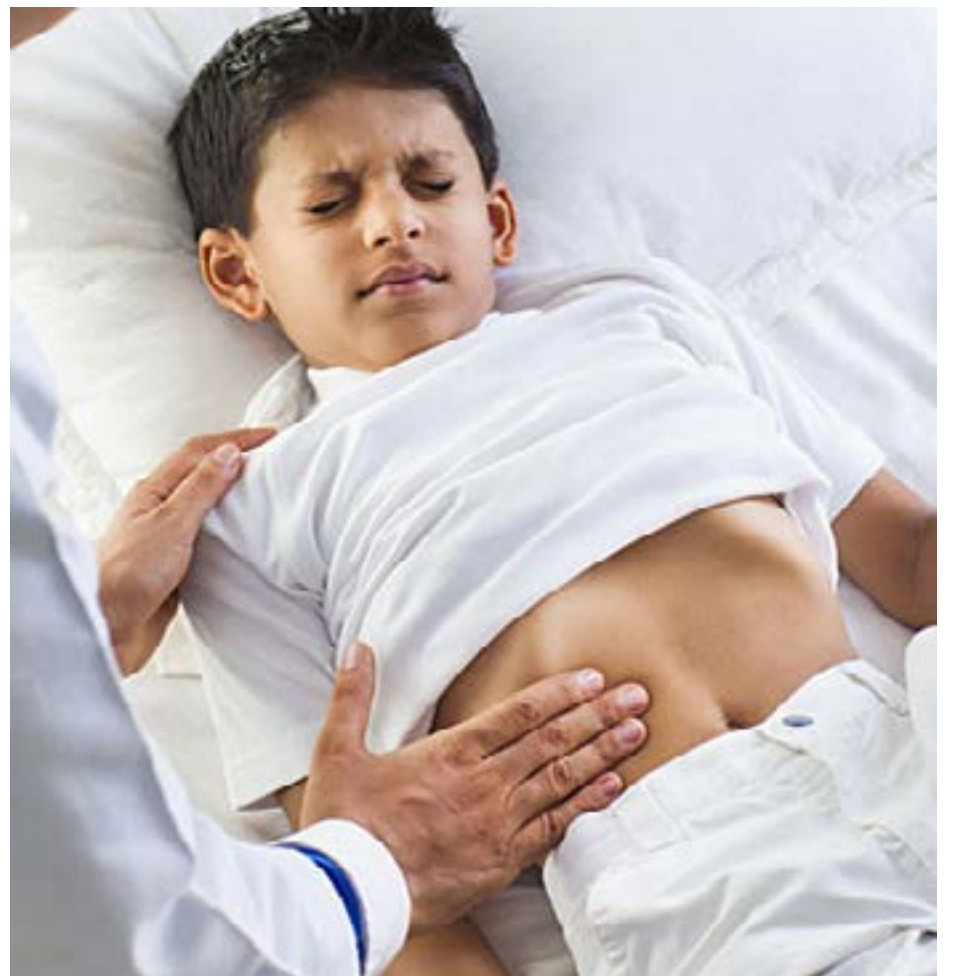
## CASE 1: APPROACH TO PEDIATRIC ABDOMINAL PAIN

A seven-year-old boy presents to your ED at 9 p.m. with a history of diarrhea and fever for two days, as well as vague abdominal pain. On further questioning, he has no travel history, his immunizations are up to date, there are no known viral contacts, and he is otherwise healthy on no medications. He vomited once that morning, has no urinary symptoms, no URI symptoms, and no rash. On exam, his vital signs are normal except for a temperature of 38.1°C. His abdomen is soft, with slight diffuse tenderness, and no peritoneal signs. The rest of his exam is normal.

**Q: You begin by considering your differential diagnosis. What are the most common diagnoses for pediatric abdominal pain in the ED?**

**A:** In order of prevalence, the most common diagnoses for pediatric abdominal pain are:

1. Gastroenteritis
2. Respiratory tract infection (including otitis media, pharyngitis, and pneumonia)
3. UTI
4. Constipation
5. Appendicitis



### **Caution:**

Only 1-2% of kids who present with abdominal pain will have a surgical diagnosis, yet these conditions can lead to significant morbidity and mortality if they are not diagnosed and managed appropriately in the ED. Children with a so-called “classic” gastroenteritis presentation may actually end up having a perforated appendicitis, while those with significantly tender bellies may have pneumonia, strep throat, or DKA.

**Case continued:** A urine dip is normal. A stool for culture and sensitivity is sent off, the boy is rehydrated with an oral rehydration solution in the ED, and a diagnosis of gastroenteritis is made. The patient is sent home with the usual gastroenteritis instructions.

**Q: How accurate are ED physicians at making the diagnosis of appendicitis?**

**A:** Despite being the most common surgical diagnosis for pediatric abdominal pain, appendicitis remains a very difficult diagnosis to make in the ED, with a misdiagnosis rate between 28% and 57% on the initial visit.

**Q: How does the rate of perforation of the appendix change with age?**

**A:** Delays in diagnosis are reflected in the high rate of perforation among pediatric patients with appendicitis. About one-third of children will have a perforated appendix discovered in the operating room. The rate of perforation is even higher among children younger than three years old, reaching as high as 80%–100%. These delays to diagnosis are associated with increased risk of intra-abdominal abscess formation, small bowel obstruction, and prolonged hospitalization.

**Q: Why are we not terribly accurate in diagnosing appendicitis in children clinically?**

**A:** The challenges in diagnosis are attributed largely to the frequent absence of the classic history of anorexia and vague periumbilical pain followed by migration to the right lower quadrant, low grade fever, and vomiting. An atypical presentation is very typical for pediatric appendicitis, with fewer than 60% of patients presenting with a “classic history.”

Anatomic position of the appendix can alter the presenting symptoms. Patients with a retrocecal appendix can present with pain localized to the psoas muscle or back rather than RLQ.



**Clinical Pearl:**

The younger the patient, the more wary a clinician should be of an atypical presentation.

The more atypical the presentation, the more likely the diagnosis will be missed on the initial visit. Add to this that the presence of features suggestive of alternative diagnoses—such as mild poorly localized pain, diarrhea, constipation, dysuria, upper respiratory symptoms, absence of fever, and a good appetite—and it is easy to understand how a physician could be led astray.

**Q: Since many children under the age of two years will present with a ruptured appendix, what signs and symptoms should you look for to assess for a ruptured or perforated appendix?**

**A:** Patients with a perforated appendix will often report an interval of pain relief prior to developing severe generalized pain, peritonitis, and a high temperature ( $> 39^{\circ}\text{C}$ ). Inflammatory markers such as a CRP or ESR are also more likely to be elevated.

**Q: The next day, the boy returns with worsening abdominal pain, persistent vomiting, and an elevated temperature of  $39.8^{\circ}\text{C}$ . You re-examine the child. What should you pay close attention to on physical exam?**

**A:** It is important to recognize that extra-abdominal etiologies can present as abdominal pain in children, and to examine the patient accordingly. In addition to examining the abdomen, the physician should also examine the patient's ears, pharynx, skin, back, lungs, and external genitalia. An internal gynecologic exam should be performed in the appropriate context, such as adolescent patients who are sexually active.



**Clinical Pearl:**

Contrary to adult appendicitis, vomiting may occur before the onset of abdominal pain in children.



**Caution:**

Parents also often present to the ED very early in the course of the illness when the signs and symptoms have not fully declared themselves.



**Clinical Pearl:**

With a delayed onset of diarrhea following two or more days of abdominal pain, think ruptured appendicitis!



Before palpating the abdomen, observe the child's behaviour and preferred position. Patients with appendicitis often prefer to lie still with their hips flexed. Restless movements are more suggestive of intussusception. You can also ask the child to cough, jump, or sit up in bed to elicit peritoneal tenderness, although these have poor predictive value. Proceed next with percussion to localize tenderness and detect peritonitis while minimizing discomfort, and then finally with palpation.



### **Caution:**

Always perform a testicular exam on male pediatric patients with abdominal pain. Testicular torsion can present with abdominal pain and vomiting.



### **Clinical Pearl:**

Consider ovarian torsion in adolescent females with sudden, near-simultaneous onset of RLQ pain and vomiting.



## **Physical Examination Strategies**

### **Ways to calmly facilitate an abdominal exam on a crying or frightened child:**

- Place your hand on top of the child's hand when palpating
- Use a stethoscope to palpate to distract the child by saying you are listening to their tummy
- Start by palpating the parent's or a stuffed animal's abdomen to demonstrate the benign nature of the exam
- Have the parent hold the child facing them, with the child's head resting on the parent's shoulder; then palpate the abdomen by wrapping your hands around the child's waist from behind
- Ask the parent to palpate the abdomen
- Have the parent bounce the child on their knee to elicit peritoneal signs
- Have the parent lie with the child on the stretcher to help the child feel safe and secure during the exam
- Start at the ankles palpating up to the abdomen. You can also lift and roll the legs to elicit psoas irritation



**Q: Next, you begin to consider whether you need to poke this child for blood work. What is the value of obtaining a complete blood cell (CBC) count on pediatric patients with abdominal pain?**

**A:** No laboratory marker can be used in isolation to definitively rule in or rule out appendicitis.

A CBC count, and in particular a WBC count, is of limited utility in diagnosing the cause of pediatric abdominal pain. The likelihood ratios (LR) associated with the presence or absence of leukocytosis are not sufficient to either rule in or rule out appendicitis. Children with gastroenteritis may have a high white count with a left shift, while as many as 40% of those with appendicitis may have no leukocytosis. Nonetheless, a normal WBC count does make the diagnosis less likely.



### **Key Reference:**

In a study of 755 kids, the absence of leukocytosis was of greater negative predictive value than the absence of physical exam findings and symptoms. A WBC count of  $<10,000$  (LR 0.18) and absolute neutrophil count (ANC) of  $< 7,500$  per cubic millimetre (LR 0.35) had lower likelihood ratios for appendicitis than a lack of percussive tenderness (LR, 0.50), lack of guarding (LR 0.63), or absence of nausea or emesis (LR 0.65).



### **AH-HA**

The earlier the presentation, the less likely the WBC count will be elevated. The WBC count is normal in first 24 hours in 80% of appendicitis cases.

**Q: Is there a role for adding inflammatory markers to the blood work to help diagnose appendicitis?**

**A:** The role for both the erythrocyte sedimentation rate (ESR) and CRP in diagnosing appendicitis among pediatric patients remains unclear at present. Similar to a WBC count, both ESR and CRP lack the necessary sensitivity or specificity to rule in or rule out a diagnosis of appendicitis in isolation, especially among patients presenting within in the first 24 hours of symptom onset. In addition, the variable cut-off values for the CRP make it difficult to compare its performance across studies and determine how it should be used.

Some literature suggests the sensitivity of CRP does improve, and potentially exceeds that of a WBC count 24 hours after the onset of symptoms. Other studies have suggested CRP is best interpreted as a marker of disease severity, with improved accuracy in detecting gangrenous or perforated appendicitis.

Interestingly, a single study demonstrated a near 90% specificity for appendicitis when both the WBC count and CRP are elevated.

**Q: You decide to order a CBC and a CRP given the child's clinical course. Will you also include a urinalysis in your standard workup for the child presenting with still undifferentiated abdominal pain?**

**A:** A urinalysis is critical in screening for alternative diagnoses when working up a child with abdominal pain. However, it is important to be mindful that a positive urinalysis can occur with appendicitis.

Pyuria found on urinalysis is routinely used as an indicator of an underlying urinary tract infection. However, it is often present in appendicitis due to local irritation from an inflamed appendix on either the ureter or bladder. As a result, the presence of pyuria can be difficult to interpret when both a UTI and appendicitis are included in a clinician's differential diagnoses. The presence of 20 or more WBCs per high-power field (hpf) or bacteria on a clean catch specimen favours a urinary tract infection.



**Caution:**

Pyuria and hematuria are findings that can be consistent with the diagnosis of appendicitis. Don't let the findings of pyuria or hematuria dissuade you from diagnosing appendicitis in a child whom you suspect has appendicitis clinically.

A human chorionic gonadotropin urine test to screen for pregnancy among sexually active adolescent patients is an important consideration in undifferentiated abdominal pain. DKA can present with abdominal pain and vomiting. A urinalysis is also valuable to evaluate for ketosis and hyperglycemia.

For more on pediatric DKA, [jump to Chapter 11](#).

**Q: You have heard about multiple clinical decision rules for pediatric appendicitis. How should you incorporate these into clinical practice?**

**A:** There are three published decision rules for pediatric appendicitis: the Refined Low-Risk Appendicitis Score, the Pediatric Appendicitis Score, and the Alvarado Score.

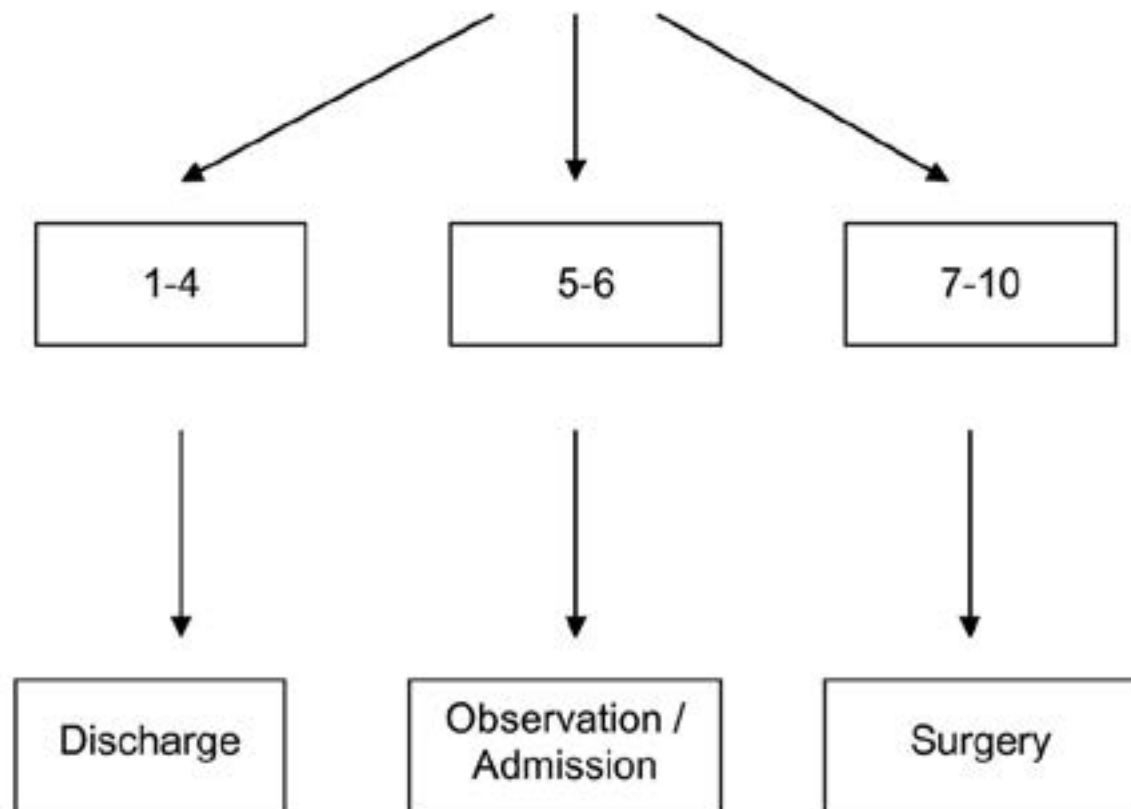
Each of these scores has varying sensitivities (65%–98%) and specificities (32%–92%) and are rarely used as definitive confirmation of the diagnosis, but knowing what is listed in them is useful for teaching purposes and as pieces of the puzzle to help weigh our decisions.



## The Alvarado Score for Predicting Acute Appendicitis

[Click here for details of a systematic review of the Alvarado Score.](#)

Alvarado score	
Feature	Score
Migration of pain	1
Anorexia	1
Nausea	1
Tenderness in right lower quadrant	2
Rebound pain	1
Elevated temperature	1
Leucocytosis	2
Shift of white blood cell count to the left	1
<b>Total</b>	<b>10</b>



Predicted number of patients with appendicitis:

- Alvarado score 1-4 - 30%
- Alvarado score 5-6 - 66%
- Alvarado score 7-10 - 93%



## PAS Score Components

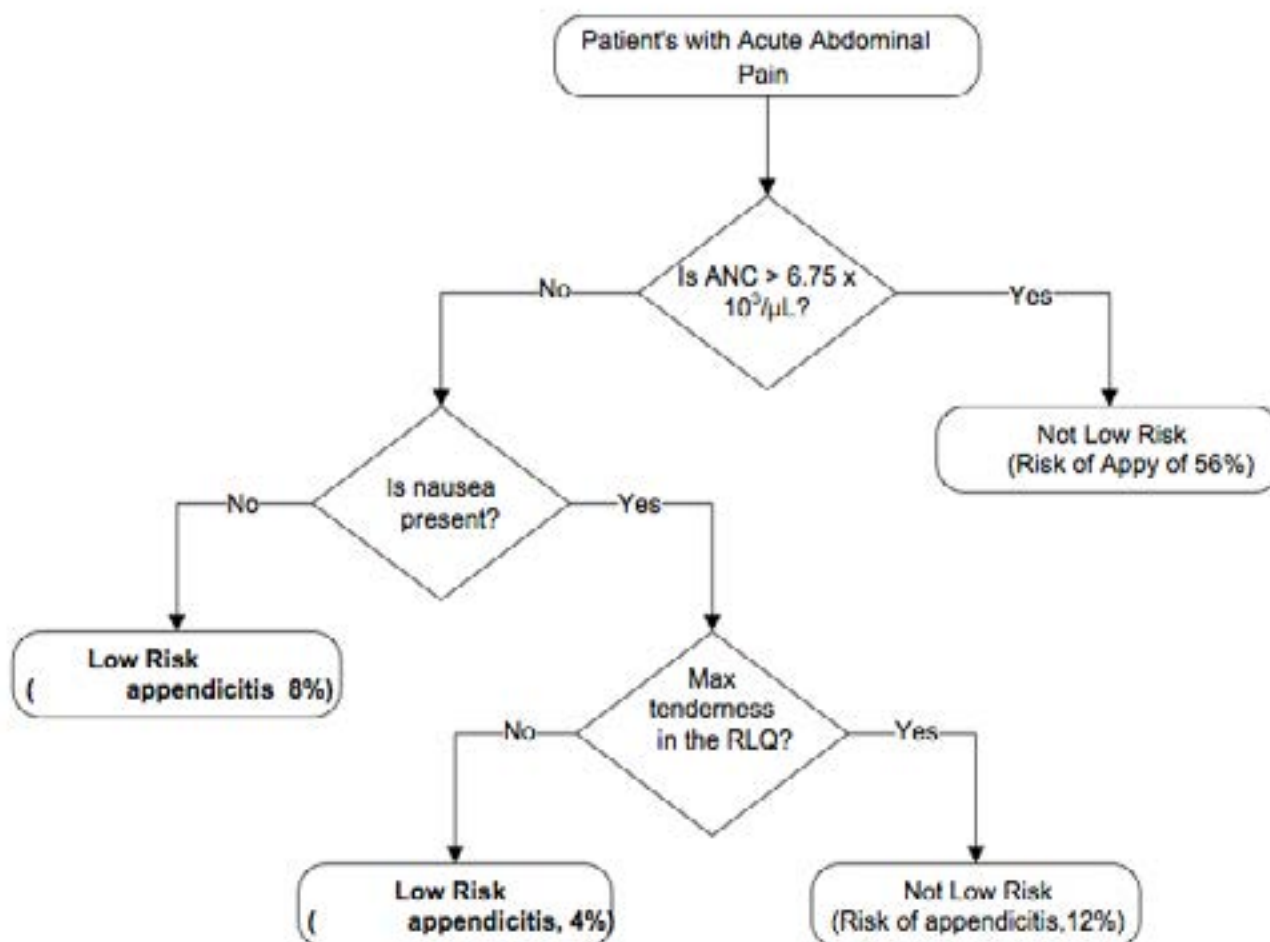
Feature	Point Value
Migration of Pain	1
Anorexia	1
Nausea/vomiting	1
RLQ tenderness	2
Coughing/hopping/percussion pain	2
Fever	1
Leukocytosis	1
Left shift on WBC differential	1

≥ 6 = Appendicitis

≤ 5 = Observe

Samuel, J Pediatric Surgery, 2002; 37(6): 877-881

[Click here for details of the Pediatric Appendicitis Score and the Refined Low Risk Appendicitis Score.](#)





Clinician gestalt of an experienced ED physician may be as good as any of these scores, but if you are early in your emergency medicine career, any of these three clinical decision rules may help in your decision-making if the score is very low or very high.

**FOAMed Link:** [For more on appendicitis decision rules, visit emDocs here.](#)

**Case continued:** The results are returning on your patient and you summarize your findings. On examination, the patient seems to be in moderate discomfort, and prefers to lie still on the stretcher. Palpation of the abdomen reveals rebound tenderness in the RLQ. Laboratory testing is remarkable for an elevated WBC count of 14 and a normal urinalysis. You remain concerned that this child has appendicitis and order an ultrasound.

**Q: While awaiting imaging, what are some options for treating this patient's pain?**

**A:** The myth has long been dispelled that providing analgesia can mask physical exam findings leading to misdiagnosis in appendicitis.



### **Pediatric Pain Management**

Typical pediatric dosages for parental opioid analgesia:

- Morphine 0.05 to 0.1 mg/kg IV q2h up to 8 mg/dose
- Hydromorphone 0.02 mg/kg IV q2h
- Fentanyl 1 mcg/kg IV Q1-2h

For more on pediatric pain management, jump to Chapter 3: Pain Management.

**Q: Your ultrasound report comes back and you are reading through the radiologist's findings. What are the ultrasound diagnostic criteria for appendicitis?**

**A:** As a modality that does not expose patients to radiation, ultrasound is the preferred initial imaging for pediatric appendicitis, with a reported sensitivity and specificity between 88% (95% CI 86%–90%) and 94% (95% CI 92%–95%), respectively.

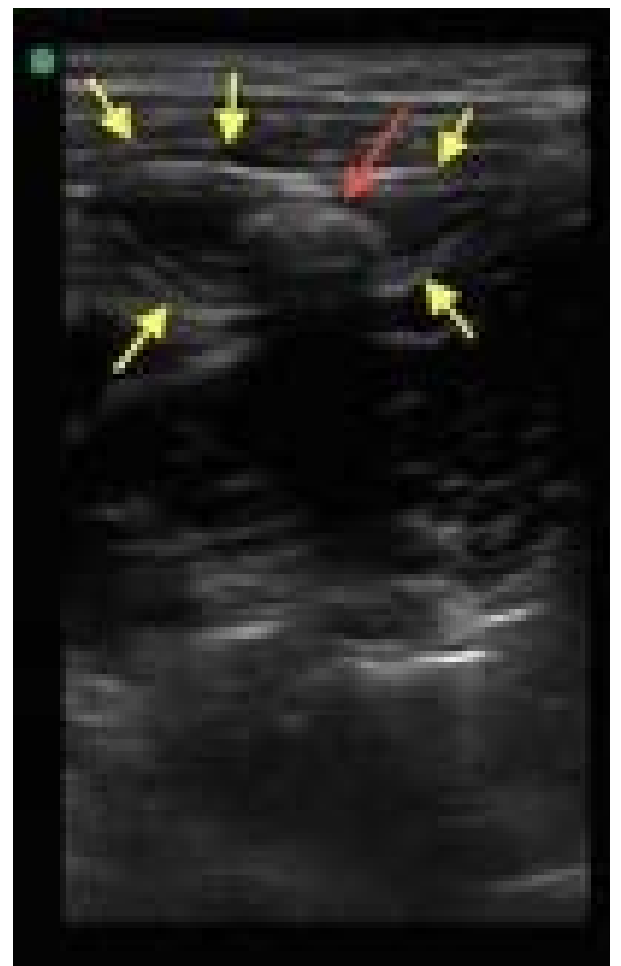
The following features of a directly visualized appendix support a diagnosis of appendicitis:

1. An aperistaltic, non-compressible, hyperemic, dilated appendix (> 6 mm)
2. Appendiceal wall thickening > 1.7 mm
3. Presence of an appendicolith

**Secondary signs** suggestive of appendicitis when you are unable to fully visualize the entire appendix include:

1. Periappendiceal free fluid
2. Enlarged mesenteric lymph nodes
3. Increased fat echogenicity
4. Fluid in the lumen of the appendix

For a the role of ED Point of Care Ultrasound in the diagnosis of pediatric appendicitis, jump to [Chapter 9](#).



**Q: How should a clinician interpret an ultrasound report that states the appendix could not be seen?**

**A:** The interpretation of an ultrasound report where the appendix is not seen will depend both on the pre-test probability from your clinical impression, initial laboratory investigations, and the presence or absence of secondary signs of appendicitis.

An ultrasound where the appendix is not seen can still provide valuable information. The absence of any secondary signs of appendicitis makes a final diagnosis of appendicitis very unlikely. One study found a 0.90 (95% CI 0.83-0.95) negative predictive value in the absence of secondary signs of appendicitis among ultrasound results where the appendix was not seen.

**Q: What should be the next step if you remain concerned that a patient may have appendicitis and the ultrasound was inconclusive?**

**A:** This is an area of great practice variability from centre to centre and between individual physicians.

In the context of high clinical suspicion, consultation with a pediatric surgeon or proceeding with a low-dose CT would typically be pursued. With a sensitivity of 92%–100%, and specificity of 89%–98%, CT has a high likelihood of being able to definitively rule in or rule out a diagnosis in a timely fashion.

In the event that the initial ultrasound is inconclusive for a well-appearing child with a low to moderate clinical pre-test probability, one approach is to have the child return to the ED in 12 to 24 hours to be reassessed and potentially repeat the ultrasound. This strategy avoids the radiation exposure of a CT, while capitalizing on the improved diagnostic accuracy of ultrasound examination with the increased duration of symptoms. A secondary analysis from a prospective trial on children with suspected appendicitis demonstrated that the sensitivity of ultrasound improved from 86% within the first 12 hours after the onset of symptoms to 96% after 48 hours.



**Clinical Pearl:**

While the accuracy of ultrasound for the diagnosis of appendicitis increases with time from onset of symptoms, the accuracy of CT does not change with time. It is therefore reasonable to repeat an abdominal ultrasound in 12 to 24 hours for patients with a low or moderate probability of appendicitis with an equivocal initial ultrasound, who present early after symptom onset.

**FOAMed link:** [For more on ultrasound versus CT for appendicitis, visit the Academic Life in EM blog.](#)

**Case continued:** On repeat ultrasound, a diagnosis of uncomplicated appendicitis it made.

**When you call the pediatric surgeon you are informed that they are in the operating room and should be down to see the patient in the next two hours. While waiting for the surgeon to arrive you decide to start antibiotics. What is the role for antibiotics in acute appendicitis? And which antibiotics should be used?**

**A:** In patients with non-perforated appendicitis, children should receive preoperative broad-spectrum antibiotics to decrease the incidence of wound infection and abscess formation; however, the antibiotics do not need to be administered in the ED.

Broad-spectrum single- or double-agent therapy is as effective as, and more cost-effective than, triple-agent therapy for the treatment of perforated appendicitis.



### **Comments?**

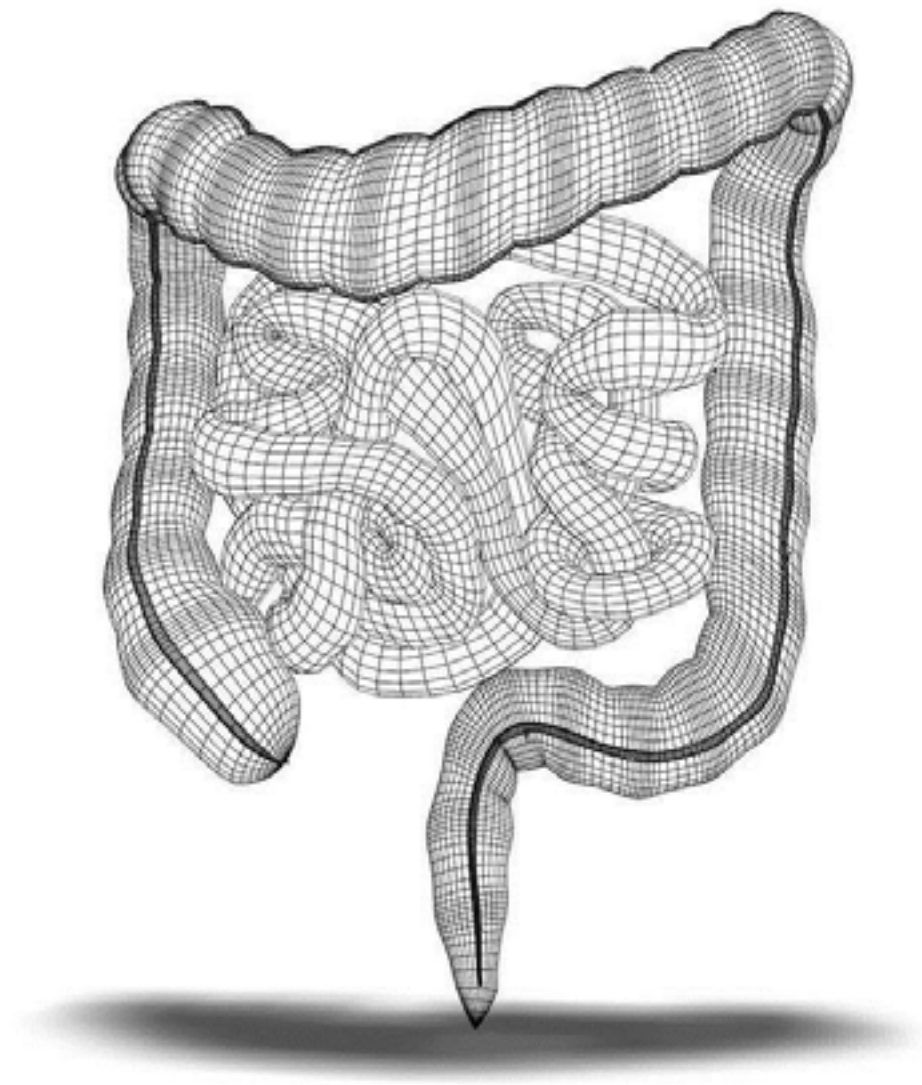
[Click here to leave a comment or to listen to this podcast.](#)

## KEY REFERENCES:

1. Becker T, Kharbanda A, Bachur R. Atypical clinical features of pediatric appendicitis. *Acad Emerg Med*. 2007; Feb;14(2):124-9.
2. Bundy DG, Byerley JS, Liles EA, Perrin EM, Katnelson J, Rice HE. Does this child have appendicitis? *JAMA*. 2007; Jul;298(4):438-51.
3. Kharbanda AB, Casme Y, Liu K, Spitalnik SL, Dayan PS. Discriminative accuracy of novel and traditional biomarkers in children with suspected appendicitis adjusted for duration of abdominal pain. *Acad Emerg Med*. 2011; Jun;18(6):567-74.
4. Kwan KY, Nager AL. Diagnosing pediatric appendicitis: usefulness of laboratory markers. *Am J Emerg Med*. 2010; Nov;28(9):1000-15.
5. Kharbanda AB, Dudley NC, Bujaj L, et al. Validation and refinement of a prediction rule to identify children at low risk for acute appendicitis. *Arch Pediatr Adolesc Med*. 2012; Aug;166(8):738-44.
6. Kulik DM, Uleryk EM, Maguire JL. Does this child have appendicitis? A systematic review of clinical prediction rules for children with acute abdominal pain. *J Clin Epidemiol*. 2013; Jan;66(1):95-104.
7. Goldman RD, Crum D, Bromberg R, Rogovik A, Langer JC. Analgesia administration for acute abdominal pain in the pediatric emergency department. *Pediatric Emerg Care*. 2006; Jan;22(1):18-21.
8. Estey A, Poonai N, Lim R. Appendix not seen: the predictive value of secondary inflammatory sonographic signs. *Pediatric Emerg Care*. 2013; Apr;29(4):435-9.
9. Bachur RG, Dayan PS, Bajaj L, et al. The effect of abdominal pain duration on the accuracy of diagnostic imaging for pediatric appendicitis. *Ann Emerg Med*. 2012; Nov;60(5):582-590.
10. Ohle R, O'Reilly F, O'Brien KK, et al. The Alvarado score for predicting acute appendicitis: a systematic review. *BMC Med*. 2011; Dec;9:139.
11. Doria AS, Moineddin R, Kellenberger CJ, et al. US or CT for diagnosis of appendicitis in children and adults? A meta-analysis. *Radiology*. 2006; Oct;241(1):81-94.
12. Lee SL, Islam S, Cassidy LD, et al. Antibiotics and appendicitis in the pediatric population: an American Pediatric Surgical Association Outcomes and Clinical Trials Committee Systematic Review. *J Pediatr Surg*. 2010; Nov;45(11):2181-2185.

# CHAPTER 9: POCUS APPENDICITIS & INTUSSUSCEPTION

[LISTEN TO THE PODCAST WITH ALEX ARROYO AND ADAM SIVITZ HERE](#)



## Objectives

1. Review the literature of POCUS in pediatric appendicitis
2. Learn the technique to perform appendicitis POCUS
3. Learn the technique to perform intussusception POCUS
4. Identify the target sign of intussusception



## CASE 1: THE BIG SAVE

A 12-year-old boy complains of peri-umbilical pain for the past 24 hours. He presents to a tertiary hospital with no pediatric capabilities. He has been refusing to eat food and is now able to tolerate sips of fluid. A junior learner has done an assessment and indicates the child is suffering from gastroenteritis, and wants to send the child home. On bedside ultrasound, a non-compressible, tubular structure is seen in the right lower quadrant with a diameter of 9 mm and peri-appendiceal fluid. The patient is transferred to a pediatric centre at 1 a.m., and its 24-hour ultrasound department confirms acute appendicitis. An uneventful appendectomy was performed at 6:30 a.m.

Appendicitis is notorious for its variability in clinical presentation, which can make it challenging to diagnose. Blindly taking a patient to surgery without any imaging can lead to a negative laparotomy, leading to complications. The current guidelines stipulate that ultrasound should be the first line imaging modality for suspected pediatric appendicitis. Ultrasound is a safe and useful tool to diagnose appendicitis, but unfortunately it is not available 24 hours a day in many centres. Appendicitis Point of Care Ultrasound (POCUS) may be an alternative in this case and save the patient radiation from a CT scan.

**Q: Will the surgeons believe me when I tell them I've confirmed appendicitis on POCUS? Can clinicians accurately diagnose appendicitis on POCUS?**

**A: Evaluation of acute appendicitis by pediatric emergency physician sonography**



In a study of 264 pediatric patients with suspected appendicitis, 13 pediatric emergency sonographers performed appendicitis POCUS.

Findings for appendicitis POCUS:

- 85/264 had appendicitis
- Sensitivity of 85% and specificity of 93% for appendicitis
- Positive LR of 11.7 and negative LR of 0.17 for appendicitis

**Author's conclusions:** Pediatric emergency physicians can diagnose acute appendicitis with substantial accuracy.



**AH-HA**

The sensitivities and specificities for the diagnosis of appendicitis on POCUS by emergency physicians are comparable to those found in the radiology literature.

**Q: The diagnosis and treatment of this 12-year-old boy with appendicitis was expedited using POCUS. What does the literature show about how appendicitis POCUS can improve ED length of stay and limit CT rates?**

**A:** In one study of 150 pediatric patients with suspected appendicitis, appendicitis POCUS significantly decreased ED length of stay (154 minutes versus 288 minutes). CT rates also decreased to 27% from 44%.

	POCUS	Radiology U/S	CT Scan
Sensitivity	60%	63%	83%
Specificity	94%	99%	98%

**Q: That makes sense, but in this case, the patient still went on to have a formal ultrasound. If emergency physicians can accurately diagnose appendicitis at the bedside, which patients require additional imaging after POCUS?**

**A:** First, a pre-test probability is required to determine the need for further testing. In a high-probability patient who has a negative appendicitis POCUS, more definitive imaging is required. Conversely, in a very low-probability patient who is otherwise well, a negative appendicitis POCUS that is determinate does not require further imaging. In the medium-probability patient (often the most diagnostically challenging), they may require further testing based on the clinical features and POCUS findings.



In the medium-probability patient for appendicitis, the safest course of action is to obtain additional tests if the appendicitis POCUS is not obviously positive. These patients are the most diagnostically challenging and may have other causes of their symptoms that need to be explored.



### **Pitfall:**

Be careful not to misidentify the terminal ileum or another component of the small bowel as the appendix by ensuring you are seeing a tubular, non-compressible structure.

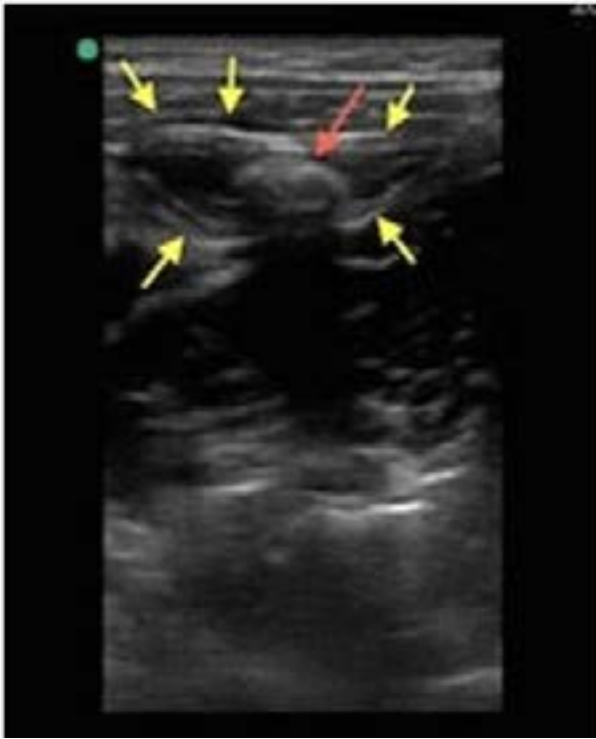**Q: Now that you have some data to support your appendicitis POCUS practice, let's move on to the practicalities of doing the procedure. How do you perform POCUS when you are suspicious of appendicitis?**

**A:** First, choose the high-frequency probe (the linear probe). Have the child point to the area of maximal tenderness, and place the high-frequency probe at that location. In a younger child who cannot express exactly where the pain is located, a more systematic scanning technique is required. Identify the ascending colon in the lateral right side of the abdomen and slide down the lateral wall to ensure findings of lateral or retro-cecal appendicitis are not missed. Slide the probe to the medial side of the cecum and ascending colon where the appendix most likely comes off the cecum. To correctly identify the appendix, ensure a tubular, non-compressible structure is seen.

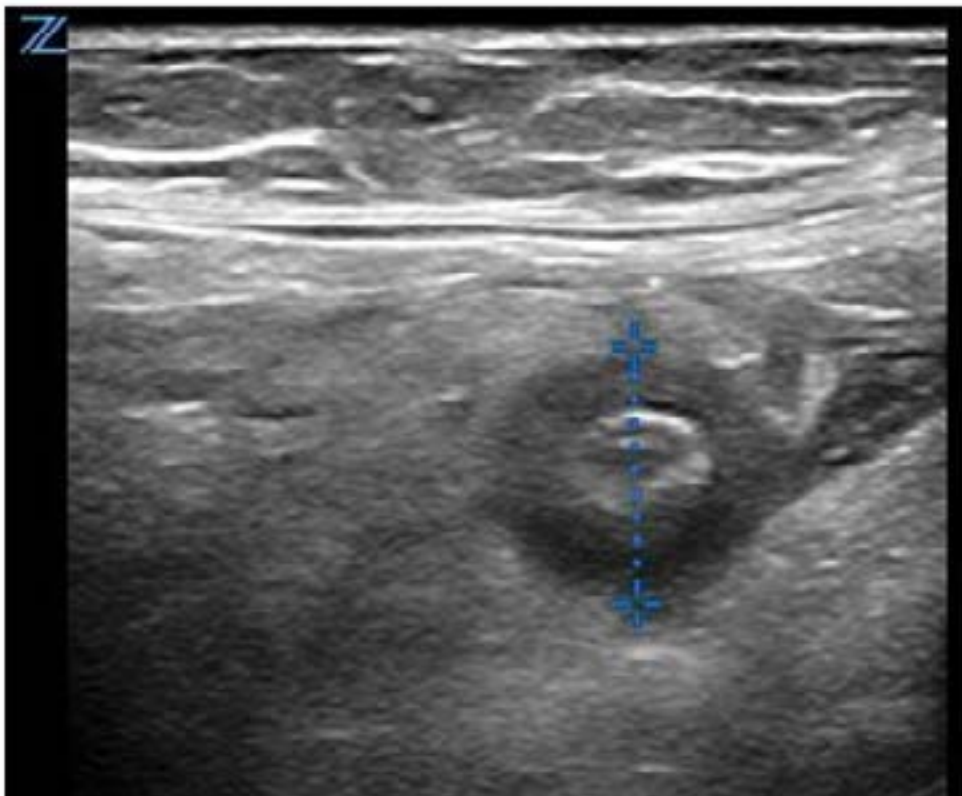
Once the appendix is located, trace the appendix all the way to its blind end by sliding the probe.

### **POCUS findings to support the diagnosis of appendicitis**

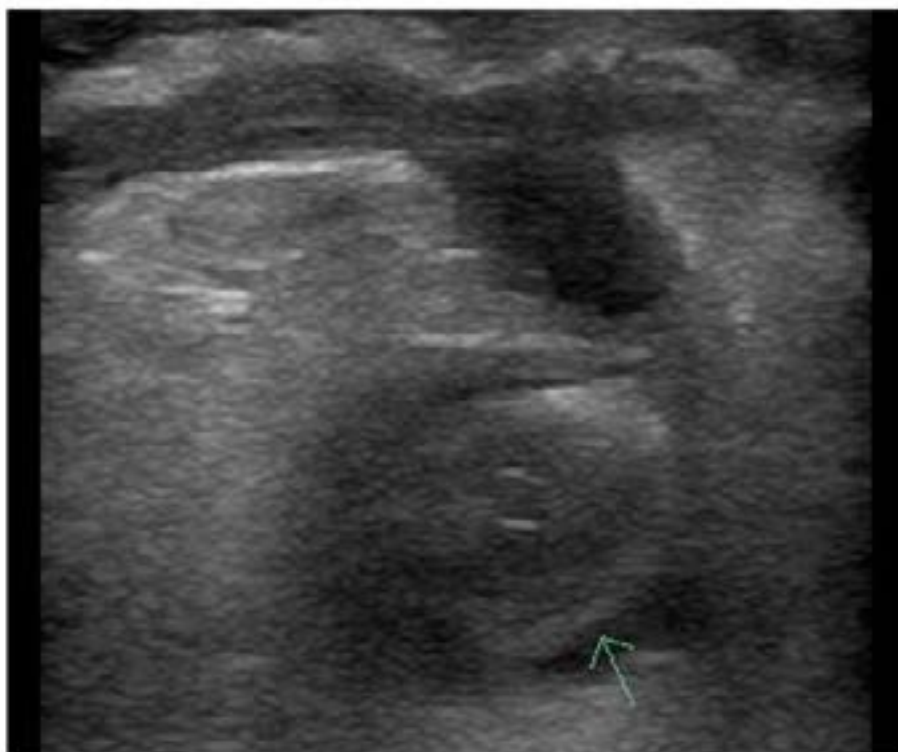
1. Dilated appendix (> 6 mm)
2. Appendicolith
3. Distinct appendiceal wall layers
4. Echogenic prominent peri-cecal fat
5. Peri-appendiceal fluid collection
6. Target appearance



Appendicitis (yellow arrow)  
with appendicolith (red arrow)

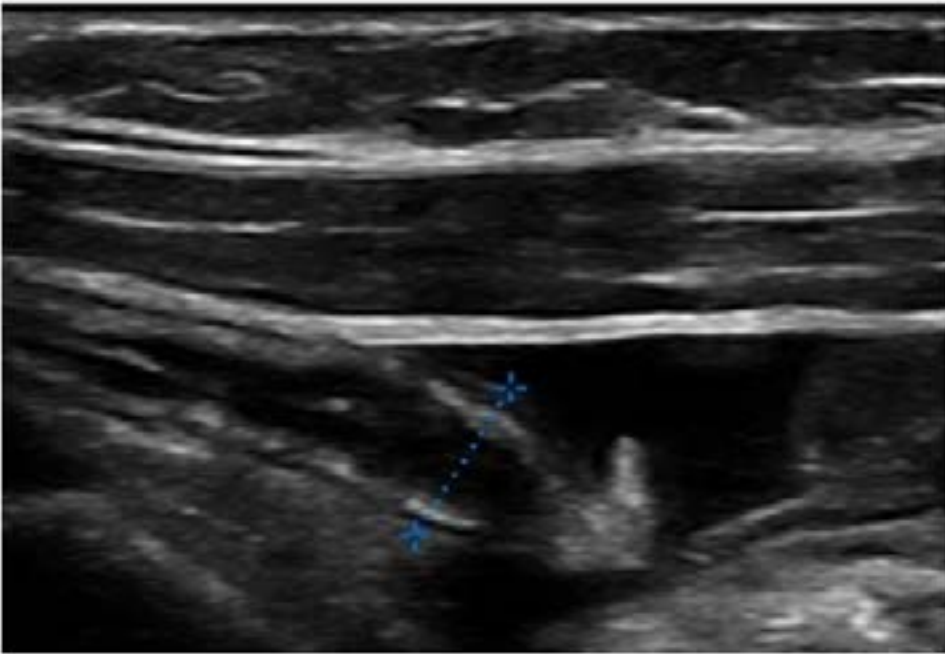


Appendicitis (with  
appendix in short axis  
measuring 10.4 mm)



Appendicitis with peri-  
appendiceal fluid  
collection (green arrow)





Appendicitis (with appendix in long axis measuring 6.8 mm) with its tip surrounded by peri-appendiceal fluid



### Step-by-Step Approach to Appendicitis POCUS

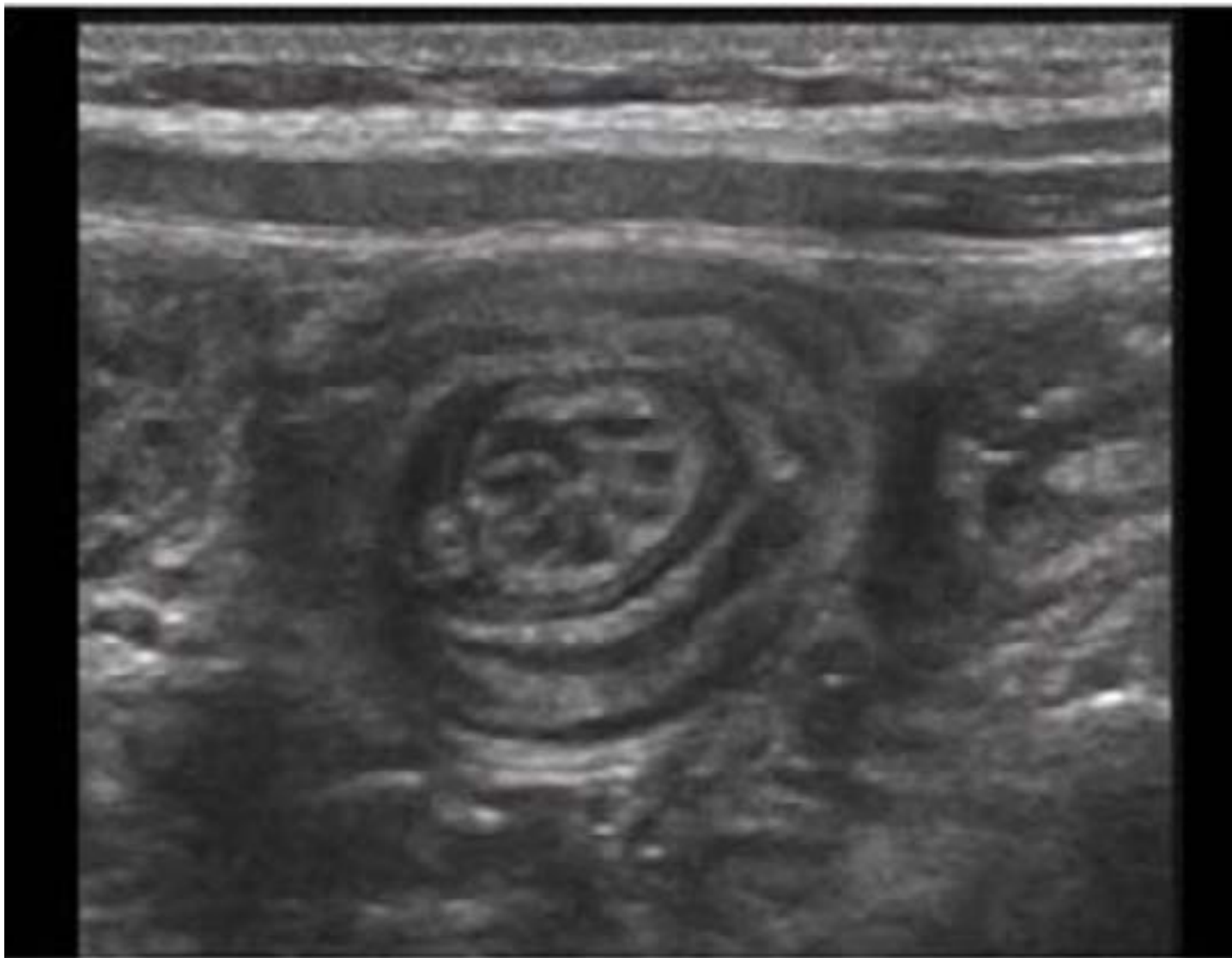1. In an older child who is able to point to the location of their pain, place the probe where they point. Younger patients require a more systematic scanning technique.
2. Identify the ascending colon in the lateral right side of the abdomen. Move down the lateral wall to make sure you are not missing a lateral or retro-cecal appendix.
3. Move to medial side of the cecum and ascending colon; this is commonly where the appendix comes off of the cecum.
4. To correctly identify the appendix, ensure you are seeing a tubular non-compressible structure. (A common pitfall is to misidentify the terminal ileum or another small bowel structure as the appendix.)
5. Once you locate the appendix, trace it all the way to its blind end.

**FOAMed Link:** [For a challenging case of appendicitis POCUS on the EDE blog, go here](#)

**Video:** [Click here for a review of pediatric appendicitis POCUS.](#)

## **CASE 2: THE STOMACH ACHE**

A 14-month-old female presents to your ED with the chief complaint of crying intermittently for the past three hours. Her parents explain that she vomited with each of these episodes. They report no blood per rectum, no fevers, and that she was well prior to the episode. On examination, the child looks very well but her parents tell you she seems more tired than usual. You just had some training in POCUS and want to keep up your skills, so you grab an ultrasound machine and place the probe on the child's abdomen. To your surprise, you immediately see a target sign. Shortly afterward, the child once again develops severe abdominal pain and vomits, but her pain resolves in a few minutes. You call your local pediatric referral centre and refer your patient with the diagnosis of intussusception.



Target sign of intussusception



**Q: The patient doesn't have the classic triad of abdominal pain, vomiting, and bloody stool! Are you sure the diagnosis is intussusception?**

**A:** Intussusception has a wide variety of presentations and age range. The classic triad is seen in only 20% of cases. The lack of textbook presentation may lead clinicians to initially miss the diagnosis, leading to complications such as bowel obstruction and perforation. Using intussusception POCUS in children with non-classic presentations who have abdominal pain or vomiting may capture intussusception cases that may otherwise be discharged as gastroenteritis or viral illnesses.

For more on intussusception, go to [Chapter 10 on Gastroenteritis, Constipation and Obstruction](#).

**Q: In this case you got lucky by seeing the target sign immediately after placing the ultrasound probe on the patient's abdomen. But you won't be so lucky every time. What is your step-by-step approach to intussusception POCUS?**

**A:** Choose the high-frequency probe (also called the linear probe). Begin the scan at a 6 cm to 8 cm depth, but you may need to adjust this based on the patient's body habitus. Start with the probe in the right upper quadrant in the transverse orientation. Ensure that bowel is identified before the probe is moved.



**Clinical Pearl:**

Bowel gas may scatter the image, making for a challenging scan. Light sedation can make the POCUS more comfortable for the patient and allow the POCUS physician to clear some bowel gas by pushing down harder on the abdomen.

For more on [Pediatric Procedural Sedation](#), go to [Chapter 5](#)

**Q: After identifying the bowel and adjusting for the correct depth, what are the next steps?**

**A:** Scan the entire bowel in the transverse orientation. Once all the bowel is seen, rotate the probe into the longitudinal position to once again visualize all the bowel. This should be repeated in all the other abdominal quadrants.

**Q: You've visualized the bowel in all four quadrants. Is this a satisfactory stopping point, or are other areas necessary to visualize?**

**A:** Looking in just the four quadrants is not sufficient. It is important to look along the flank, in the paracolic gutter (slightly lower than standard FAST view) to ensure all the areas of possible intussusception are covered. Once all these areas are visualized, the POCUS is complete.

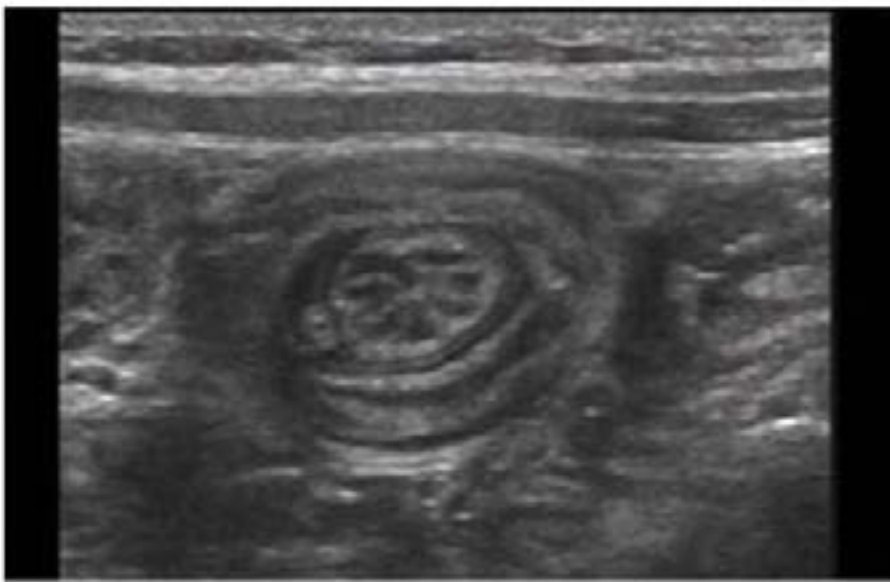

### **Step-by-Step Approach to Intussusception POCUS**

- 1.** Using the linear probe, start in RUQ
- 2.** Set depth at 6 cm to 8 cm
- 3.** Scan transversely making sure to visualize all the bowel
- 4.** Flip probe to longitudinal orientation and repeat scan
- 5.** Apply same steps for each abdominal quadrant
- 6.** Finally, look along the flank, in the paracolic gutter (slightly lower than standard FAST view)

**Q: Great! And what will help you determine if the patient does in fact have intussusception?**

**A:** Look for the target sign or doughnut sign (mmm ... delicious). A target sign can be found in appendicitis, intussusception, and pyloric stenosis. In the transverse view you can see one ring within another. In the longitudinal view it may have a layered appearance of bowel stacked onto itself.



Target sign or doughnut sign

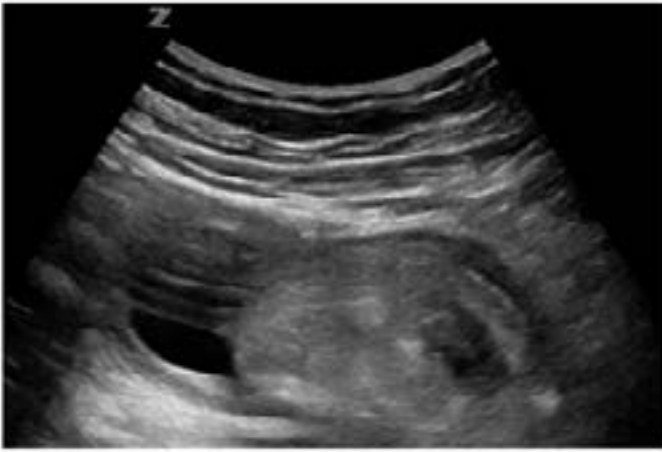**Video:** [\*Dr. Samuel Lam illustrates the technique of POCUS for intussusception in the following video.\*](#)

**FOAMed Link:** [\*For an interesting case of Intussusception picked up by POCUS on the EDE blog, click here.\*](#)

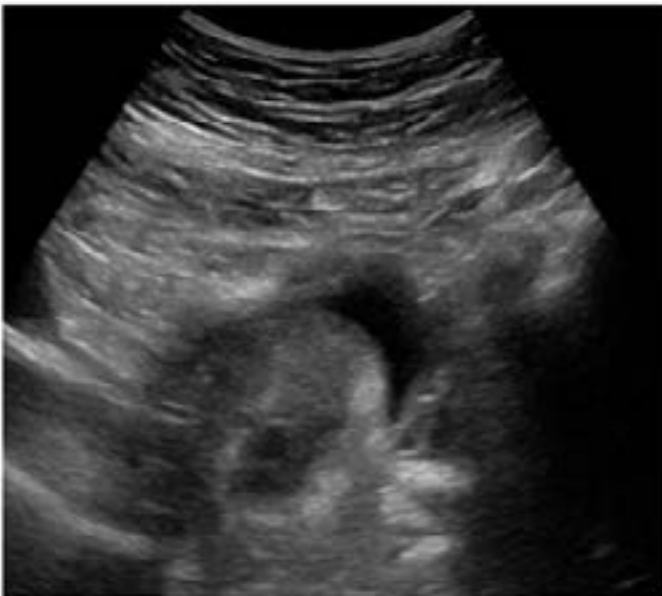
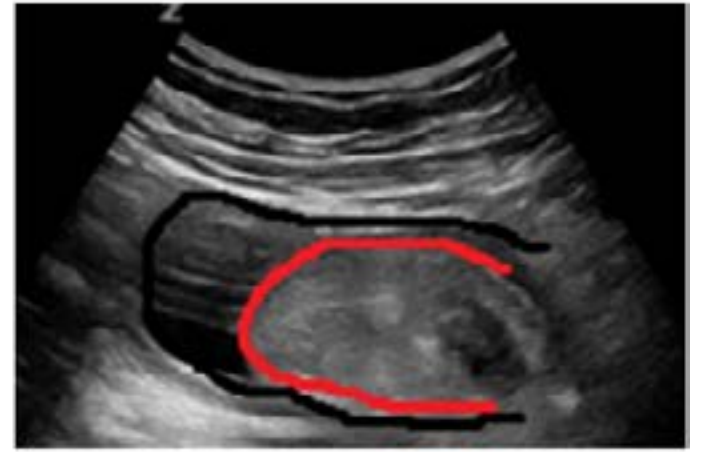

**Clinical Pearl:**

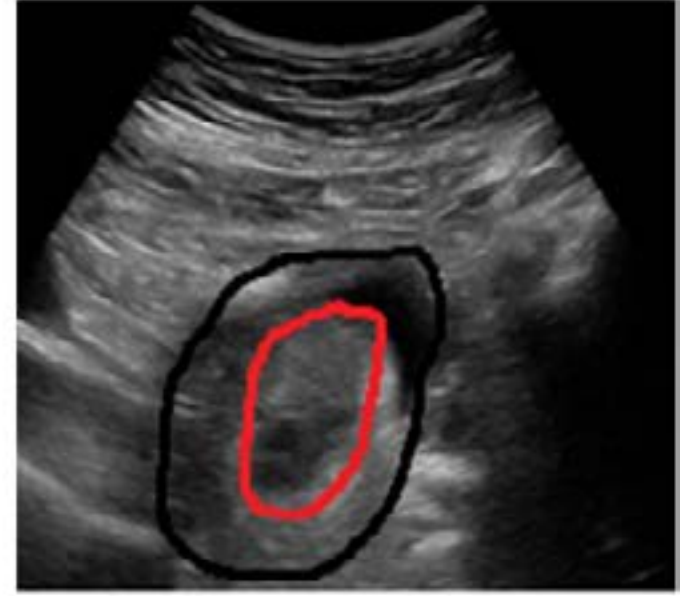Before diagnosing intussusception, ensure that you have seen it in both planes (transverse and longitudinal).



Longitudinal view  
(sausage sign)



Transverse view  
(target sign)



**Comments?**

[Click here to leave a comment or to listen to this podcast.](#)

---

## KEY REFERENCES:

1. Sivitz AB, Cohen SG, Tejani C. Evaluation of acute appendicitis by pediatric emergency physician sonography. *Ann Emerg Med.* 2014; Oct;64(4):358-364.
2. Elikashvili I, Tay ET, Tsung JW. The effect of point of care ultrasound on emergency department length of stay and computed tomography utilization in children with suspected appendicitis. *Acad Emerg Med.* 2014; Feb;21(2):163-170.
3. Pineda C, Hardasmalani M. Pediatric intussusception: A Case Series and Literature Review. *Internet J Pediatrics and Neonatology.* 2008; 11(1):1-7.

# CHAPTER 10: GASTROENTERITIS, CONSTIPATION & OBSTRUCTION

[LISTEN TO THE PODCAST WITH ANNA JARVIS AND STEPHEN FREEDMAN HERE](#)



## Objectives

1. Develop an approach to assessing the child with vomiting and diarrhea
2. Review the management of gastroenteritis
3. Develop an approach to treating functional constipation
4. Understand the pathophysiology of intussusception
5. Describe an approach to the management of intussusception
6. Develop an approach to imaging investigations for pediatric patients with abdominal pain
7. Identify children at risk for mid-gut volvulus
8. Be able to distinguish surgical causes of abdominal pain from sickle cell pain crisis



## CASE 1: VOMITING & DIARRHEA

A seven-year-old boy presents to your ED at 9 p.m. with a history of diarrhea and fever for two days, as well as vague abdominal pain. On further questioning, he has no travel history, his immunizations are up to date, there are no known infectious contacts, and he is otherwise healthy on no medications. He vomited once that morning, has no urinary symptoms, no URI symptoms, and no rash. On exam, his vital signs are normal except for a temperature of 38.1°C. His abdomen is soft, with slight diffuse tenderness, and no peritoneal signs.

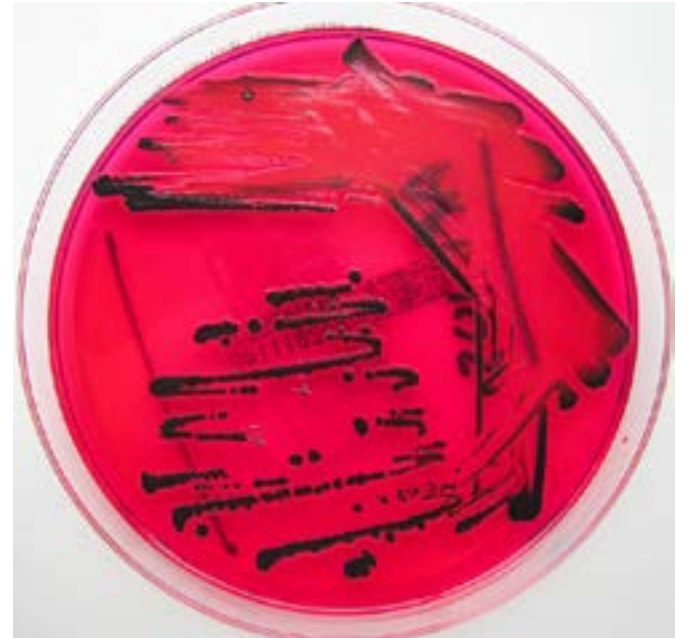**Q: What is your differential diagnosis in this case?**

**A:** As every clinician knows, gastroenteritis is a very common diagnosis for pediatric patients presenting with vomiting and diarrhea. Fortunately, in most cases it has a self-limited and relatively benign course. However, the challenge is being able to accurately distinguish it from more serious illnesses that can present with similar symptoms. At present, there is no simple means to definitively rule in gastroenteritis. Therefore, it should be considered a diagnosis of exclusion.



### Clinical Pearl:

Vomiting in the absence of diarrhea, especially persistent vomiting, should elevate a clinician's suspicion of a more serious alternative diagnoses other than gastroenteritis.



Key diagnoses to consider before making a diagnosis of gastroenteritis:

- Intracranial mass
- Meningitis
- Intussusception
- Diabetic ketoacidosis
- Cholinergic syndrome
- Pneumonia
- Myocarditis
- Appendicitis
- Urinary tract infection

**Q: What are the key aspects of the history when assessing a child who presents with vomiting and diarrhea?**

**A:** It is important to ask about exposure to sick contacts, such as daycare or siblings. In addition, assess for potential risk of either bacterial or parasitic infections by asking about the patient's AND family's recent travel history, antibiotic use, exposure to untreated water or unpasteurized dairy products, and consumption of undercooked or raw meats.

A history of chronic or recurrent episodes of diarrhea can be suggestive of inflammatory bowel disease and require further workup after discharge from the ED.

**Case continued:** Based on the history and physical exam, you determine the most likely diagnosis is gastroenteritis and proceed to assess the child for signs of dehydration.

**Q: What are the most useful signs for assessing for dehydration?**

**A:** Both parental reports and clinician gestalt are surprisingly sensitive for identifying dehydration. However, they are both prone to overestimating the severity, and therefore can lead to excessively aggressive measures of rehydration.

The three most useful clinical exam findings for detecting > 5% dehydration in a child are: prolonged capillary refill, abnormal skin turgor, and abnormal respiration patterns.

Two clinical decision rules, which can be used together or on their own, have been shown to perform better than any single physical exam finding. These are the Gorelick Score and the Clinical Dehydration Scale.



**The Gorelick Score**

Two or more of the following suggests > 5% dehydration:

- Capillary refill > two seconds
- Absent tears
- Dry mucous membranes
- Ill general appearance



## Clinical Dehydration Scale

Characteristic	Points		
	0	1	2
<b>General Appearance</b>	Normal	Thirsty Restless or lethargic Irritable when touched	Drowsy, limp, cold or sweaty Comatose or not
<b>Eyes</b>	Normal	Slightly sunken	Very sunken
<b>Tongue</b>	Moist	Sticky	Dry
<b>Tears</b>	Present	Decreased	Absent

0=No dehydration      1–4 =Some dehydration      5–8=Moderate/severe dehydration

\*Goldman RN, Friedman JN, Parkin PC. Validation of the Clinical Dehydration Scale for children with acute gastroenteritis. *Pediatrics*. 2008; 122 (3): 545-549



### EXPERT OPINION

For practical purposes to direct management, we recommend the following classification for dehydration:

Degree of Dehydration	Signs/Symptoms	Management
<b>Minimal</b>	None of the features below	Safe to be discharged with clear instructions
<b>Somewhat</b>	Some of the following features are present: - Unwell general appearance (fussy, lethargic, irritable) - Dry mucous membranes - Absence of tears - Sunken eyes - Prolonged capillary refill - Abnormal skin turgor - Tachypnea	Oral rehydration therapy to be initiated in ED and reassess
<b>Severe</b>	Most or all of the above features along with abnormal vital signs	IV or NG rehydration indicated



**Q: As you consider your next steps for this patient, you cringe at the thought of having to poke the child for blood. What is the role for laboratory investigations in the context of a child with presumed gastroenteritis?**

**A:** Most children do NOT require investigations. Situations where investigations could be helpful would include a capillary glucose when a child appears lethargic to detect hypoglycemia, a urinalysis in the presence of polyuria or polydipsia to screen for DKA or in children with fever or prior urinary tract infections to screen for another infection.

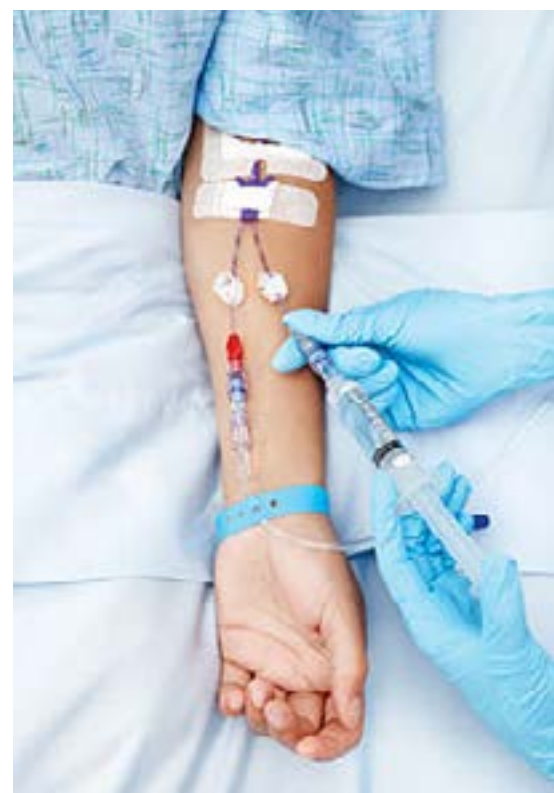Electrolyte abnormalities are usually minor and rarely affect management. A serum bicarbonate of  $> 15$  mEq/l reduces the likelihood of dehydration. However, if you are planning to start IV rehydration, ordering baseline electrolytes are important to monitor for iatrogenic electrolyte derangements.

**Q: After telling your resident that this patient does not require blood work, she asks, “Doesn’t this patient require blood work to rule out hemolytic uremic syndrome?”**

**A:** A complete blood count and creatinine should be ordered if there is clinical concern for hemolytic uremic syndrome (HUS).

HUS is a bacterial enteritis most commonly caused by the Shiga toxin produced by E. Coli 0157:H7 that results in a classic triad of microangiopathic hemolytic anemia, thrombocytopenia, and renal insufficiency.

Clinical features that should raise suspicion for HUS include patients presenting with bloody stool and abdominal pain, lethargy, low-grade fever, paleness and tachycardia, petechia, periorbital edema (especially upon waking), and tea-coloured urine.



**Clinical Pearl:**

Hemolytic uremic syndrome may occur after the diarrhea has resolved.



**Caution:**

Do not give antibiotics empirically to patients at risk for HUS, as it may exacerbate the disease.

**Q: Your resident then asks, “What about a stool culture?” What are the indications for obtaining a stool culture for patients presenting with diarrhea?**

**A:** The indications for obtaining a stool culture are any of the following: travel to an endemic country, > 10 diarrhea stools in 24 hours, > five days duration and not resolving, blood and/or mucous in stools, and unremitting fever.

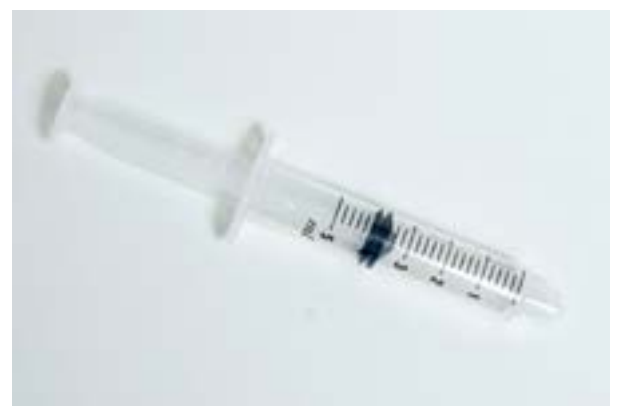On further assessment to determine the child’s hydration, you note that he is irritable, with dry mucous membranes and decreased tears. You calculate his Clinical Dehydration Scale to be 3, suggestive of “some” dehydration being present.

**Q: How would you rehydrate this child with some signs of dehydration from gastroenteritis?**

**A:** Oral rehydration is the treatment of choice for children with acute gastroenteritis who have evidence of some dehydration. Compared with IV rehydration, oral rehydration therapy is associated with a lower risk of complications such as electrolyte imbalances, cerebral edema, phlebitis, and cellulitis.

**Oral rehydration solution dose:** The following doses are administered via syringe, preferably by the parents, q5min, for a goal of 30 ml (1oz)/kg/hour for the first three to four hours:

- 5 cc if < six months old
- 10 cc if six months to three years old
- 15 cc if > three years old
- An additional 10 cc/kg/stool should be administered for each episode of diarrhea in the ED
- The child should continue to breastfeed during this time



Start slow in the first 30 to 60 minutes to minimize the chance of emesis and obtain buy-in from the parents and patient.



**Q: You'd like to give your oral rehydration treatment it's best shot. What is the role for oral ondansetron for treating vomiting in acute gastroenteritis?**

**A:** Compared with placebo, oral ondansetron stops vomiting more frequently (NNT 5), prevents IV insertion (NNT 5), and reduces immediate admission rates without masking serious disease or leading to worse outcomes. Studies suggest there is no change in hospitalizations at 72 hours, as ondansetron does not alter the disease trajectory, and patients with more severe illness can still return to hospital.

Oral ondansetron is dosed according to the child's weight:

Children from 8 kg to 15 kg	2 mg
Children 15kg to 30 kg	4 mg
Children over 30 kg	8 mg

Ondansetron should be given as a single dose. A repeat dose can be considered if the child vomits within 15 minutes of getting the initial dose. Keep children NPO for 15 minutes before starting oral rehydration therapy to allow the medication time to take effect.



**Pitfall:**

Do NOT use ondansetron as a diagnostic test based on response to treatment. If a child stops vomiting after taking ondansetron, it does NOT rule out alternate diagnoses such as appendicitis.



**Caution:**

Ondansetron may prolong the QTc interval. Do not use ondansetron in patients with known prolonged QTc, hypokalemia or hypomagnesemia, congenital heart disease, or CHF.



We suggest that ED physicians do not provide a prescription for ondansetron for outpatient management of vomiting associated with gastroenteritis. There is no evidence of any benefit for this strategy, and repeat dosing has been shown to increase diarrhea. Prescribing ondansetron may also deter parents from bringing their child back for reassessment if the child experiences worsening symptoms.

**Q: The child tolerates the oral rehydration therapy with Pedialyte after receiving a single dose of ondansetron, and appears well enough to be discharged upon reassessment. What are your typical discharge instructions for patients with acute gastroenteritis?**

**A:** The child should resume a regular diet as early as possible and avoid drinks high in sugar, as they can worsen the diarrhea.

There is some literature to suggest that the early initiation of a regular diet including solid food shortens the duration of diarrhea in children with gastroenteritis. There is no evidence to show benefit of using the BRAT (bananas, rice, apple sauce, and toast) diet over a regular diet, and there is no role for ongoing use of oral rehydration solution or fluid-only diet after the patient has been rehydrated in the ED.

The child should return to the ED for reassessment if they develop bloody diarrhea, worsening abdominal pain, increased vomiting, are unable to tolerate fluids, or develop lethargy.

**Q: After receiving the discharge instructions, the parents ask if their child needs antibiotics or antidiarrheal medication. Are antidiarrheal medications or antibiotics recommended for the treatment of acute gastroenteritis?**

**A:** Antibiotics are rarely indicated, even for bacterial pathogens among immunocompetent patients. Consider using antibiotics when a child is persistently ill and high-risk (i.e., immunocompromised, sickle cell disease, corticosteroid use, or recent chemotherapy), or are older than one year of age and have risk factors for a *Clostridium difficile* infection (i.e., recent hospitalizations, recent antibiotic use, history of inflammatory bowel disease, or immunocompromised).

With respect to antidiarrheal agents, neither loperamide nor bismuth should be used in the treatment of acute pediatric gastroenteritis. Loperamide may cause lethargy or paralytic ileus. Alarming, there have also been case reports of death attributed to the use of loperamide. Bismuth is also not recommended as it may lead to salicylate toxicity.

On the other hand, there is some evidence to suggest that probiotics may shorten the duration of diarrheal illnesses and have a far more favourable safety profile. However, they should be avoided in children with indwelling lines, congenital heart disease, or short gut syndrome.

## CASE 2: BLOATED

A two-year-old girl presents at 9 p.m. to your ED with several hours of intermittent crying and looking “bloated.” There is no history of vomiting, fever, or urinary symptoms, and the last bowel movement two days ago was normal. Last week, she had a mild upper respiratory tract infection that resolved spontaneously. She is otherwise healthy with no past medical or surgical history, and is taking no medications. On exam, the vital signs are normal except for a slightly high heart rate and a temperature of 38.0°C. The abdomen is soft and non-tender, and bowel sounds are present. An abdominal X-ray shows a moderate amount of fecal loading and no obvious signs of obstruction. The girl is diagnosed with constipation, and discharged home with a script for lactulose and dietary instructions.



**Q: How is pediatric functional constipation defined? How do you make the diagnosis in the ED?**

**A:** Functional constipation is the most common cause of abdominal pain in children, but should still remain a diagnosis of exclusion.

The most widely accepted definition for functional constipation are the Rome III criteria. There are two sets of criteria, one for children who have a developmental age younger than four years of age, and another for children with a developmental age of four years or older.



### **The Rome III Diagnostic Criteria for Functional Constipation**

In the absence of organic pathology, at least two of the following must occur for one month for a child with a developmental age < four, and at least once a week for two months for a child with a developmental age of  $\geq$  four.

1. Two or fewer defecations per week
2. At least one episode of fecal incontinence per week after the acquisition of toilet training skills
3. History of excessive stool retention or retentive posturing
4. History of painful or hard bowel movements
5. Presence of a large fecal mass in the rectum
6. History of large-diameter stools that may obstruct the toilet

**Q: What are some red flags that should alert a physician to consider diagnoses other than functional constipation?**

**A:** Some red flags on history that are suggestive of more serious diseases include a history of fever, abdominal distention, anorexia, nausea or vomiting, weight loss, delay in first bowel movement for more than 48 hours after birth, and blood in the stools.

On physical exam, the astute clinician should also note the absence of stool in the rectum on digital rectal exam in the presence of a large palpable fecal mass in the abdomen, abdominal distension, and evidence of lower back skin defects.



### **Clinical Pearl:**

Diseases to consider in the child with constipation:

- **Hirschsprung's disease:** Presents as severe obstipation with overflow diarrhea and abdominal distension in a non-thriving, fussy child; it can also present as toxic megacolon
- **Hypothyroidism and cystic fibrosis:** Assess family history and whether family members were screened
- **Down syndrome**
- **Myelomeningocele or neuromuscular diseases:** Can present with history of a delay to walking or unusual gait
- **Celiac disease:** May have a family history
- **Child abuse**

**Q: You are now more sure that this is functional constipation. How do you treat functional constipation?**

**A:** Oral medications work better when combined with enemas in the ER. After initiating treatment, it is important to explain to parents that it can take months to years to retrain the bowel.

For enemas, if the child is younger than two years old, use a saline enema at 20 cc/kg. Children > 20 kg can use an adult fleet enema.

Upon discharge home, patients should be instructed to take PEG 3350 (e.g., Laxaday) at a dose of 1–1.5 g/kg/day dissolved in 240 ml of fruit juice until the child has one soft stool per day for three days, and then titrate down the dose. PEG 3350 is preferred over lactulose.

**Q: Are there any dietary or lifestyle recommendations that can help to improve functional constipation?**

**A:** Infants four to eight months of age are advised to add 120 ml of fruit juice to their diet, substitute barley cereal in place of rice cereal, and use glycerine suppositories as needed.



Older children can be advised to increase their intake of fluids and fibre (e.g., bran cereals, fruits such as pears or prunes, and beans).

Children can also supplement with a daily powdered fibre such as Metamucil (¼ tsp if younger than six years old, ½ tsp for children six to 12, and 1 tsp for children older than 12 years) taken with a large cup of water.

With respect to behaviour modifications, parents should promote unhurried toilet time after meals and track activity with a stool diary.

**Case continued:** The next day, the family returns to the ED and the child looks lethargic, pale, and tachypneic, with a distended abdomen. The girl is placed on a monitor and an IV is started in the resuscitation room. A 20 cc/kg NS bolus is given, as well as IV antibiotics to cover for possible sepsis. A portable abdominal X-ray is ordered and blood work is sent. The X-ray shows prominent loops of bowel. A venous blood gas comes back showing a metabolic acidosis with pH of 7.1. A rectal examination is done with a positive fecal occult blood test. The patient was stabilized and sent for advanced imaging.

**Q: What diagnosis is at the top of your differential now?**

**A:** Intussusception.

**Q: What is the typical presentation for intussusception?**

**A:** Intussusception predominantly occurs in children younger than two years of age, and is unlikely to occur after the age of seven. It can often occur during viral gastroenteritis outbreaks, as inflamed enlarged Peyer's patches within the intestinal wall can act as a lead point for the intussusception to occur.

There are two common and classic presentations for intussusception:

1. Vomiting with severe paroxysmal episodes of abdominal pain
2. The listless, lethargic infant



### Clinical Pearl:

Parents sometimes describe the child as pale and sleepy in between episodes of paroxysmal pain.



### Clinical Pearl:

“Currant jelly stools” are a late finding in intussusception, and are often absent on initial presentation to the ED. The absence of currant jelly stools should not dissuade a clinician from a diagnosis of intussusception.

The abdominal presentation may manifest as severe crying episodes (as in this illustrative case) lasting one to five minutes, separated by pain-free intervals of three to 30 minutes in duration during which the child may actually appear either tired and drowsy or return to normal activities. This cyclic pattern occurs as the peristaltic wave encounters the intussusception region. The vomitus is usually non-bilious since the obstruction is typically distal in the ileocecal region.

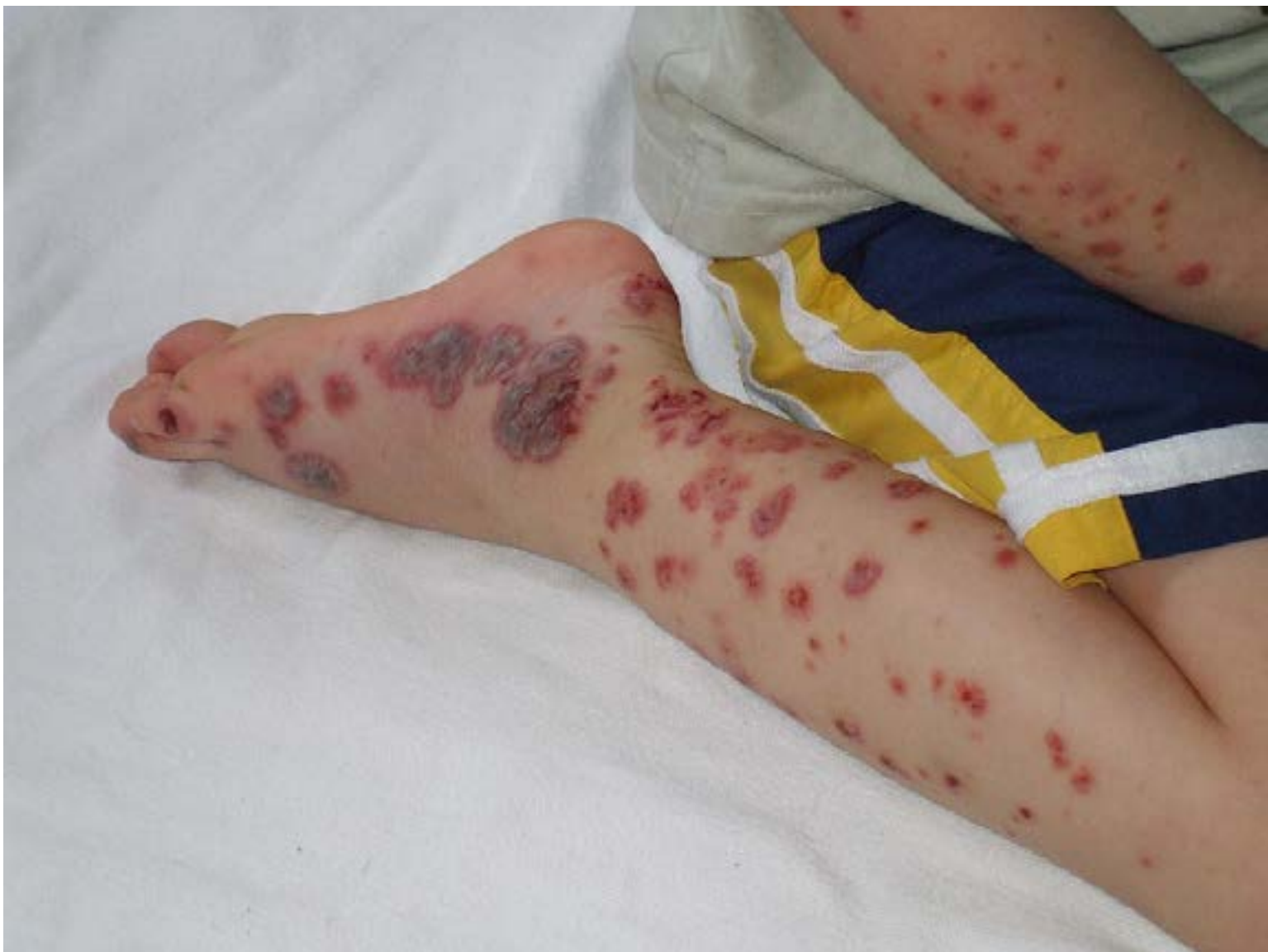The **classic triad** of intussusception consists of colicky intermittent abdominal pain, vomiting, and “currant jelly stools.” However, as with all “classic triads,” this constellation occurs relatively infrequently, accounting for only 10% to 20% of documented cases.

Typically, the episodes of pain will intensify and increase in duration with shorter pain-free intervals. Vomiting usually develops within the first six to 12 hours.

**Q: You make the diagnosis of intussusception and the parents ask you what may have caused this. You also begin to consider causes of intussusception and wonder about other diagnoses not to miss in this patient. What diagnosis should you consider?**

**A:** Henoch-Schonlein purpura (HSP) is frequently implicated as a potential cause for intussusception. HSP is a vasculitis that affects children predominantly between the ages of two to 11 years old. It is classically characterized by the triad of abdominal pain, arthritis, and palpable purpura.

The abdominal pain is typically diffuse and colicky, and may precede the rash, making the diagnosis more difficult. The arthritis is migratory, usually targeting the knees and ankles, and associated with periarticular swelling and redness on exam. The palpable purpuric rash is the hallmark of HSP. It usually is isolated to the buttocks and lower extremities and may look urticarial or petechial.



Other findings associated with HSP include hematuria and proteinuria, recent viral illness, scrotal edema, and history of bloody stools.

About 5% of cases of HSP will present as intussusception, where areas of bowel edema secondary to the vasculitis serve as a lead point.



## **The International Consensus Conference Diagnostic Criteria for HSP**

Palpable purpura in the presence of one or more of the following:

- Diffuse abdominal pain
- Any biopsy showing predominant IgA deposition
- Arthritis or arthralgias
- Renal involvement (hematuria or proteinuria)



### **Clinical Pearl:**

**Atypical presentations of intussusception** include:

- Older children with intermittent abdominal cramping and no vomiting
- Vomiting in the absence of abdominal pain
- Very early presentations of vomiting that resemble gastroenteritis
- Infants that present with lethargy or seizures suspicious for CNS disease or sepsis
- Patients presenting with hematemesis



### **Caution:**

A recent viral illness can be a precipitating factor for intussusception. Therefore, DON'T attribute a child's abdominal pain to their recent viral illness before considering intussusception.

**Q: What should you be looking for on physical exam for the patient with suspected intussusception?**

**A:** The patient may appear pale and lethargic in between episodes, and show signs of dehydration such as a prolonged capillary refill, abnormal respirations or dry mucous membranes.

However, the exam between episodes of abdominal pain can also be relatively unremarkable. A well-appearing child with a good history for intussusception warrants further observation in the ED.



**Pitfall:**

A common pitfall is assuming that a well-appearing child cannot have intussusception. A well-appearing child in the ED can certainly still have an intussusception, as you may be assessing them in between the paroxysms of pain, crying, or vomiting.

A sausage-shaped abdominal mass can sometimes be palpated in the RUQ. This sausage mass can best be palpated in those who have very soft abdomens. In most infants and children with intussusception, the abdomen is very soft once the painful cycle has passed, facilitating the palpation of the mass.

Experienced clinicians who have examined many children may be able to detect a subtle emptiness in the RLQ (known as “dance sign”), with the intussuscepted segment of bowel migrating up to the RUQ.

While the utility of a rectal examination for most cases of pediatric abdominal pain has been called into question, the presence of fecal occult blood can be an early clue for intussusception well before the onset of currant jelly stools.

The remainder of the exam should focus on ruling out alternative diagnoses that can present in a similar manner, such as an inguinal hernia, testicular torsion, midgut volvulus, sepsis, meningitis, or non-accidental trauma.

**Q: Should you order any further investigations? What role does plain radiography serve in diagnosing intussusception?**

**A:** Although plain film radiographs of the abdomen have poor sensitivity, there are a number of potential findings that can be highly suggestive of intussusception. It is estimated that up to 25% of abdominal plain films are normal in patients who have a final diagnosis of intussusception. However, subtle findings such as a target sign or crescent sign can warrant consultation with a surgeon (see images on following pages). In addition, plain films can be used to screen for potential complications such as perforated viscus or evidence of a small bowel obstruction.





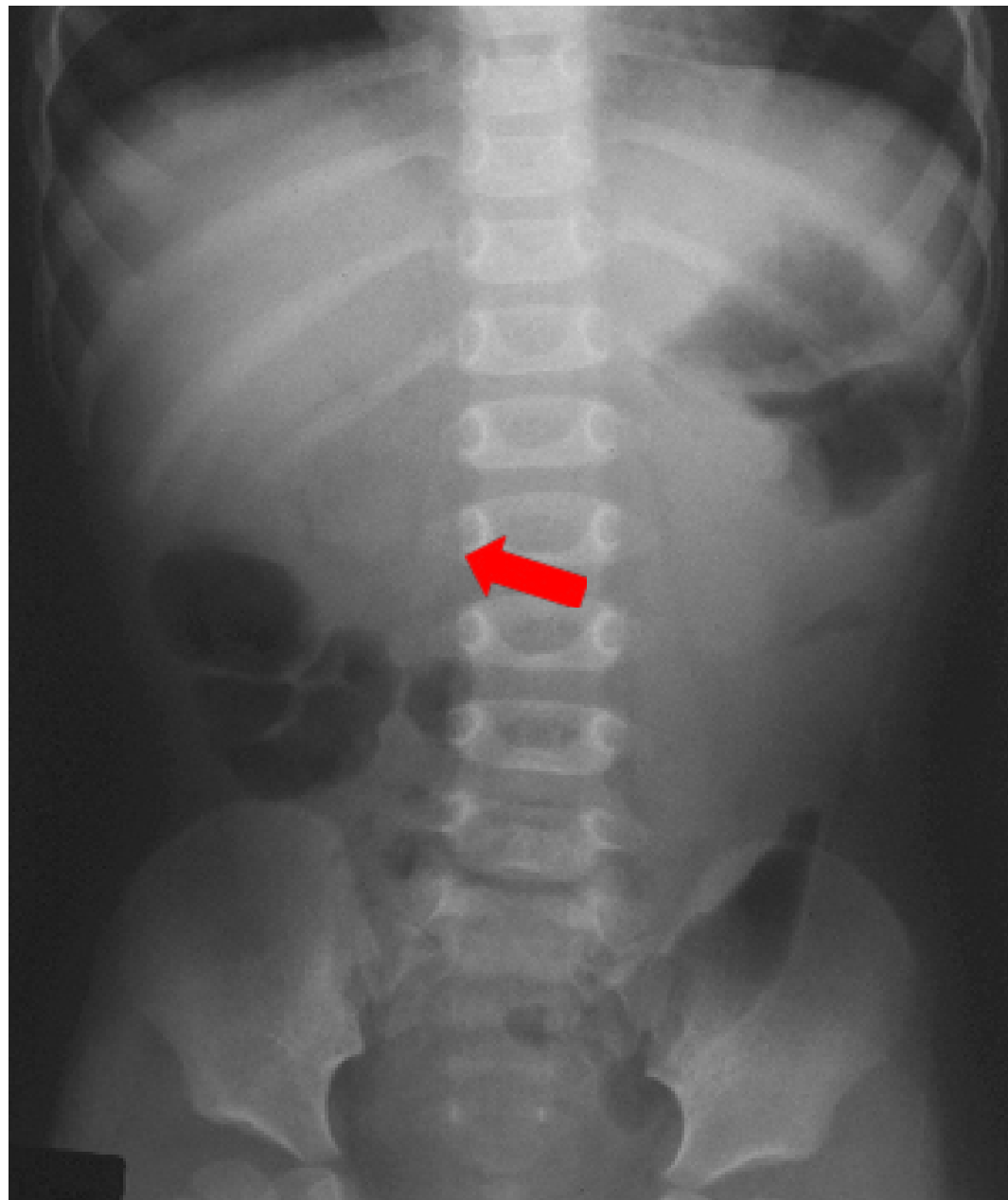
### Clinical Pearl:

The “big three” findings to look for on EVERY pediatric plain film of the abdomen:

- Free air to detect perforated viscous
- Multiple air fluid levels to detect small bowel obstruction
- The double bubble sign to detect proximal obstructions such as volvulus

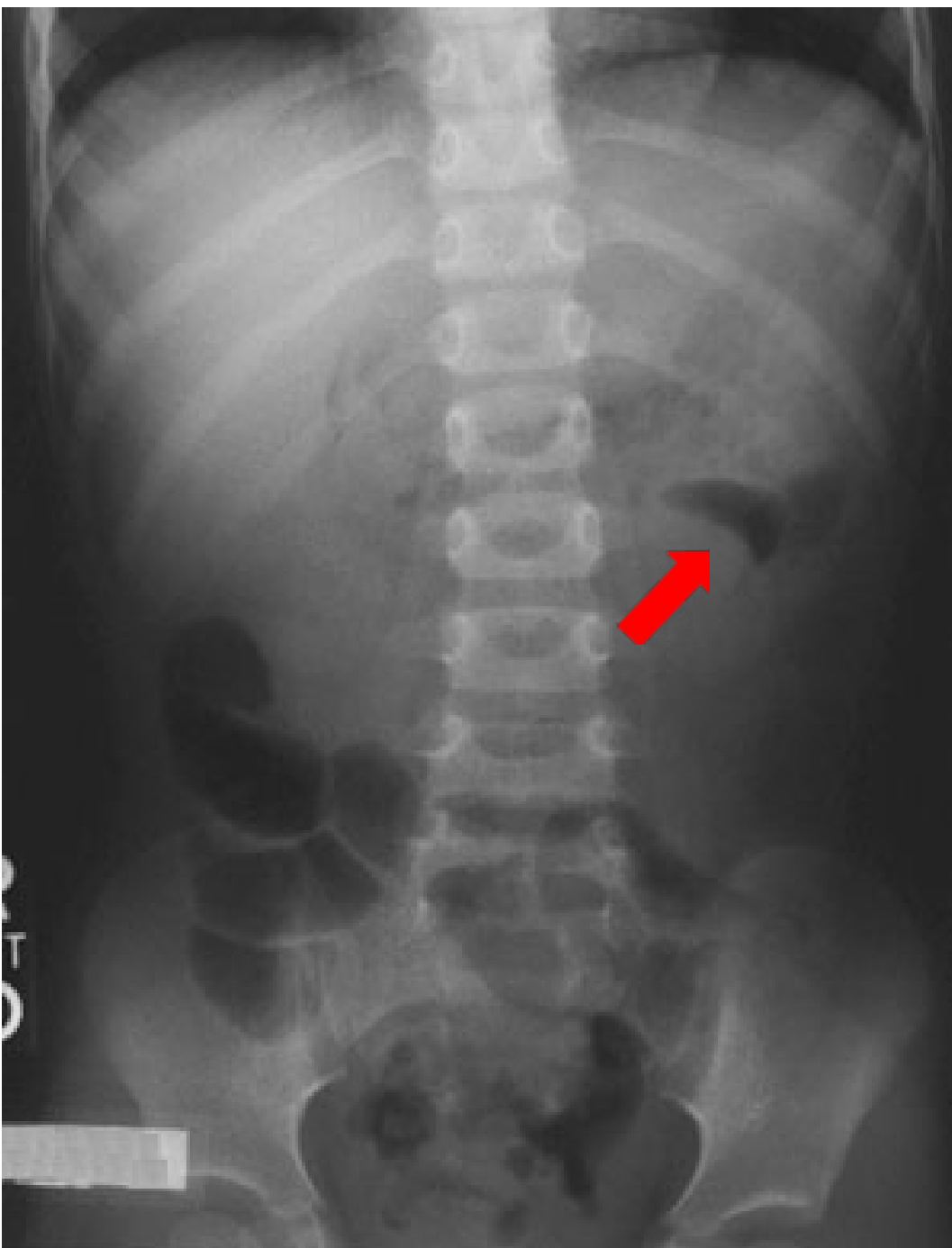### Three plain film signs specific to intussusception:

The **target sign** is a faint, doughnut-shaped mass in the right upper quadrant; it is subtle, so you must specifically be looking for it, and its presence is near diagnostic of intussusception.



An example of the subtle yet fairly specific sign of intussusception

The **crescent sign** occurs because the leading point of the intussusception (intussusceptum) protrudes into a gas-filled pocket. When this occurs, a crescent shape may result and is highly indicative of intussusception. The shape of the crescent will always be in the direction of transit through the colon (i.e., upward in the ascending colon, right to left in the transverse colon, and downward in the descending colon).



Crescent sign seen in intussusception

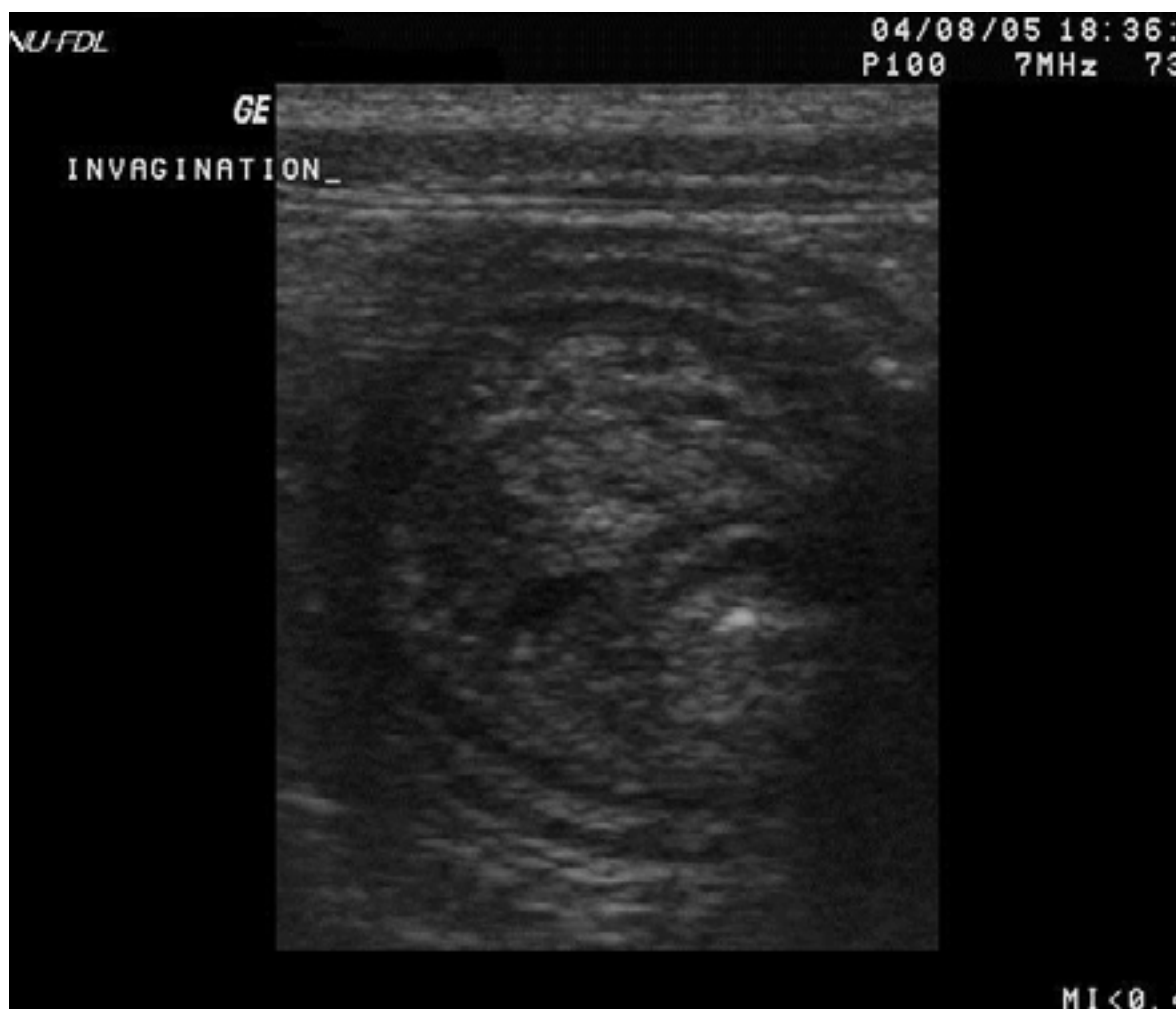

If there is evidence of a bowel obstruction on a pediatric X-ray, use the mnemonic “Double A-I-M” to generate a differential for the underlying etiologies:

- **A**dhesions
- **A**ppendicitis
- **I**ntussusception
- **I**ncarcerated hernia
- **M**alrotation/volvulus
- **M**eckel’s diverticulum

**Q: All this considered, what is your diagnostic test of choice for intussusception?**

**A:** Ultrasound is regarded by many as the best test for diagnosing intussusception, with near 99% sensitivity, and it is less invasive than a contrast enema study. Similar to X-ray, ultrasound can identify a target sign (a hypoechoic ring with a hyperechoic centre). It can also often identify the leading edge along with Doppler flow studies to detect ischemic segments of bowel, to assist with surgical planning.



Target sign of intussusception on ultrasound

For more on POCUS for intussusception, jump to [Chapter 9](#).

**Case continued:** The ultrasound was positive for intussusception. The surgeon was consulted, and she opted not to do an air-contrast enema, and instead took the patient to the operating room, where she found perforated bowel and intestinal ischemia. The patient had a long postoperative recovery, but ended up doing well.

**Q: Contrast enema studies have the dual benefit of being potentially both diagnostic and therapeutic for intussusception. What are potential contraindications for contrast enema studies?**

**A:** An enema can perforate the bowel if the gut is ischemic. Gastrografin has a high osmolality and can produce shock (secondary to intravascular depletion) in the case of perforation. Some centres prefer air-contrast enemas since they result in smaller tears in the event of perforation. Using air is also less expensive, requires less radiation, and leads to shorter fluoroscopy times.

Contraindications for performing a contrast enema include:

- Suspected or confirmed perforation
- Symptoms lasting longer than 24 hours
- Evidence of obstruction
- Intestinal ischemia

---

## **CASE 3: OBSTRUCTED**

A five-year-old boy is brought to the ED with a chief complaint of diffuse abdominal pain and persistent vomiting for the past 24 hours. He has not tolerated oral fluids at home. His last bowel movement was two days ago and his last urination was 12 hours ago. He has no fever, diarrhea, dysuria, or coughing. His past history is significant for two previous episodes of severe abdominal pain, which resolved on their own.

On exam his vital signs were normal: heart rate 100, respiratory rate 30, blood pressure 110/70. He is moderately ill appearing; pale with dry mucous membranes and diminished skin turgor. His abdomen is soft and slightly tender all over. Bowel sounds are diminished. He has no inguinal hernias and his genitals are normal.

An abdominal X-ray is done that shows findings of an obstruction, suspicious for midgut volvulus.

**Q: What is volvulus, and how does it occur?**

**A:** The mesentery is suspended by a stalk containing its own vascular supply. In midgut volvulus, the entire stalk can twist on itself, leading to life-threatening ischemia of the entire small bowel. Midgut volvulus has a high mortality rate when it is not surgically corrected in a timely manner.

Children born with congenital malrotation are at high risk for midgut volvulus. Roughly half of those born with malrotation will manifest with an acute bowel obstruction during the first few months of life.

**Q: The early diagnosis and treatment of midgut volvulus is essential to avoid catastrophe. When should a clinician consider midgut volvulus?**

**A:** A clinician should be extra vigilant to identify midgut volvulus with any neonate presenting with a sudden onset of bilious vomiting, abdominal pain, or distension.



**Clinical Pearl:**

Be sure to also consider midgut volvulus in any child who appears septic from a presumed abdominal source.



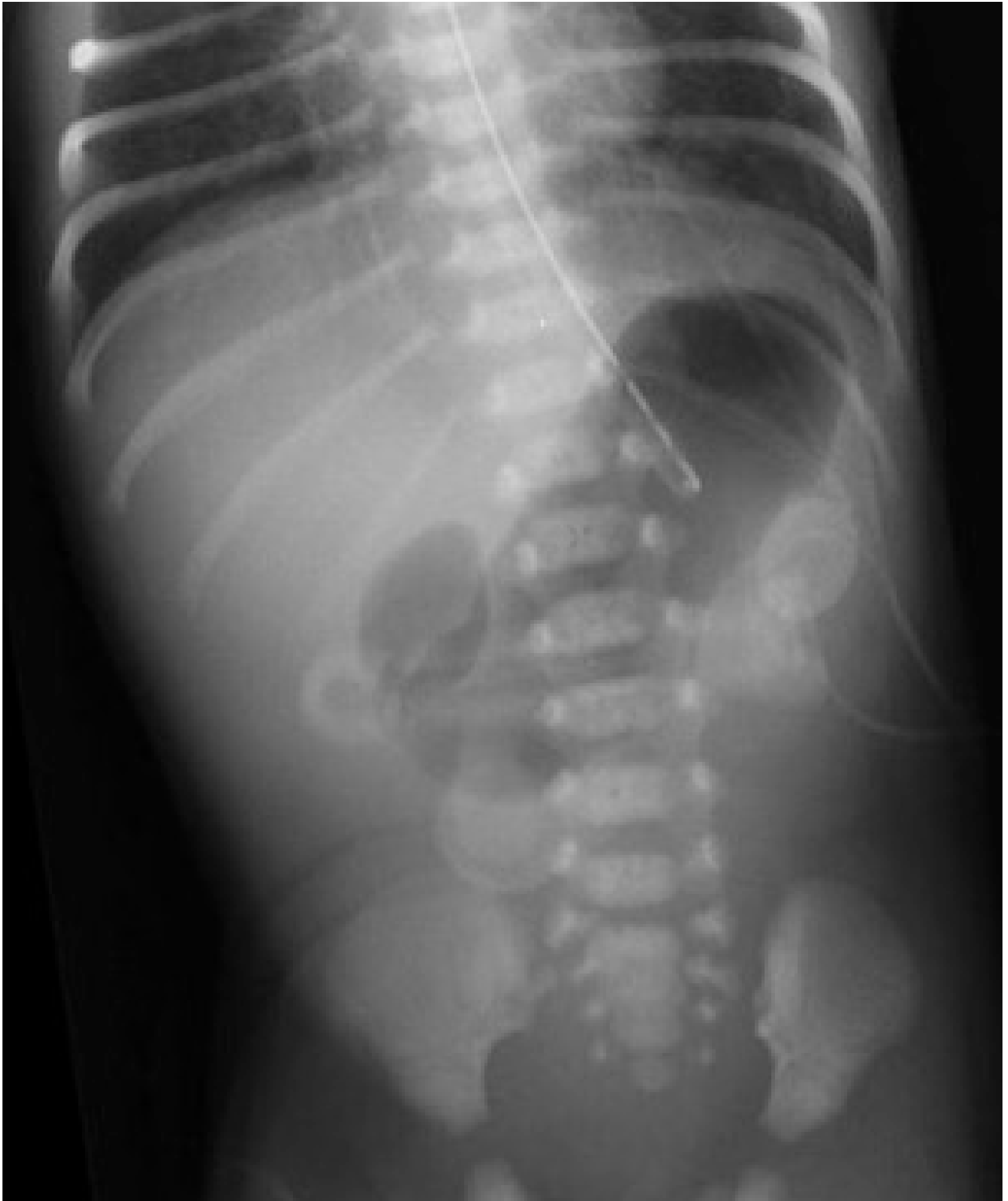**Pitfall:**

Any infant presenting with bilious vomiting should be considered to have midgut volvulus until proven otherwise.

**Q: How do you make the diagnosis of midgut volvulus?**

**A:** Plain film x-rays of the abdomen can show evidence of a proximal bowel obstruction, also known as the double bubble sign, with one bubble in the stomach and one in the duodenum.





Double bubble sign in midgut volvulus

Ultrasound is not nearly as definitive as it is for intussusception, but it can be suggestive of the diagnosis. The most specific finding is the presence of the superior mesenteric artery on the **right** (opposite) side of the mesenteric vein. It is important to note that a negative ultrasound does not rule out midgut volvulus.

The gold-standard test for midgut volvulus is an upper GI series under fluoroscopy. This will allow definitive visualization of the small intestine rotated on the right side of the abdomen.

**Case continued:** You receive a verbal report that the child's ultrasound is very suggestive of midgut volvulus. Seconds later, the nurse calls you STAT to the child's bedside. The child is now tachycardic with a heart rate of 200 bpm, and the blood pressure is 60 mmHg on palpation. She appears very lethargic and unwell.

**Q: What treatments need to be initiated immediately in the ED for this patient?**

**A:** This child requires aggressive fluid resuscitation, with a minimum of two 20 cc/kg boluses of normal saline. Broad spectrum antibiotics should be initiated that cover Gram-positive, Gram-negative, and anaerobic organisms (e.g., ampicillin, gentamicin, and clindamycin). Surgery should be consulted in parallel with the implementation of these treatments.

.....

## **CASE 4: PMHx SICKLE CELL DISEASE**

An adolescent female with a history of sickle cell disease presents with nausea, vomiting, and poorly localized abdominal pain that has prevented her from attending school. She is adamant that this feels different than her previous vaso-occlusive pain crisis. She denies any chest pain, back pain, or arthralgias. She is afebrile and slightly tachycardic, with a heart rate of 105 bpm. Her blood pressure is 110/75. She appears uncomfortable on exam and is noted to have tenderness in the RUQ. She has no prior surgeries.

**Q: How can a clinician distinguish a sickle cell pain crisis from a surgical abdomen?**

**A:** Unfortunately, a vaso-occlusive pain crisis can perfectly mimic a surgical abdomen, with patients presenting with symptoms of nausea, vomiting, fever, and peritoneal tenderness.

Leukocytosis is a near universal finding, and of virtually no discriminatory value.

Although very little evidence exists in the literature, many experienced clinicians will report that if the pain is reported to be similar to a previous pain crisis, an underlying surgical etiology is less likely.

In contrast, pain that occurs in the absence of typical bone or joint symptoms is more likely to be associated with a problem requiring surgery.



**Clinical Pearl: High-Yield Associations and Pearls in Pediatric Abdominal Pain**

- Intermittent pain with a change in stools (esp. bloody) ==> Intussusception
- Neonate with bilious vomiting ==> Midgut volvulus
- Scrotal swelling or discolouration ==> Testicular torsion
- Polyuria and polydipsia ==> DKA
- Recent mononucleosis ==> Splenic rupture
- Petechial rash on buttocks and legs ==> Henoch-Schonlein purpura
- Hematuria and proteinuria ==> Henoch-Schonlein purpura
- Sterile pyuria ==> Appendicitis
- Glucosuria and ketonuria ==> DKA
- Occult blood in stool ==> Intussusception or midgut volvulus

## KEY REFERENCES:

1. Steiner MJ, DeWalt DA, Byerley JS. Is this child dehydrated? *JAMA*. 2004; Jun;291(22):27-46.
2. Freedman SB, Vandermeer B, Milne A, Hartling L, Pediatric Emergency Research Canada Gastroenteritis Study Group. Diagnosing clinically significant dehydration in children with acute gastroenteritis using noninvasive methods: a meta-analysis. *J Pediatr*. 2015; Apr;166(4):908-916.
3. Friedman JN, Goldman RD, Srivastava R, Parkin PC. Development of a clinical dehydration scale for use in children between 1 and 36 months of age. *J Pediatr*. 2004; Aug;145(2):201-7.
4. Gorelick MH, Shaw KN, Murphy KO. Validity and reliability of clinical signs in the diagnosis of dehydration in children. *Pediatrics*. 1997; May;99(5).
5. Freedman SB, Adler M, Seshadri R, Powell EC. Oral ondansetron for gastroenteritis in a pediatric emergency department. *N Engl J Med*. 2006; Apr;354(16):1698-705.
6. Fedorowicz Z, Jagannath VA, Carter B. Antiemetics for reducing vomiting related to acute gastroenteritis in children and adolescents. *Cochrane Database Syst Rev*. 2011; Issue 9.
7. Bernaola Aponte G, Bada Mancilla CA, Carreazo NY, Royas Galarza RA. Probiotics for treating persistent diarrhea in children. *Cochrane Database Syst Rev*. 2013; Issue 8.
8. Goldenberg JZ, Lytvyn I, Steurich J, Parkin P, Mahant S, Johnston BC. Probiotics for the prevention of the pediatric antibiotic-associated diarrhea. *Cochrane Database Syst Rev*. 2015; Issue 12.
9. Hymen PE, Milla PJ, Benninga MA, Davidson GP, Fleisher DF, Taminiau J. Childhood functional gastrointestinal disorders: neonate/toddler. *Gastroenterology*. 2006; Apr;130(5):1519-26.
10. Rasquin A, Di Lorenzo C, Forbes D, et al. Childhood functional gastrointestinal disorders: child/adolescent. *Gastroenterology*. 2006; Apr;130(5):1527-37.
11. Dillon MJ, Ozen S. A new international classification of childhood vasculitis. *Pediatr Nephrol*. 2006; Sep;21(9):1219-22.

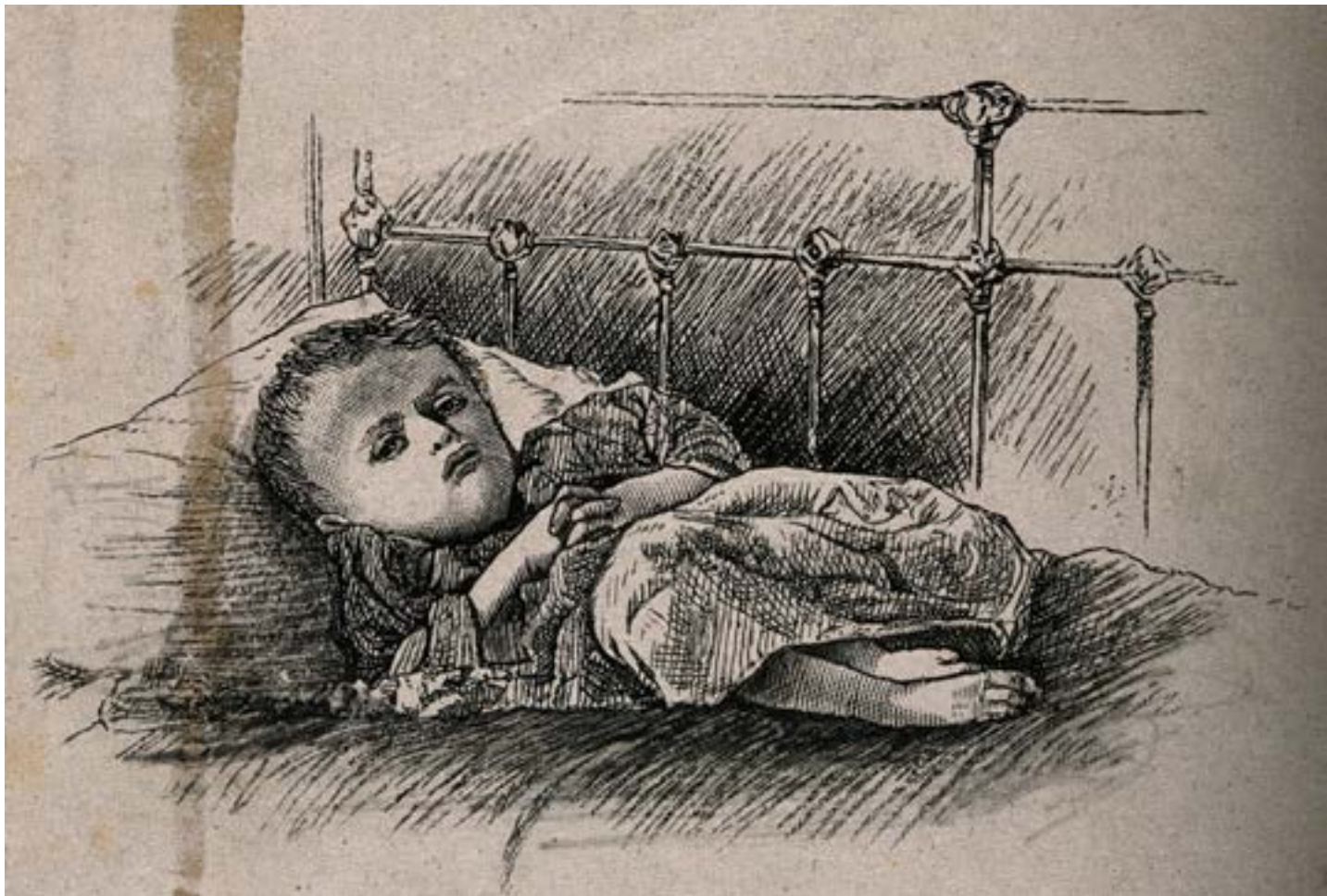

### Comments?

[Click here to leave a comment  
or to listen to this podcast.](#)

# CHAPTER 11: DIABETIC KETOACIDOSIS

[LISTEN TO THE PODCAST WITH SARAH REID AND SARAH CURTIS HERE](#)



## Objectives

1. Identify aspects of the history and physical exam that should prompt one to suspect DKA in children
2. Develop an understanding of the diagnostic criteria for DKA and how this directs investigations in whom the diagnosis is suspected
3. Develop an approach to the management of DKA based on disease severity
4. Understand the risk factors and clinical presentation of cerebral edema in DKA patients
5. Develop an approach to the management of cerebral edema in DKA patients



## **CASE 1: APPROACH TO DIABETIC KETOACIDOSIS (DKA)**

A four-year-old boy presents to your academic ED with his parents complaining of abdominal pain and shortness of breath since waking that morning. They report a low-grade fever two days ago, which has now resolved, no vomiting, and normal bowel movements. He has had a mild cough for three days but no chest pain. They report that he's been going to the bathroom more often than usual to urinate. His past medical history is unremarkable.

On exam he appears fatigued but is alert and oriented with a GCS of 15. He is tachypneic with deep respirations but no indrawing. The patient has a clear chest, capillary refill is two seconds, and mucous membranes are dry. Abdominal exam is benign and the neurological exam is grossly normal.

**Q: Yes, this is a DKA chapter, so the diagnosis is DKA. However, this case describes very non-specific symptoms, which may not trigger a consideration of DKA. What are some of the clues in this case that should trigger one to consider DKA?**

**A:** Most patients will not present with the classic constellation of polyuria, polydipsia, nausea/vomiting, and abdominal pain. The presence of tachypnea with a clear chest should prompt the consideration of acidosis. Hyperventilation is an attempt to release CO<sub>2</sub> from the blood as a respiratory compensation for the metabolic acidosis associated with DKA. This breathing pattern is called Kussmaul breathing.

Polyuria on history should prompt the consideration of three diagnoses in pediatric patients: urinary tract infection, hyperglycemia, and hypercalcemia. Abdominal pain without associated gastrointestinal symptoms (or with isolated vomiting) should prompt consideration of DKA. Consider this diagnosis in any child with altered mental status, and remember that "glucose is the sixth vital sign!"

**Q: You suspect the diagnosis of DKA in this child. You know it is also important to assess for an underlying trigger for this episode of DKA. What are the common triggers for DKA?**

**A:** Underlying viral or bacterial infection are common triggers for DKA. This four-year-old boy had a mild cough and fever, which likely triggered his DKA presentation. In patients with known diabetes, high-risk groups for DKA are those with a prior history of DKA, peri-pubertal and adolescent girls, and those on insulin pumps. Adolescent girls may reduce insulin use in an attempt to lose weight, which predisposes to DKA. In patients with known diabetes, always assess for insulin adherence and inquire regarding missed insulin doses.

**Q: Your student on shift asks, “Why do kids with DKA get so sick? And why do they look so dehydrated?” An understanding of the pathophysiology of DKA helps to understand the management strategies. What are the underlying metabolic derangements in DKA?**

**A:** DKA is most commonly seen in patients with type 1 diabetes since the disease is defined by insulin deficiency. The lack of insulin prevents glucose from entering the cells of the body and being used as an energy source. Stress hormones are released due to the body’s perceived energy supply deficiency. This causes further glucose release from glycogen stores as well as the breakdown of free fatty acids into a usable energy source. Fatty acid breakdown leads to the formation of keto-acids, which accumulate in the blood and cause acidosis. The accumulation of glucose in the blood eventually overwhelms the ability of the kidney to reabsorb glucose, causing loss of glucose in the urine and resulting osmotic diuresis and dehydration.

**Q: Given the pathophysiology underlying DKA, what are the criteria we use to diagnosis it?**

**A:** The diagnosis of DKA requires the presence of acidosis, ketosis, and hyperglycemia.



**AH-HA**

### **Diagnostic Criteria for DKA**

Diabetes: Random serum glucose >11.1 mmol/L

Acidosis: pH<7.3 OR HCO<sub>3</sub><15

Ketosis: Ketones on urine dipstick or urinalysis

**Q: Given these diagnostic criteria, what tests will you order for this child with suspected DKA?**

**A:** Once a capillary glucose is obtained and DKA is suspected, initial investigations would include CBC, electrolytes, BUN, creatinine, urinalysis, and a VBG. If the patient is hypokalemic or hyperkalemic, an ECG is warranted. Other investigations can be directed at finding an underlying trigger for DKA, such as a chest X-ray if pneumonia is suspected, for example.



A urinalysis to detect the presence of ketones (as apposed to serum

ketones) is adequate in the vast majority of pediatric patients for the detection of ketosis in DKA. While the sensitivity of urine ketones may be less than serum ketones early in the disease course, clinical experience of our experts suggests the urine ketones are rarely negative in DKA. In patients with elevated glucose and osmolality but negative urine ketones, you can consider the diagnosis of hyperglycemic hyperosmotic syndrome (HHS). However, this is very rare in pediatric patients, as this is usually associated with type 2 diabetes. Like any test, it needs to be interpreted in light of your pretest probability. If urine ketones are negative and you have a high index of suspicion for DKA, this warrants further testing with serum ketones or a VBG.

**Q: The child in this case appears to be quite sick. The management of the child will depend on the severity of disease. How do you determine the severity of the DKA?**

**A:** The severity of DKA is classified based on the degree of acidosis and the  $\text{HCO}_3$  level.



**Clinical Pearl:**

Acidosis determined from a venous blood gas (VBG) is just as useful in the management of DKA as an arterial blood gas (ABG) in pediatric patients. Save the patient the difficult poke of an ABG and just use the VBG.

**Severe  
DKA**

- $\text{pH} < 7.1$
- $\text{HCO}_3 < 5$

**Moderate  
DKA**

- $\text{pH} < 7.2$
- $\text{HCO}_3 < 10$

**Mild  
DKA**

- $\text{pH} < 7.3$
- $\text{HCO}_3 < 15$

**Q: You are working in an academic hospital that sees adult patients almost exclusively, and so you are more familiar with managing DKA in adults. In general, how does the management of DKA differ between adults and pediatric patients?**

**A:** The key goals in managing DKA are to correct hypovolemia, correct acidosis, reverse ketosis, restore glucose to near normal, monitor for complications, and treat any precipitating event. While these principles are true both in adult and pediatric populations, there are major differences in management between adults and pediatric patients.

- 1. IV fluids:** While adult DKA guidelines recommend multiple fluid boluses in the first two hours of care, fluid boluses are indicated only in pediatric patients who are in decompensated shock. Judicious use of IV fluids is encouraged with twice maintenance being the upper limit of the rate of administration.
- 2. Potassium management:** Adult DKA patients have strict potassium cut-offs that guide insulin administration, but potassium management in pediatric DKA is less stringent. This is because pediatric patients are less prone to arrhythmias with hypokalemia.
- 3. Sodium bicarbonate:** While sodium bicarbonate is recommended in adult DKA with a pH < 7.1, its use in pediatric DKA is limited to patients with cardiovascular collapse.

**Case continued:** The four-year-old boy in this case is hyperventilating. Clinically he looks mildly hypovolemic but is tolerating oral intake. Investigations are remarkable for a glucose of 22 mmol/l, pH of 7.25, and a  $\text{HCO}_3^-$  of 14 mmol/l.

**Q: How would you manage this patient?**

**A:** This child has mild DKA. Mild DKA patients can usually be managed with subcutaneous insulin in the ED. If they are able to tolerate oral fluids, they can often be treated as outpatients with subcutaneous insulin following a period of observation and close follow-up in a diabetes clinic the next day.

Children younger than five years of age will generally be admitted, as they are at higher risk for decompensating. Insulin titration may be more difficult, they may be less likely to tolerate oral fluids, and assessment of mental status changes may be more difficult.



All DKA patients should be managed in consultation with a pediatrician or pediatric endocrinologist.



## CASE 2: MODERATE DKA

A six-year-old girl presents to your ED with her parents complaining of abdominal pain with nausea and vomiting throughout the day. The patient's mother states the child looks more lethargic than normal, has not been drinking, and is making very dark urine today.

On exam, she is alert and oriented with a GCS of 15, but she appears drowsy. Vitals are: heart rate 135, respiratory rate 50, and blood pressure 89/50. Capillary refill is two seconds and the mucous membranes are dry. Chest is clear and there is no indrawing. Abdominal exam is benign.

Investigations are remarkable for a pH of 7.1, a  $\text{HCO}_3^-$  of 7 mmol/l and a potassium is 5.1 mmol/l.

**Q: What will be your next step in the management of this six-year-old lethargic child with suspected DKA?**

**A:** This patient is clearly sicker than the previous case. However, she is not in decompensated shock, as her systolic blood pressure is greater than the minimal acceptable for her age ( $70 + [2 \times \text{age}]$ ). Her pH and  $\text{HCO}_3^-$  are consistent with moderate DKA. Remember that it took a few days to develop these metabolic derangements in DKA, and there is no rush to correct them immediately. In fact, aggressive fluid and insulin boluses may increase the risk of cerebral edema. It is important to follow the DKA algorithm provided by your hospital or the [Canadian Diabetes Association](#) in consultation with your pediatrician or pediatric endocrinologist.



### **Pitfall:**

One of the common pitfalls in the management of hemodynamically stable pediatric DKA patients is employing aggressive fluid management with large boluses of saline up front. This practice increases the risk of cerebral edema.



**Q: How will you provide IV fluid rehydration for this patient?**

**A:** The fluid of choice is normal saline. This patient is not in decompensated shock and so there is no role for fluid boluses. The goal is to provide maintenance fluid and replace her deficits over 48 hours. It is very common to overestimate the degree of dehydration in DKA patients, partly because their mucous membranes will appear dry due to their tachypnea. Our experts recommend that IV fluids should be administered at no greater than twice the maintenance rate.

**Q: When will you administer insulin in this child, and at what rate?**

**A:** Insulin should be administered **after** one to two hours of intravenous fluids. A [case-control study](#) found that early administration of insulin was associated with increased risk of cerebral edema. This is the reason that insulin administration is delayed in the current guidelines. Initial insulin infusion should be between 0.05-0.1 unit/kg/hour in consultation with your pediatrician or pediatric endocrinologist. There is no role for insulin boluses in these patients, again due to an association with cerebral edema.

The metabolic derangements of DKA took one to two days to develop, and so they should be corrected over one to two days, as well.



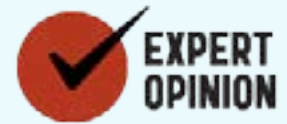**Key Reference:**

In a [U.K. case-control study](#) of cerebral edema complicating diabetic ketoacidosis in children, the researchers found that, after allowing for severity of acidosis, insulin administration in the first hour and volume of fluid administered over the first four hours were associated with an increased risk of cerebral edema.

**Q: How will you manage the potassium level of 5.1 mmol/l in this child?**

**A:** Remember that patients in DKA have a whole-body depletion of potassium due to the osmotic diuresis associated with elevated blood glucose levels. However, the potassium level in the blood will be relatively higher due to the acidosis shifting potassium stores into the blood. The administration of insulin will push potassium back into cells, which may cause hypokalemia. This puts the patients at risk of hypokalemia-induced dysrhythmias. In adult DKA patients, administration of insulin is held until the potassium is known. If the potassium is below 3.3 mmol/l, the insulin is not started until the potassium can be replaced.

Pediatric patients are less prone to dysrhythmias. The guidelines do not require one to know the potassium level prior to starting insulin. Remember that the insulin infusion should not be started until one to two hours of IV fluid has been administered. As such, it is very likely that you will have the potassium level back within the time you will be starting insulin. If the initial potassium is found to be less than 5.5 mmol/l and the patient is making urine, 40 mEq KCl should be added to your IV normal saline infusion. ECGs are not routinely indicated unless the patient is hypokalemic or hyperkalemic on the initial blood work.



While serum ketones can be used to monitor treatment, most clinicians will monitor the anion gap as a marker of ketosis and ensure that it is decreasing with treatment.

**Q: Following these initial interventions, how are you going to monitor this child to determine how to adjust further treatment?**

**A:** The DKA algorithm provided by your consultant will inform further care, but the principles of ongoing monitoring interventions in DKA are outlined below:

1. Check bedside glucose hourly
2. Check electrolytes and VBG every two hours initially
3. Add potassium to your normal saline infusion as 40 mmol KCl once serum potassium is < 5.5 mmol/l and the patient is making urine
4. Add D10W or D5W to the infusion once glucose is 14.0–17.0 mmol/l
5. Target a blood glucose of 10.0–15.0 mmol/l with a dextrose infusion

## CASE 3: SEVERE DKA AND CEREBRAL EDEMA

A two-year-old girl presents to your ED with lethargy for the past 24 hours. She has no infectious signs or symptoms and there are no sick contacts. The excellent triage nurse carries the child in her arms directly to your resuscitation room, as she is really worried about her. She looks altered and is not responding appropriately. She is very tachypneic.



Vital signs are: heart rate of 150, blood pressure 80/50, respiratory rate 44, and oxygen saturation of 96%. The capillary glucometer displays critically high readings. She is breathing rapidly and deeply, capillary refill is three to four seconds, and extremities are cool. There are no focal findings on gross neurologic exam. The blood gas reveals a pH of 7.03 and a  $\text{HCO}_3^-$  of 3 mmol/L. Your heart rate goes up.

**Q: Does this patient require an IV fluid bolus?**

**A:** This patient is in severe DKA, as evidenced by her pH and bicarbonate level. However, her blood pressure is greater than the minimal acceptable blood pressure for her age, and therefore she is not in decompensated shock. The acidosis in this patient can lead to mottling and delayed capillary refill that may cause one to overestimate the degree of dehydration in these patients. Judicious use of fluids with a maximal infusion rate of twice the maintenance still applies to this patient as in the previous case. At this point, an IV fluid bolus would not be warranted. If this patient does develop decompensated shock (defined as hypotension adjusted for age) then a normal saline bolus of 5–10 cc/kg can be administered with close monitoring to reduce the risk of excess fluid administration. Given the association of excess IV fluid administration with cerebral edema, it is important to be judicious with fluid administration.



### **Clinical Pearl:**

If you have a patient with DKA with altered mental status, presume they have cerebral edema. Administration of mannitol or hypertonic saline should be strongly considered.

**Q: What diagnosis would you consider given this patient's altered mental status? How will you manage this?**

**A:** This patient is presenting with altered mental status in the presence of severe DKA. The possibility of cerebral edema must be considered. In addition to the previously stated care plan, it would be prudent to:

1. Elevate the head of the bed to 30 degrees to help decrease raised ICP
2. Prepare mannitol and/or 3% hypertonic saline
3. Call your regional referral centre, as this patient will require admission to a pediatric ICU

**Case continued:** The patient is given a 400 ml bolus of normal saline as well as an IV insulin bolus. The nurse calls you back to the bedside because the child is now stuporous and incontinent of urine. Her heart rate has decreased from 150 to 90 beats per minute, and her blood pressure has increased to 140/10 mmHg.

**Q: What is the likely cause of this sudden decrease in heart rate and increase in blood pressure?**

**A:** This child is likely suffering from cerebral edema with a significantly raised intracranial pressure resulting in a Cushing reflex.

**Q: What are the risk factors for cerebral edema in DKA?**

**A:** Cerebral edema is a rare but devastating complication of DKA. Risk factors for the development of DKA can be divided into patient-related and treatment-related. These risk factors are summarized in the table below. Note that these are only associations only, derived mostly from retrospective studies. The pathogenesis of cerebral edema in DKA is quite controversial. Theories attributing it to aggressive insulin and fluid administration describe increased intracellular sodium, with the forcing of water into brain cells a possible mechanism. Alternatively, cerebral hypoperfusion from dehydration and acidosis in DKA, causing cytogenic edema, has been proposed. Certainly, patients in severe DKA can present to the ED already with signs of cerebral edema, so it is unlikely it is a phenomenon caused exclusively by overzealous insulin and IV fluid administration.

**Risk Factors for Cerebral Edema in DKA**

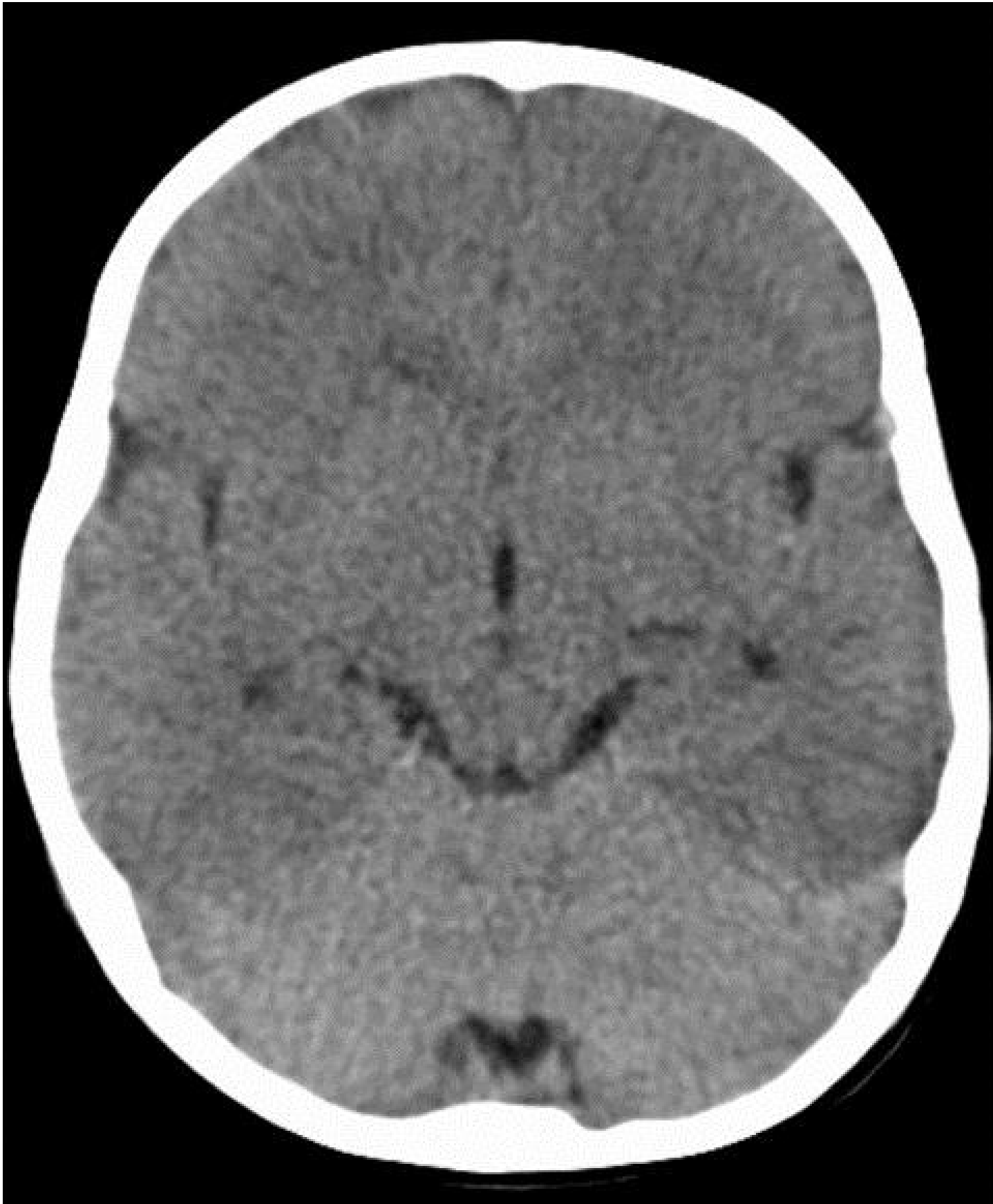
Risk Factors for Cerebral Edema	
Patient related	Children < 5 New onset diabetes Late presentation (longer symptoms, more acidic pH)
Treatment related	Administration of large amounts of fluids Administration of hypotonic fluids Early administration of insulin Administration of sodium bicarbonate Bolusing IV insulin

**Q: What are your immediate steps in the management of this patient who is now showing signs of cerebral edema with raised intracranial pressure (ICP)?**

**A:** The patient's mental status has declined and she now has signs of increased ICP, as suggested by her hypertension and bradycardia, both part of the Cushing reflex of increased ICP. The head of the bed should be elevated to 30 degrees. Administer mannitol 0.5–1 g/kg over 20 minutes and/or 3% hypertonic saline 5-10 cc/kg IV over 30 minutes. Hypertonic saline has the theoretical benefit of preventing hyponatremia as well as preventing hypovolemia caused by mannitol-induced osmotic diuresis. However, there is no strong clinical evidence in the pediatric population to support one agent over the other.



A head CT can be considered to evaluate for increased ICP, but only after the patient has stabilized. In fact, CT findings of cerebral edema usually lag behind clinical symptoms, so management should proceed based on clinical signs of cerebral edema.



Head CT showing loss of sulci indicative of raised intracranial pressure

**Q: Will you give this patient sodium bicarbonate for her severe acidosis?**

**A:** While sodium bicarbonate therapy has not been demonstrated to show clinical benefit in adult DKA patients, guidelines suggest considering it in patients with a pH < 7.0. This is not the case for pediatric DKA patients. There is no evidence of benefit for this therapy in pediatric DKA patients and there is a weak association with cerebral edema. Administration of sodium bicarbonate should be limited to the pediatric patient who is in cardiovascular collapse.

**Q: If the patient becomes comatose and requires intubation, what issues would you need to consider?**

**A:** Intubation of the severe DKA patient is a very risky procedure and should ideally be done in consultation with a pediatric intensivist. The tachypnea of DKA patients serves to release large amounts of CO<sub>2</sub> as a respiratory compensation for the severe metabolic acidosis. Prolonged apnea during intubation and hypoventilation post-intubation can cause accumulation of CO<sub>2</sub> in the blood, rapidly worsening acidosis and possibly precipitating a cardiac arrest. Prior to intubation, it is important to note the patient's pCO<sub>2</sub> as this should be your target following intubation.



**Clinical Pearl:**

Administration of sodium bicarbonate in pediatric DKA should be limited to the patient who is in cardiovascular collapse.



**Pitfall:**

Prior to intubation, it is important to note the patient's pCO<sub>2</sub> as this should be your target following intubation.

**Q: The patient in this case is clearly quite sick and will be admitted to a pediatric ICU. What factors should guide disposition of DKA patients?**

**A:** General criteria for ICU admission in DKA are:

1. pH < 7.1 or HCO<sub>3</sub> < 5 mmol/l
2. Age younger than two years old
3. Any concern for cerebral edema

As mentioned before, patients with mild DKA who are older than five years of age and are tolerating oral fluids can be considered for discharge from the ED if they are otherwise well, have clear follow-up instructions, and have reliable caregivers.

**FOAMed link:** [For a full pdf of the bottom line recommendations from TREKK, click here.](#)



### Comments?

[Click here to leave a comment or to listen to this podcast](#)

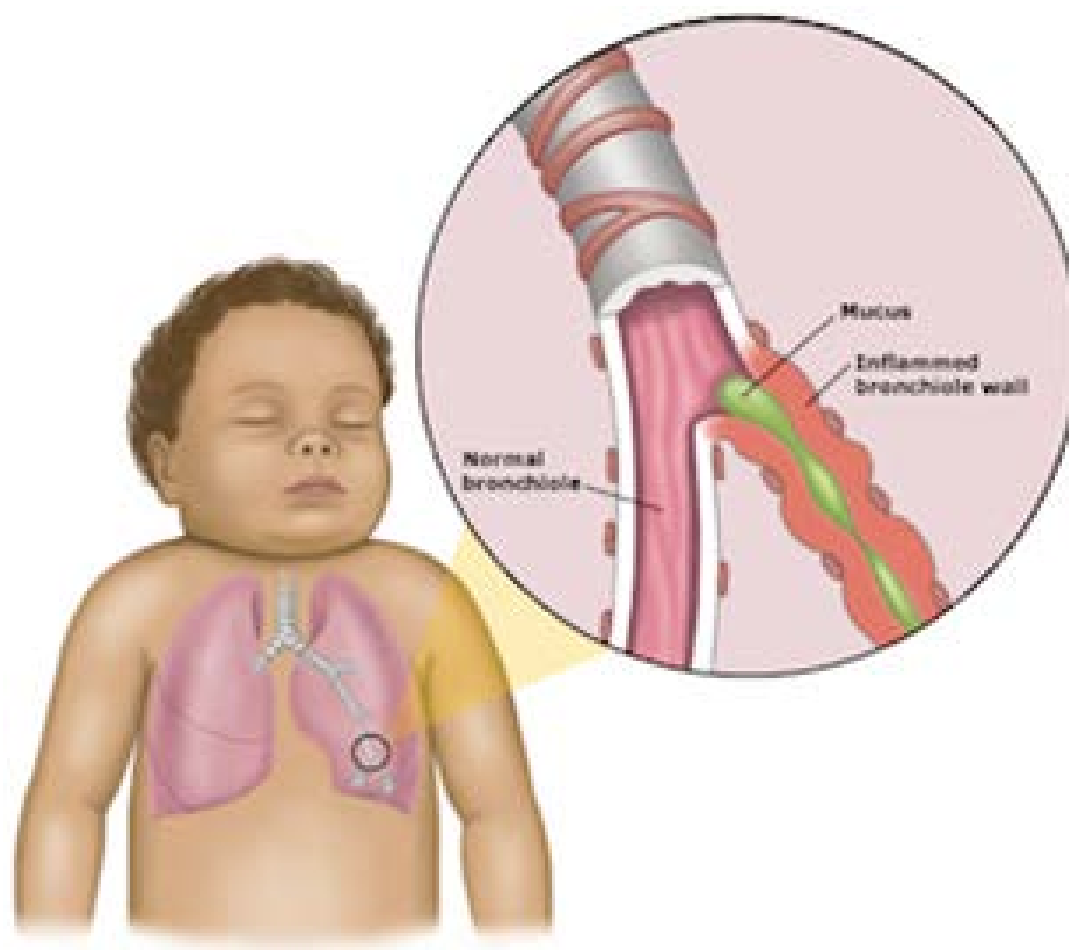
## KEY REFERENCES:

1. Edge JA, Jakes RW, Roy Y, et al. The UK case-control study of cerebral oedema complicating diabetic ketoacidosis in children. *Diabetologia*. 2006; Sep;49(9):2002-9.
2. Koves IH, Neutze J, Donath S, et al. The accuracy of clinical assessment of dehydration during diabetic ketoacidosis in childhood. *Diabetes Care*. 2004; Oct;27(10):2485-7.
3. Levin DL. Cerebral edema in diabetic ketoacidosis. *Pediatr Crit Care Med*. 2008; May;9(3):320-9.
4. Ma OJ, Rush MD, Godfrey MM, Gaddis G. Arterial blood gas results rarely influence emergency physician management of patients with suspected diabetic ketoacidosis. *Acad Emerg Med*. 2003; Aug;10(8):836-41.
5. Sheikh-ali M, Karon BS, Basu A, et al. Can serum beta-hydroxybutyrate be used to diagnose diabetic ketoacidosis?. *Diabetes Care*. 2008; Apr;31(4):643-7.
6. TREKK. Bottom Line Recommendations: Diabetic Ketoacidosis. 2014. [http://cme02.med.umanitoba.ca/assets/trekk/assets/attachments/39/original/Bottom\\_Line\\_Summary\\_DKA.pdf?1415132311](http://cme02.med.umanitoba.ca/assets/trekk/assets/attachments/39/original/Bottom_Line_Summary_DKA.pdf?1415132311).
7. Wherrett D, Huot C, Mitchell B, Pacaud D. Type 1 diabetes in children and adolescents. *Can J Diabetes*. 2013; Apr;37:Suppl 1:S153-62.
8. Wolfsdorf JI, Allgrove J, Craig ME, et al. Diabetic ketoacidosis and hyperglycemic hyperosmolar state. *Pediatr Diabetes*. 2014; Sep;15(20):154-79.

# CHAPTER 12: BRONCHIOLITIS

[LISTEN TO THE PODCAST WITH DENNIS SCOLNIK AND SANJAY MEHTA HERE](#)

[LISTEN TO THE BONUS BRONCHIOLITIS PODCAST WITH AMY PLINT HERE](#)



## Objectives

1. Develop an approach to the clinical exam of a patient with respiratory distress
2. Learn how to distinguish between bronchiolitis, asthma and pneumonia clinically
3. Know which investigations are necessary for children with bronchiolitis
4. Develop an approach to the management of bronchiolitis with an understanding of the evidence supporting various treatment modalities
5. Learn which children with bronchiolitis require admission



## CASE 1: DIFFICULTY BREATHING

A six-month-old girl is brought to the emergency department by her parents because the child is having difficulty breathing. She's had a cough and runny nose for the past three days and gradually increasing shortness of breath since the previous evening. This is her second ED visit.

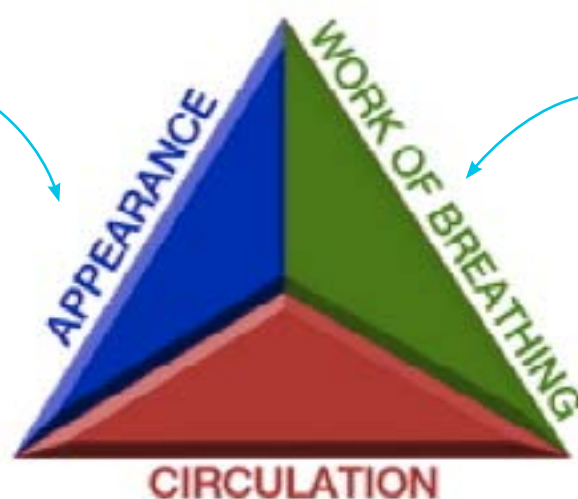
On the first visit she was treated with ibuprofen and nebulized salbutamol, and sent home. Her past history reveals that she was an uneventful delivery with no NICU admission and no history of reactive airways. She is otherwise healthy. Both her mother and father had asthma when they were children.

**Q: As you are about to start your physical exam, you recall the Pediatric Assessment Triangle and go through in your head all its components to help guide your exam and to determine how “sick” this child is. What are the important aspects of the Pediatric Assessment Triangle that can help you out when faced with a six-month-old child with respiratory distress in front of you?**

**A:** Use the ABCs of the Pediatric Assessment Triangle:

### Appearance:

- Tone
- Interactiveness
- Consolability
- Look/gaze
- Speech/cry



### Work of Breathing:

- Respiratory rate
- Abnormal breath sounds
- Retractions
- Tripod position
- Nasal flaring

### Circulation:

- Pallor
- Mottling
- Cyanosis



### Clinical Pearl:

It is also important to assess the hydration status of a child who presents to the ED in respiratory distress. An increased respiratory rate with nasal congestion can impair feeding ability and lead to dehydration. Ask about the number of wet diapers, check the mucus membranes, look for sunken eyes, and assess cap refill and skin turgor.

**Case continued:** The patient's vitals are: heart rate 150, respiratory rate 55, oxygen saturation 95% on room air, and a temperature 38.4°C. On exam, the patient is alert and does not appear toxic, but is in moderate respiratory distress with tracheal tugging and intercostal indrawing. Auscultation reveals bilateral diffuse biphasic wheezes with no crackles. Mucous membranes are moist, anterior fontanelle is flat, and capillary refill is one second. The rest of the exam is unremarkable.

**Q: This six-month-old child seems to be working pretty hard to breathe. What is the upper limit of normal respiratory rate for a six-month old?**

**A:**



### Upper Limit of Normal Respiratory Rate:

- |                 |                   |
|-----------------|-------------------|
| • Term neonate  | 50 breaths/minute |
| • Six-month-old | 40 breaths/minute |
| • 12-month-old  | 30 breaths/minute |

**Q: You're thinking that this child likely has reactive airways disease—either an asthma-type illness, since both her parents were asthmatics, or bronchiolitis, which you know is the most common lower respiratory tract infection in those younger than two years of age and one of the leading causes of hospital admission in those under six months of age. Or could this be pneumonia?**

**You wonder, how does one tell the difference between asthma, pneumonia, and bronchiolitis clinically, at the bedside?**

**A:** Bronchiolitis may present in the “classic” fashion with a first-time wheezing episode in the first year of life between the months of November and April in northern climates. Bronchiolitis usually begins with a two- or three-day viral prodrome of fever, cough, and runny nose, which progresses to tachypnea, wheeze, crackles, and a variable degree of respiratory distress, usually with a decreased oxygen saturation. It usually lasts about 10 days, with the severity increasing over the first three to five days.

However, often it is not possible to distinguish bronchiolitis from asthma or pneumonia at first contact because their presentations may overlap.

Children with asthma usually presents with recurrent wheezing in a child younger than two years old with a personal and/or family history of atopy or asthma. Response to beta-agonists may help to differentiate bronchiolitis from asthma, as typically patients with bronchiolitis do not show any improvement following beta-agonist administration, whereas asthma patients typically do.

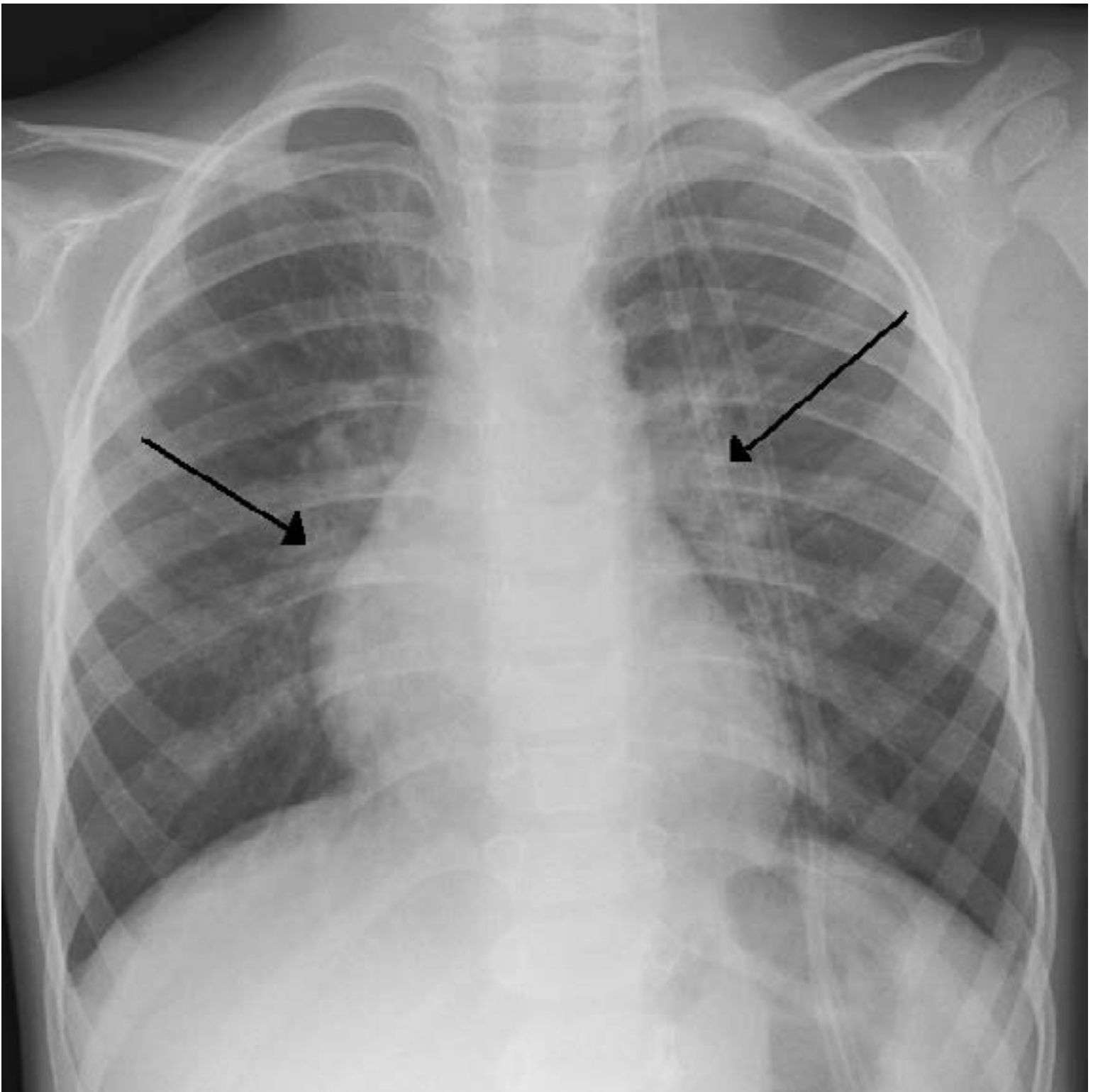
Children with bacterial pneumonia often appear “toxic” and tend to have higher-grade fevers than those found in bronchiolitis. They may have focal chest findings and usually do not have wheeze.

**Q: This six-month-old girl’s parents are quite anxious, and they want to know if you are going to order a chest X-ray. Is this necessary?**

**A:** In our case, a chest X-ray is not necessary. Chest X-ray findings of bronchiolitis are often non-specific.

They may show hyperinflation, perihilar fullness (see below), and areas of atelectasis that are often misinterpreted as a consolidation and lead to inappropriate antibiotic use.

However, one should consider a chest X-ray when the diagnosis is unclear or pneumonia is suspected due to severe respiratory distress, focal lung findings on clinical exam or unexpected response to treatment.



Perihilar fullness seen on chest X-ray in a child with bronchiolitis



### Key Reference:

The American Association of Pediatricians' (AAP) *Clinical Practice Guideline: The Diagnosis, Management, and Prevention of Bronchiolitis* states: "Clinicians should diagnose bronchiolitis and assess disease severity on the basis of history and physical examination. Clinicians should not routinely order laboratory and radiologic studies for diagnosis."

**Q: The nurse asks you if you would like him to swab the nose of this six-month-old child for respiratory syncytial virus (RSV). While your reflex answer is ,“Sure, why not?” you’re actually not sure if there is any value in RSV swabs for patients who present to the emergency department with suspected bronchiolitis. Is there any value in doing an RSV swab for this patient?**

**A:** There is no need to do an RSV swab for this patient. Bronchiolitis is a clinical diagnosis and a swab will not change the management. However, there are certain populations for whom you may consider doing a swab, such as those who were a premature delivery, recently discharged from hospital, are immunocompromised, or are ventilated.

**Q: The parents say their daughter’s nasal congestion has been much worse over the past 24 hours, and that they read online that they should be doing nasal suctioning. They ask, “What are your thoughts about this?”**

**A:** A trial of gentle nasal suctioning in the ED is reasonable. This is especially true for younger children because they are obligate nose breathers. Nasal suctioning may relieve some of the upper airway obstruction and reduce the patient’s work of breathing. However, the evidence for nasal suctioning is unclear, with one study showing that in-hospital suctioning actually increased length of stay.



**Q: The parents hear the word “wheezy” and remind you that they both had asthma as a child. Should this child be treated with inhaled bronchodilators?**

**A:** Both the literature and recent guidelines report minimal evidence of benefit for bronchodilators in bronchiolitis. Studies have shown improvement in clinical scores but have not been shown to improve oxygen saturation, admission rates, or length of stay. If a trial of salbutamol is going to be attempted, the clinician should objectively assess the work of breathing before and after its administration and continue therapy only if a clinical benefit is noted.



**Q: Is there a role for nebulized epinephrine in children suspected of bronchiolitis in the emergency department?**

**A:** There is some evidence to suggest that nebulized epinephrine may provide short-term benefit, but it may ultimately delay the need for admission.

Nebulized epinephrine may be considered in patients in whom you suspect admission will be the likely disposition. If there is going to be a trial of nebulized epinephrine, our experts suggest you monitor the patient objectively for benefit of treatment to guide further management.

**Q: Would this six-month-old child with suspected bronchiolitis benefit from oral steroids? What about the combination of oral steroids and nebulized epinephrine?**

**A:** Corticosteroids alone are not recommended in bronchiolitis. Both a 2013 Cochrane Review and a 2014 systematic review in *Annals of Emergency Medicine* showed no benefit of oral steroids with respect to length of stay and admission rates for children with bronchiolitis.



Our experts recommend considering a trial of salbutamol for patients in whom there is a strong family history of asthma, atopy or in the patient who has had multiple wheezing episodes. Ipratropium should be reserved for asthmatic patients and not used in bronchiolitis.



**Key Reference:**

A Cochrane Review in 2011 found that nebulized epinephrine reduced admission rates on day one; however, there was no difference in hospitalization rates at day seven when compared with placebo.



**Key Reference:**

The evidence for the combination of oral steroids with nebulized epinephrine is equivocal. A large randomized control trial by Plint et al. demonstrated a trend toward decreased admission rates for children treated with a combination of oral steroids and nebulized epinephrine. However, some experts believe the clinical significance of this difference was very small, and therefore do not recommend this treatment routinely.

**Q: In between seeing patients, you stop to chat with one of your colleagues. You tell him about the six-month-old with difficulty breathing, and he asks if you tried hypertonic saline. You had never heard of using hypertonic saline before and wonder whether it is worth trying. You figure it's probably pretty harmless, and if it might benefit your patient, then great! Is there a role for nebulized hypertonic saline in bronchiolitis management?**

**A:** Once again, the evidence is equivocal for the use of hypertonic saline in the ED. There is evidence for its use in hospitalized patients, in whom it has been shown to reduce length of stay and severity scores. However, the benefits are short term and have not been shown to consistently reduce rates of admissions or improve oxygenation. Our experts view this treatment as a temporizing measure for a patient who is going to be admitted and not as a rescue manoeuvre.

**Q: Given the lack of good evidence for benefit for most treatment modalities, what is your approach to the management of patients with bronchiolitis?**

**A:**



1. Correct hypovolemia
2. Treat hypoxemia if the oxygen saturation is less than 90%
3. Treat fever for comfort
4. Do serial assessments to determine the need for further interventions
5. Consider a trial of salbutamol if there is a history of atopy or a family history of asthma or atopy
6. If admission is anticipated, consider a trial of epinephrine and/or hypertonic saline
7. If showing signs of severe respiratory distress, high-flow oxygen is an option (see Case 3)



## Management of Bronchiolitis:

Adapted from [The Canadian Paediatric Society Guidelines for Bronchiolitis, 2014](#)



### Recommended treatments

1. Oxygen
2. Hydration



### Evidence equivocal

1. Nebulized epinephrine
2. Nasal suctioning
3. Nebulized 3% saline
4. Combined epinephrine and dexamethasone



### Not recommended

1. Salbutamol
2. Steroids
3. Antibiotics
4. Cool mist therapies

**Q: After the child has received nasal suctioning, oxygen, and fluids, you reassess this child who now appears to be well, with no respiratory distress and normal vital signs except for an oxygen saturation of 92%. Does this child with presumed bronchiolitis require admission to hospital?**

**A:**



### Key Reference:

One study of otherwise healthy infants between the ages of four weeks to 12 months, with mild to moderate bronchiolitis and true oxygen saturations of 88% or higher, were randomized to pulse oximetry measurements with true saturation values displayed or with altered saturation values displayed that had been increased three percentage points above the true values.

The primary outcome was hospitalization within 72 hours, defined as inpatient admission within this interval or active hospital care for greater than six hours.

They found that those with an artificially elevated pulse oximetry reading were less likely to be hospitalized within 72 hours or to receive active hospital care for more than six hours than those with unaltered oximetry readings. This suggests that oxygen saturation should not be the only factor in the decision to admit, and its use may need to be re-evaluated.

---

## **CASE 2: AN INFANT WITH FEVER & BRONCHIOLITIS**

A seven-week-old female is brought to the emergency department by her parents with a two-day history of fever, runny nose, and cough. She is previously healthy with an uncomplicated delivery.

On exam, her vitals are: heart rate 140, respiratory rate 60, oxygen saturation 97% on room air, and a temperature of 38.5°C. She is alert and interactive. She has intercostal indrawing and bilateral expiratory wheeze on auscultation. She appears well hydrated. The rest of the exam is non-contributory.

**Q: In this seven-week-old infant who is presenting with a clinical picture consistent with bronchiolitis, you wonder whether there might be a concurrent bacterial infection, which would require a change in management. What is the risk of her also having a serious bacterial infection?**

**A:** Approximately 5% to 10% of infants with bronchiolitis will have a concurrent serious bacterial infection, most commonly a urinary tract infection.

**Q: Knowing that 5% to 10% of infants with bronchiolitis will have a concurrent serious bacterial infection, you wonder how to decide which children with bronchiolitis require a workup for a serious bacterial infection. Should you work up this seven-week-old infant?**

**A:** Strongly consider obtaining a urinalysis for all infants who present with fever and bronchiolitis. All infants from birth to 28 days of age with a fever require a full septic workup and should be started on empiric IV antibiotics, regardless of any suspicion for bronchiolitis. All febrile infants who display signs of septic shock or impending septic shock should also have a full septic workup and be started on empiric IV antibiotics.



**Q: When you go to reassess this infant, her mother tells you she thinks her baby may have stopped breathing for a few seconds in the ED. Is this seven-week-old female at risk for apnea with her bronchiolitis? Can the risk be predicted?**

**A:** Yes, she is at increased risk because she is younger than two months of age. The overall incidence of apnea in children with bronchiolitis is 2.7%. Risk factors for apnea with bronchiolitis include:

- Age younger than 2 months
- Small for gestational age (weight < 2.3 kg)
- Previous episode of apnea
- Oxygen saturation < 90%



## CASE 3: FEVER AT THREE MONTHS OF AGE

A three-month-old male is brought in to the emergency department by his parents with a three-day history of runny nose and cough. He has felt warm at home. Over the past 24 hours his parents have noticed that he is not acting himself, has decreased feeding, and increased work of breathing. He is previously healthy and was born at term with an uncomplicated delivery.

On exam, his vitals are: heart rate 160, respiratory rate 70, oxygen saturation 89% on room air, and a temperature of 38.1°C. He is not very interactive. He is working hard to breathe with tracheal tugging, nasal flaring, and intercostal indrawing. On auscultation, you hear a bilateral diffuse biphasic wheeze with no crackles. His mucus membranes are dry and his capillary refill is three seconds. The rest of the exam is non-contributory.

**Q: For this child who is presenting with more severe respiratory distress, what additional treatments will you consider in addition the medications discussed in Case 1?**

**A:** There is conflicting evidence for the use of CPAP and high-flow nasal cannula for respiratory failure in bronchiolitis. However, our experts recommend the use of warmed, humidified high-flow oxygen by facemask for children with bronchiolitis who are in severe respiratory distress.



High-flow oxygen may not be tolerated by all patients, but in those who are showing signs of fatigue and in whom you are considering intubation, it may play a role. High-flow oxygen by facemask provides positive end expiratory pressure (PEEP) and allows the delivery of a high concentration of oxygen.

While ketamine is an option in these patients, it is not recommended by our experts unless it is going to be used in as an induction agent for tracheal intubation. While it may have benefit in asthmatic patients due to its broncho-dilatory properties, bronchoconstriction is not thought to play a significant role in bronchiolitis, and thus ketamine is unlikely to be of benefit.

**FOAMed link:** [For more on high-flow oxygen for bronchiolitis, check out this PEM Currents podcast.](#)

**Q: After receiving nasal suctioning, nebulized epinephrine, dexamethasone, and high-flow oxygen, this child who presented in severe respiratory distress improves substantially. When you go to reassess him, he looks great! You wonder whether this child can go home with good discharge instructions. What are the criteria for admission for a child with bronchiolitis according the Canadian Paediatric Society 2014 guidelines?**

**A:**  **Admission criteria for bronchiolitis:**

1. Signs of severe respiratory distress (i.e., indrawing, grunting, or respiratory rate > 70)
2. Supplemental oxygen required to keep saturations above 90%
3. Dehydration or history of poor fluid intake
4. Cyanosis or history of apnea
5. Family unable to cope
6. Infant at high risk for severe disease (born at less than 35 weeks gestation, younger than three months old, hemodynamically significant cardiopulmonary disease, immunodeficiency)



### **Clinical Pearl:**

Bronchiolitis symptoms peak around days three to five. If the patient presents on day two, you can expect the patient may get worse before they get better. This should be factored into your disposition decision. Also, 50% of patients who develop severe disease do so after their first ED visit, so clear discharge instructions are very important.



### **Comments?**

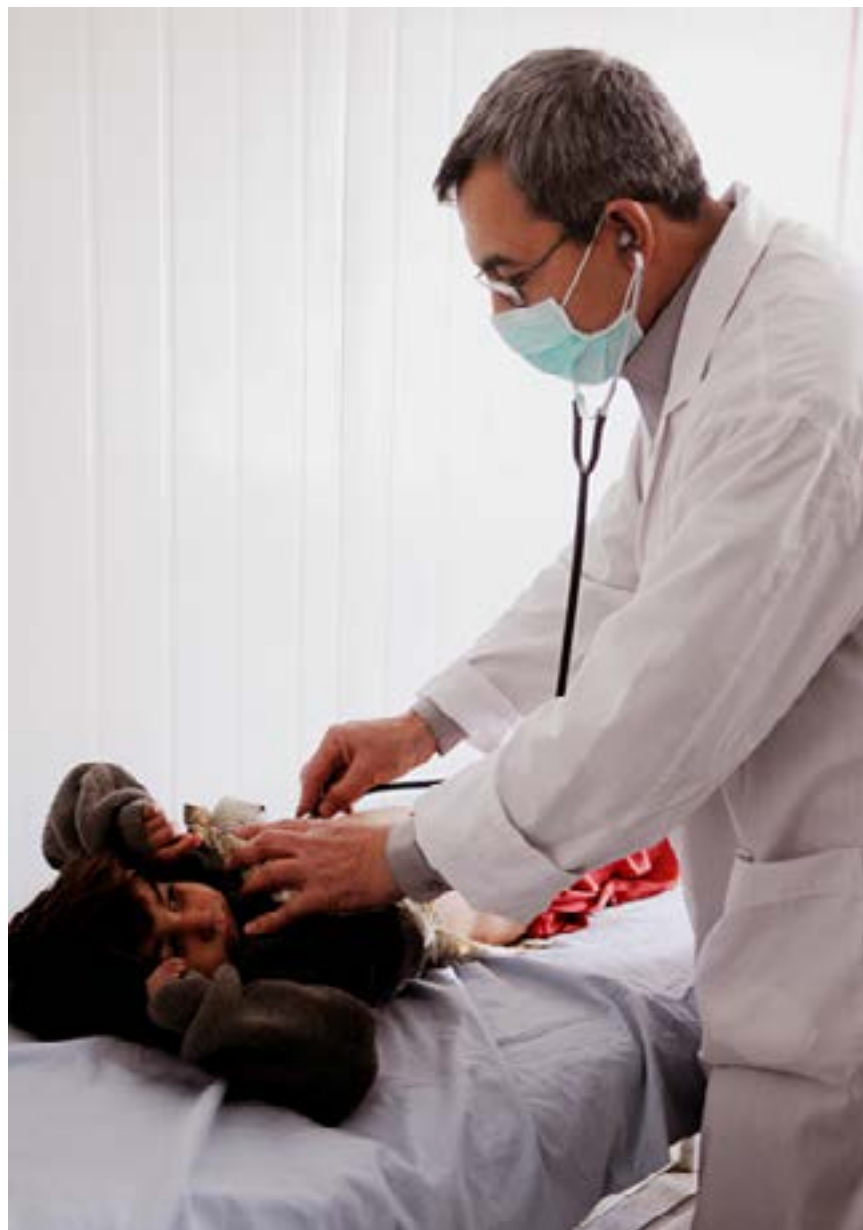[Click here to leave a comment or to listen to this podcast.](#)

## KEY REFERENCES:

1. Ecochard-Dugelay E, Beliah M, Perreaux F, et al. Clinical predictors of radiographic abnormalities among infants with bronchiolitis in a paediatric emergency department. *BMC Pediatr*. 2014; Jun;14:143.
2. Fernandes RM, Bialy LM, Vandermeer B, et al. Glucocorticoids for acute viral bronchiolitis in infants and young children. *Cochrane Database Syst Rev*. 2013; Issue 6.
3. Friedman JN, Rieder MJ, Walton JM, Canadian Paediatric Society, Acute Care Committee, Drug Therapy and Hazardous Substances Committee. Bronchiolitis: Recommendations for diagnosis, monitoring and management of children one to 24 months of age. *Pediatr Child Health*. 2014; Nov;19(9):485-498.
4. Hartling L, Bialy LM, Vandermeer B et al. Epinephrine for Bronchiolitis (Review). *Cochrane Database Syst Rev*. 2011; Issue 6.
5. Plint AC, Johnson DW, Patel H, et al. Epinephrine and dexamethasone in children with bronchiolitis. *N Engl J Med*. 2009; May;360(20):2079-2089.
6. Ralston SL, Lieberthal AS, Meissner HC, et al. Clinical practice guideline: The diagnosis, management and prevention of bronchiolitis. *Pediatrics*. 2014; Nov;134(5):e1474-1502.
7. Ng C, Foran M, Koyfman A. Do glucocorticoids provide benefit to children with bronchiolitis? *Ann Emerg Med*. 2014; Oct;64(4):389-91.
8. Schuh S, Freedman S, Coates A, et al. Effect of oximetry on hospitalization in bronchiolitis: a randomized clinical trial. *JAMA*. 2014; Aug;312(7):712-8.

# CHAPTER 13: ASTHMA

[LISTEN TO THE PODCAST WITH DENNIS SCOLNIK AND SANJAY MEHTA HERE](#)



## Objectives

1. Determine the severity of asthma to guide ED management
2. Distinguish asthma from common asthma mimics
3. Understand the evidence for various treatments for acute asthma exacerbations
4. Understand the dangers of endotracheal intubation in patients with severe asthma
5. Know the discharge and hospital admission criteria for pediatric asthma

## CASE 1: HISTORY OF ASTHMA

A 10-year-old boy with a history of asthma is triaged to the acute area of your ED with a seven-day history of shortness of breath. Today, during recess at school, he suddenly became much more short of breath and his inhaler was empty from using it the day before. EMS brought the child to your ED. On arrival he appears alert but tachypenic, with nasal flaring and accessory muscle use. He's able to speak in single-word phrases. His respiratory rate is 40, heart rate is 140, oxygen saturation is 88% on room air, and temperature is 37.4°C. His chest is silent.



**Q: You are taking a quick history and you're wondering about how severe his asthma has been in the past. What historical features would make you more worried that this child has severe asthma and that he is at high risk for deterioration in the ED?**

**A:**

- Previous life-threatening exacerbations
- Admissions to ICU
- Intubation
- Deterioration while on systemic steroids
- Using more than two canisters of short-acting beta-agonist per month
- Cardiopulmonary and psychiatric comorbidities





**Pitfall:**

A common pitfall is to assume that the lack of risk factors means that the patient is low risk for deterioration. It is important to realize that a lack of risk factors does not necessarily confer a lack of risk. In the absence of the risk factors above, asthmatic patients may still have a severe disease course and deteriorate in the ED.

**Q: Although you think this is likely an asthma exacerbation, what are some other possible diagnoses or mimics, and how do you distinguish them from asthma?**

**A:**

- 1. Bronchiolitis:** Low-grade fever, wheeze tends to sound harsher and less melodious; for more on bronchiolitis, [jump to Chapter 12](#)
- 2. Airway FB:** Symptomless period followed by paroxysms of respiratory distress, choking, recurrent or unresolving pneumonia, unilateral wheeze, failure to improve with asthma therapies.
- 3. Tracheomalacia:** Usually within first two months of life, strong inspiratory component, no improvement with asthma meds—may even cause worsening
- 4. GERD:** Incidence among patients with asthma is as high as 48%; heartburn, regurgitation, dysphagia
- 5. Pneumonia:** Toxic appearing, respiratory distress, febrile, crackles

**Q: Now that you've considered alternative conditions, you really do believe this is an asthma exacerbation. You look up clinical assessment tools for pediatric asthma to help guide you. These are the Pediatric Respiratory Assessment Measure (PRAM) and Pediatric Asthma Severity Score (PASS). How useful are these scores in predicting severity?**



### Key Reference:

Birken et al. compared the performance of various assessment tools and concluded the **Clinical Assessment Score** and the **Pediatric Respiratory Assessment Measure (PRAM)** both reliably assess the severity of an acute asthma exacerbation and are sensitive to changes in clinical status.

The Pediatric Asthma Severity Score (PASS), based on three clinical findings (wheezing, prolonged expiration, and work of breathing), is a reliable and valid measure of asthma severity in children and shows both discriminative and responsive properties.

### Pediatric Respiratory Assessment Measure (PRAM)

Emergent & Urgent Care Asthma Clinical Score (PRAM)*				
Signs	0	1	2	3
Suprasternal Indrawing	absent		present	
Scalene Retractions	absent		present	
Wheezing	absent	expiratory only	inspiratory and expiratory	audible without stethoscope/silent chest with minimal air entry
Air entry	normal	decreased at bases	widespread decrease	absent/minimal
Oxygen saturation on room air	> 93%	90% - 93%	< 90%	

Severity Classification	PRAM CLINICAL Score
Mild	0 - 4
Moderate	5 - 8
Severe	9 - 12
Impending Respiratory Failure	12+ following lethargy, cyanosis, decreasing respiratory effort, and/or rising pCO <sub>2</sub>

\*Modified to adjust for higher altitude  
Chalut D, Ducharme F, Davis G *Journal of Pediatrics* 2000;137:762-768

**JUNE 2008**

### Pediatric Asthma Severity Score (PASS)

**TABLE 1. Clinical Findings Assessed**

Clinical Finding	Definition	0	1	2
Wheezing	High-pitched expiratory sound heard by auscultation	None or mild	Moderate	Severe wheezing or absent wheezing due to poor air exchange
Air entry*	Intensity of inspiratory sounds by auscultation	Normal or mildly diminished	Moderately diminished	Severely diminished
Work of breathing	Observed use of accessory muscles, retractions, or in-breathing	None or mild	Moderate	Severe
Prolongation of expiration	Ratio of duration of expiration to inspiration	Normal or mildly prolonged	Moderately prolonged	Severely prolonged
Tachypnea	Respiratory rate above normal for age	Absent	Present	
Mental status	Observation of the child's state of alertness	Normal	Depressed	

**Q: What are some other tools you can use to help assess your patient's disease and severity?**



You can use peak expiratory flow to help exclude asthma mimics. An improvement by 15% or more in peak expiratory flow after bronchodilator therapy is very suggestive of reactive airways disease or asthma in children (most reliable in children 10 years and older).

You may also consider obtaining a blood gas. A venous blood gas (VBG) is adequate. Metabolic acidosis is an indicator of impending respiratory arrest. A VBG, however, is rarely indicated unless the patient has no clinical improvement despite maximal treatment. It is reserved for measuring the degree of respiratory acidosis and hypercapnea and may be most useful as a baseline after treatment in the ED for the patient who will be admitted to the ICU.

A  $\text{PaCO}_2 > 42$  is indicative but not diagnostic of a severe exacerbation.

A  $\text{PaCO}_2 > 50$  is a risk factor for impending respiratory failure.



**Caution:**

Peak expiratory flow should NOT be relied upon solely as a measure of severity or as a sole determinate for discharge.



**Clinical Pearl:**

A normal partial pressure of  $\text{CO}_2$  in a patient with extreme tachypnea and retractions could indicate impaired ventilation and impending respiratory failure.

**Q: What about ordering imaging studies? Are there indications for a chest X-ray in patients with wheezing?**

**A:** You may want to consider obtaining a chest X-ray if the patient has:

- Focal chest findings
- Fever
- Extreme distress
- Subcutaneous emphysema
- History of choking

No sets of predictors have been found to accurately identify children likely to have abnormalities on chest radiograph. Chest X-rays are not recommended for all wheezing in children. Upon reassessment after treatment, you may find that the initial clinical focal findings have resolved, obviating the need for a chest X-ray. This approach is cost-effective, limits radiation, and limits unnecessary antibiotic use.

**Q: You have ordered your peak expiratory flow and used your clinical score. You are now even more confident that this is asthma and, given his condition, you want to start treatment right away. You are going to start with beta-agonist therapy. How will you deliver this treatment?**

**A:** Compared with nebulized treatments, a metered-dose inhaler (MDI) with a spacer use has been shown to be equally effective for children of all ages with a wide range of illness severity and by multiple outcome measures. Among children one to four years old, using an MDI with a spacer was associated with a greater reduction in wheezing and a lower hospitalization rate in one study. Furthermore, a recent cost analysis determined that the use of MDIs to treat children with mild to moderate asthma exacerbations in the ED could yield significant cost savings compared with nebulized treatments. MDIs with a spacer should not be used in patients with impending respiratory failure, and it can be difficult to coordinate breathing with administration of the inhaler for patients younger than one year old.



With respect to nebulized treatments, there is no need to coordinate the treatment with breathing, and bronchodilators can be given concurrently with anticholinergics and humidified oxygen. The downsides to using nebulized treatments are that only about 10% of the drug reaches the small airways and they may increase the spread of airborne infections.

IV beta-agonists have not been shown to be superior to inhaled beta-agonists. IV beta-agonists should be considered in those who are unable to tolerate nebulized or MDI treatments.



### **Salbutamol Dosing:**

- For patients who weigh less than 15 kg, use Salbutamol MDI four puffs or 2.5 mg nebulized + 3 ml NS.
- For patients who weight more than 15 kg, use Salbutamol MDI eight puffs or 5 mg nebulized + 3 ml NS.

**Q: Will you use the nebulized treatments intermittently (every 15 minutes) or continuously?**



**A:** A Cochrane systematic review found that those treated with continuously nebulized bronchodilators had lower rates of hospitalization, greater improvements in pulmonary function test results, and similar rates of adverse events compared with those treated intermittently. Continuous treatment allows greater compliance with the goal of delivering the equivalent of three intermittent bronchodilator treatments in the first hour of care. In addition, this method will result in less respiratory therapy time and costs; it has been shown to be safe, and it may benefit the sickest patients the most. On the other hand, young children may not tolerate a face mask for prolonged periods.



### **Caution:**

In children receiving multiple beta-agonist treatments, watch for hypokalemia, especially if the patient has diarrhea or is on diuretic medications.



**Q: You have started your beta-agonist therapy and are waiting optimistically for an improvement in your patient. What are some other treatments you can give to your pediatric patient in the meantime?**



**A:** Ipratropium-bromide! Beta-agonists with ipratropium bromide are more effective than beta-agonists alone. In a large, double-blind randomized controlled trial, three doses of ipratropium bromide administered concurrently with the first three beta-agonist treatments were shown to be superior to just one dose of ipratropium bromide. In a systematic review and meta-analysis comparing the use of beta-agonists plus anticholinergics with beta-agonists alone among children older than 18 months combination therapy was associated with significantly **lower hospitalization rates** and **improvements in asthma scores and pulmonary function test results**. These investigators concluded that multiple doses of ipatropium bromide added to beta-agonists should be standard treatment for children with moderate to severe asthma exacerbations. However, there are no clinical trials supporting ipratropium use beyond the **first hour** in children.

**Q: What added benefit do steroids such as prednisone or dexamethasone have over beta-agonists and ipratropium bromide?**

**A:** Steroids should be administered as early in the ED visit as feasible. Significant clinical benefits begin two hours after administration and are most pronounced among the sickest children. A Cochrane Review demonstrated that steroid use decreased the need for hospitalization, decreased risk of relapse after initial treatment and may facilitate an earlier discharge from the hospital. Oral administration of steroids is just as effective as IV administration.



### Clinical Pearl:

Ipratropium bromide should be given concurrently with a beta-agonist. Ipratropium bromide MDI four puffs (80 mcg) or 250 mcg nebulized.



### Steroids:

Dexamethasone suspension 0.6 mg/kg (max. 20 mg) OR prednisone suspension 1mg/kg (max. 60 mg).

Dexamethasone tastes better and may be given in smaller volumes. Studies show 0.6 mg/kg for two days is just as good as prednisone for five days, and compliance may improve as a result.

**Case continued:** The 10-year-old boy has improved significantly and has a good oxygen saturation, has no wheezing on auscultation, and feels better, with an acceptable peak expiratory flow. You are ready to discharge the patient.

**Q: What discharge instructions will you give the parents?**

**A:** Ensure the patient has an MDI spacer! If not, prescribe him one.

**Every child should have the following discharge instructions:**

- Complete a two- to five-day course of oral steroids, depending on the severity of the illness at presentation
- Continue to use a short-acting beta-agonist, such as salbutamol (200 mcg [0.3 puffs/kg to a maximum of two puffs] every four hours) until exacerbations resolve and then as needed, with directions to see a health care professional if therapy is needed more often than every four hours
- Prepare a written asthma action plan
- Review techniques for using inhaled asthma medications, as well as for cleaning/maintaining the inhaler device
- Encourage follow-up with the patient's primary-care physician or a local asthma clinic to review asthma control, environmental history, and symptom recognition

While there is no evidence that the use of inhaled steroids in the ED is beneficial, there is evidence that they decrease relapse rates in the outpatient setting.

.....

Let's back up and pretend you have a similar scenario but with a patient who clinically worsens despite continuous nebulized beta-agonist and ipatropium bromide plus oral dexamethasone 0.6 mg/kg. His oxygen saturation is now 86% and he is showing signs of fatigue. His GCS is 14, and the nurse asks what you want to do next.

**Q: What other treatments should you consider?**

**A:** There is accumulating evidence that magnesium sulfate may benefit children with severe asthma. Meta-analyses have shown that the use of magnesium sulphate resulted in improved outcomes for both adults and children, improving respiratory function and decreasing hospital admissions. IV magnesium sulphate may be considered in cases of moderate and severe asthma with incomplete response to conventional therapy during the first one to two hours. The most common adverse effect is hypotension; this may be avoided by infusion of the dose over 20 minutes. Both IV and inhaled magnesium sulphate are effective.

If a patient has responded poorly to a beta-agonist/ipratropium/systemic corticosteroid/magnesium sulphate, then IV terbutaline can be considered and may reduce the need for assisted ventilation.

**Q: You have now tried everything you could think of for asthma, except epinephrine. In what situations is epinephrine indicated?**

**A:** Epinephrine is recommended for patients who are minimally responsive or responding poorly to beta-agonists/ipratropium/systemic corticosteroid/magnesium sulfate therapies, or who are unable to tolerate nebulized treatments, that parenteral epinephrine be considered. Initially, IM epinephrine can be given (0.01 mg/kg, max of 0.3 mg dose).

**Q: One of the medical students mentions hearing about something called heliox. What is heliox, and is there any role for it in this context?**

**A:** Heliox is a mixture of helium and oxygen. In conditions where there is increased airway resistance (asthma, croup, upper airway masses, etc.) there is turbulent airflow, which increases the work of breathing. Heliox can reduce airway resistance by increasing laminar airflow, and decrease the work of breathing.

Currently, systematic reviews and guidelines state that heliox should not be used routinely in patients with acute asthma in the ED.

Using a helium-oxygen gas mixture is generally reserved for children in the ICU setting with severe asthma exacerbation who have failed to improve despite maximized therapy.



Consider heliox in a patient with increased work of breathing in whom there has been no improvement with first- and second-line therapies. A trial of heliox may help patients who have conditions in which securing an advanced airway may be challenging (e.g., croup, asthma).



**Caution:**

Heliox should not be given to patients who require high oxygen concentrations, as the ratio of helium to oxygen in heliox is 70:30 or 80:20, which does not deliver high enough oxygen concentrations for patients who are severely hypoxic.

**Q: You have heard that if you need to intubate, ketamine is a good choice as the induction agent. But you wonder: Is ketamine useful in preventing the need for intubation in the worsening asthmatic?**



**A:** Current literature on this topic is mixed.

A limited case series has reported the effectiveness of a bolus (2 mg/kg) followed by a continuous infusion (2–3 mg/kg/h) of ketamine in children with severe asthma who were approaching respiratory failure. In this study, the use of ketamine resulted in prompt improvement and avoided the need for endotracheal intubation. This is an appealing use of ketamine, because it may allow one to avoid the hazards of endotracheal intubation and mechanical ventilation in the patient with asthma.

A randomized controlled trial showed no improvement in pulmonary index scores with the administration of ketamine to patients with moderate to severe asthma. Patients were randomized to 0.2 mg/kg ketamine bolus followed by 0.5 mg/kg/h for two hours versus placebo. Pulmonary index scores were measured throughout the two hours and no difference was found.

In a 2001 prospective, observational, single-arm pilot study in two pediatric EDs over three months, the effect of IV ketamine added to standard therapy in status asthmaticus was evaluated. Initiation of ketamine in patients with severe asthma was associated with clinical improvement. Side effects were easily managed with treatment or discontinuation of ketamine.

The take-home message is that more convincing evidence is required before ketamine can be recommended for routine treatment of severe pediatric asthma to avoid intubation. Ketamine, however, is safe at dissociative dosages, and is a reasonable option when all others measures have failed.

**Case continued:** This 10-year-old boy who is now suffering from worsening status asthmaticus is given IV magnesium and IM epinephrine in addition to continuous salbutamol, and he continues to tire. His GCS has dropped to 13 and his VBG shows an elevated CO<sub>2</sub>.

**Q: What are your next steps in managing this patient?**

**A:** Positive-pressure ventilation should be considered, and you should prepare for intubation.



**Caution:**

Up to 26% of children intubated due to asthma have such complications as pneumothorax, impaired venous return, and cardiovascular collapse because of increased intrathoracic pressure. Mechanical ventilation during an asthma exacerbation is associated with an increased risk of death and should be considered as a last resort and in conjunction with the support of a pediatric ICU specialist.





The decision to intubate should be based on clinical judgment as opposed to any single vital sign or blood gas result. Some variables to consider for intubation are worsening hypercapnea, patient exhaustion, and changes in mental status.

**Q: What is your ultimate disposition for this 10-year-old asthmatic? What are your criteria for admission in general?**

**A:**



### **Criteria for Admission in Pediatric Asthma**

**Admission** should be considered if any one of the following apply:

- An ongoing need for supplemental oxygen
- Persistently increased work of breathing
- Beta-agonists are needed more often than q4 h after four to eight hours of conventional treatment
- The patient deteriorates while on systemic steroids

Other criteria may also be taken into consideration (e.g., distance from home, comorbid conditions such as anaphylaxis).

**ICU admission** or referral to a tertiary-care centre should be considered if the patient requires continuous nebulized salbutamol and fails to improve on this therapy.

**Q: Let's say this 10-year-old asthmatic improved in the ED. What are your discharge criteria for pediatric asthma?**

**A:**



### **Discharge Criteria in Pediatric Asthma**

**Discharge** criteria from the ED include:

- Needing beta-agonists less often than q4 h after four to eight hours of conventional treatment
- A reading of SpO<sub>2</sub> 94% on room air
- Minimal or no signs of respiratory distress
- Improved air entry



### **Comments?**

[Click here to leave a comment](#)  
[or to listen to this podcast.](#)

---

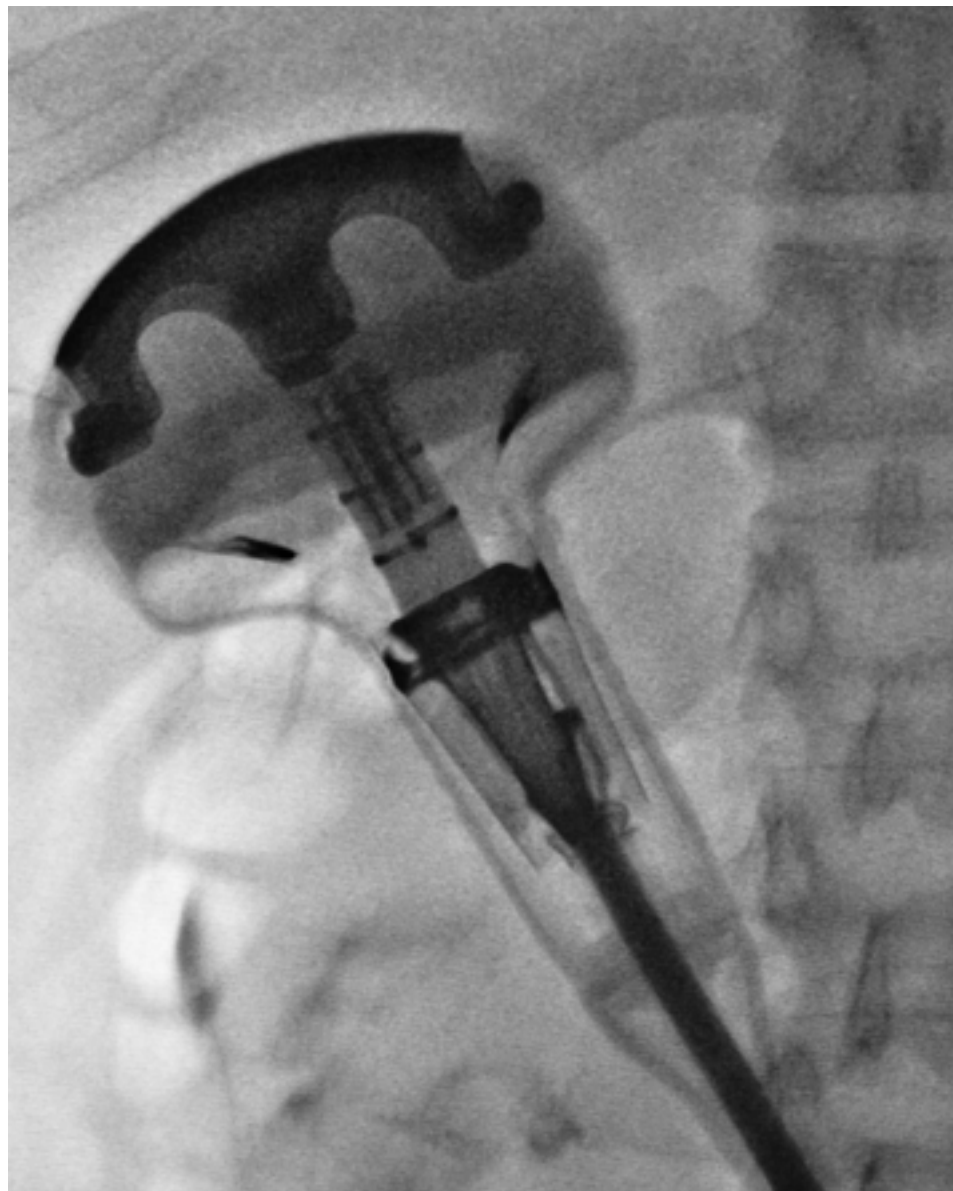## **KEY REFERENCES:**

1. Belessis Y, Dixon S, Thomsen A, et al. Risk factors for an intensive care unit admission in children with asthma. *Pediatr Pulmonol*. 2004; Mar;37(3):201-9.
2. Gorelick MH, Stevens MW, Schultz T, Scribano PV. Difficulty in obtaining peak expiratory flow measurements in children with acute asthma. *Pediatr Emerg Care*. 2004; Jan;20(1):22-6.
3. Parkin PC, Macarthur C, Saunders NR, Diamond SA, Winders PM. Development of a clinical asthma score for use in hospitalized children between 1 and 5 years of age. *J Clin Epidemiol*. 1996; Aug;49(8):821-5.
4. Chalut DS, Ducharme FM, Davis GM. The Preschool Respiratory Assessment Measure (PRAM): A responsive index of acute asthma severity. *J Pediatr*. 2000; Dec;137(6):762-8.
5. Gorelick MH, Stevens MW, Schultz TR, Scribano PV. Performance of a novel clinical score, the Pediatric Asthma Severity Score (PASS), in the evaluation of acute asthma. *Acad Emerg Med*. 2004; Jan;11(1):10-18.

6. Birken CS, Parkin PC, Macarthur C. Asthma severity scores for preschoolers displayed weaknesses in reliability, validity, and responsiveness. *J Clin Epidemiol*. 2004; Nov;57(11):1177-81.
7. Ortiz-Alvarez O, Mikrogianakis A, Canadian Paediatric Society Acute Care Committee. Managing the pediatric patient with an acute asthma exacerbation. *Paediatr Child Health*. 2012; May;17(5):251-62.
8. Gershel JC, Goldman HS, Stein RE, Shelov SP, Ziprkowski M. The usefulness of chest radiographs in first asthma attacks. *N Engl J Med*. 1983; Aug;309(6):336-9.
9. Castro-Rodriguez JA, Rodrigo GJ. Beta-agonists through metered-dose inhaler with valved holding chamber versus nebulizer for acute exacerbation of wheezing or asthma in children under 5 years of age: A systematic review with meta-analysis. *J Pediatr*. 2004; Aug;145(2):172-7.
10. Cates CJ, Welsh EJ, Rowe BH. Holding chambers (spacers) versus nebulisers for beta-agonist treatment of acute asthma. *Cochrane Database Syst Rev*. 2013; Issue 9.
11. Camargo CA, Spooner CH, Rowe BH. Continuous versus intermittent beta-agonists in the treatment of acute asthma. *Cochrane Database Syst Rev*. 2003; Issue 4.
12. Rodrigo GJ, Castro-Rodriguez JA: Anticholinergics in the treatment of children and adults with acute asthma: A systematic review with meta-analysis. *Thorax*. 2005; Sep;60(9):740-6.
13. Doymaz S, Schneider J, Sagy M. Early administration of terbutaline in severe pediatric asthma may reduce incidence of acute respiratory failure. *Ann Allergy Asthma Immunol*. 2014; Mar;112(3):207-10.
14. Rowe BH, Bretzlaff JA, Bourdon C, Bota GW, Camargo CA Jr. Intravenous magnesium sulfate treatment for acute asthma in the emergency department: A systematic review of the literature. *Ann Emerg Med*. 2000; Sep;36(3):181-90.
15. Mohammed S, Goodacre S. Intravenous and nebulised magnesium sulphate for acute asthma: Systematic review and meta-analysis. *Emerg Med J*. 2007; Dec;24(12):823-30.
16. Cheuk DK, Chau TC, Lee SL. A meta-analysis on intravenous magnesium sulphate for treating acute asthma. *Arch Dis Child*. 2005; Jan;90(1):74-7.
17. Denmark TK, Crane HA, Brown L. Ketamine to avoid mechanical ventilation in severe pediatric asthma. *J Emerg Med*. 2006; Feb;30(2):163-6.
18. Allen JY, Macia CG. The efficacy of ketamine in pediatric emergency department patients who present with acute severe asthma. *Ann Emerg Med*. 2005; Jul;46(1):43-50.
19. Petrillo TM, Forteberry JD, Linzer JF, Simon HK. Emergency department use of ketamine in pediatric status asthmaticus. *J Asthma*. 2001; Dec;38(8):657-64.

# CHAPTER 14: LUNG POCUS

[LISTEN TO THE PODCAST WITH ALYSSA ABO HERE](#)



## Objectives

1. Understand the advantages of lung Point of Care Ultrasound (POCUS)
2. Understand the steps to perform lung POCUS to diagnose pneumonia
3. Understand the common pearls and pitfalls of lung POCUS

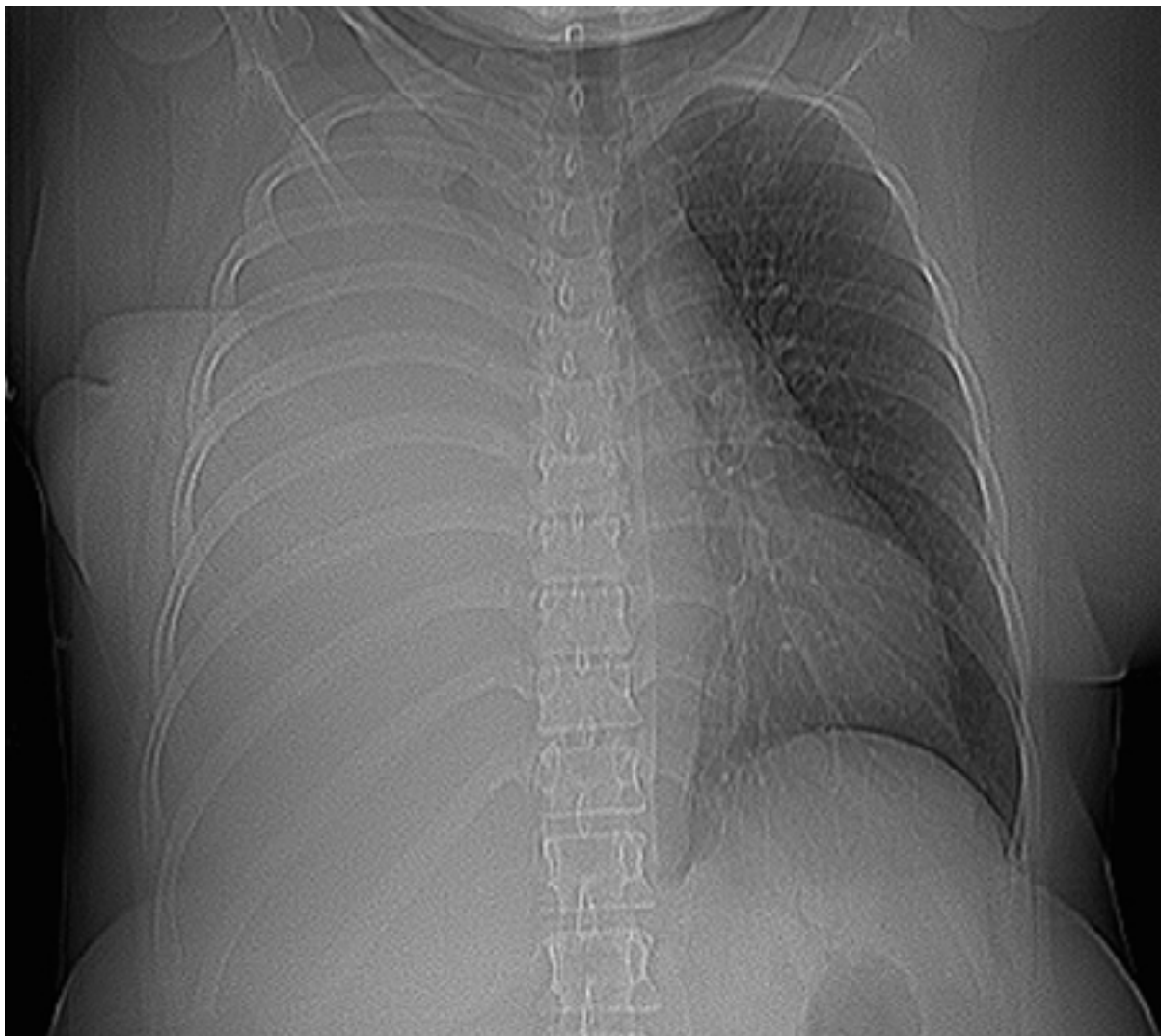


**Q: I have treated pneumonia many-a-time without using the complicated ultrasound machine. Why should I learn to do this?**

**A:** Many children present to the emergency department with respiratory illnesses. Although only a small number of these patients have pneumonia, a large number of these patients receive chest X-rays. POCUS may be used not only to limit the number of chest X-rays performed on patients, but also because it is more accurate than chest X-ray in diagnosing pneumonia.

## **CASE 1: THE CASE OF THE NON-RADIATING WAR ON PNEUMONIA**

A three-year-old boy presents to the emergency department with fever, cough, and tachypnea. You order a chest X-ray and it shows the appearance of a complete whiteout of the right hemithorax. You have a discussion with your emergency team, mostly about placing a chest tube and obtaining a CT for this child. Someone mentions that you should consider doing a bedside ultrasound of the lungs. POCUS is performed, and the right lung shows a large pneumonia taking up the entire lung field with no fluid.





**Q: With these findings and the clinical picture favouring pneumonia, do you need a thoracic CT?**

**A:** Since the clinical scenario and the ultrasound findings are in favour of pneumonia, you may not need to go on to further CT investigations. Other advantages of using POCUS for suspected pneumonia include:

1. Differentiating pneumonia from a viral URTI or empyema
2. Potentially diagnosing early bacterial pneumonia before there is evidence of pneumonia on a chest X-ray
3. Reliably diagnosing retro-cardiac infiltrates that are difficult to visualize on chest X-ray



Use of lung POCUS has the potential to decrease the number of chest X-rays performed in pediatric patients in the future and can show the lungs in more detail for some illnesses.

**Q: But what if you're wrong? Perhaps a formal CT and a radiology opinion may be better. Can clinicians diagnose pneumonia accurately with POCUS?**

**A:**



**Key Reference:**

Prospective evaluation of POCUS for the diagnosis of pneumonia in children and young adults

- 200 patients with a pneumonia prevalence of 18%
- POCUS for pneumonia: Sensitivity = 86%; Specificity = 89%
- Positive LR = 7.8; negative LR = 0.2 for diagnosing pneumonia
- **Study author's conclusion:** Clinicians are able to diagnose pneumonia in children and young adults using POCUS with high specificity.



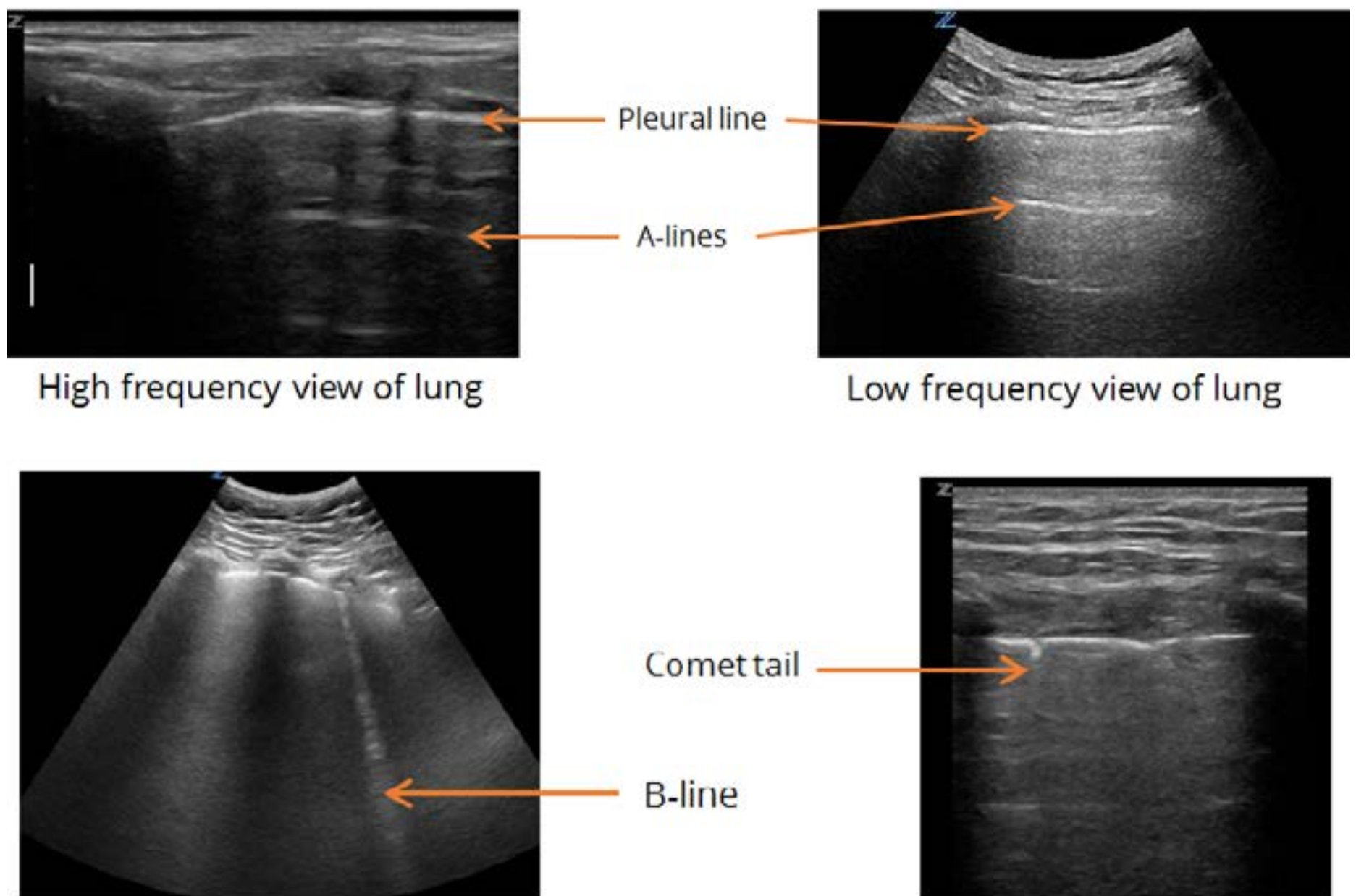
**Clinical Pearl:**

When performing an IVC, FAST, or para-sternal long view of the heart, portions of the lung may be seen in these views. Pay attention to these lung views. You may pick up pathology that you weren't expecting to find that explains the patient's acute presentation.

**Q: That makes you feel better. So, you see lots of different “lines” when you look at the lungs. What are the common lines on lung POCUS, and what do they all indicate?**

**A:** There are many different “lines” present on POCUS. The most common ones are A-lines, B-lines, and comet tails.

- 1. A-lines:** These are artifact lines horizontal to the pleural line that represent normal lungs
- 2. B-lines:** These are hyperechoic lines that extend vertically from the pleural line to the far field of the POCUS screen; they do not taper, they move with respiration, they are pathologic, and they abolish A-lines; they represent an interstitial process
- 3. Comet tails:** These are hyperechoic artifacts that extend vertically from the pleural line and taper in the far field and move with respiration; these are seen in normal lungs, but may be absent in normal lungs



**Q: You think you are convinced and are ready to start using POCUS for pneumonia. What are the steps for lung POCUS?**

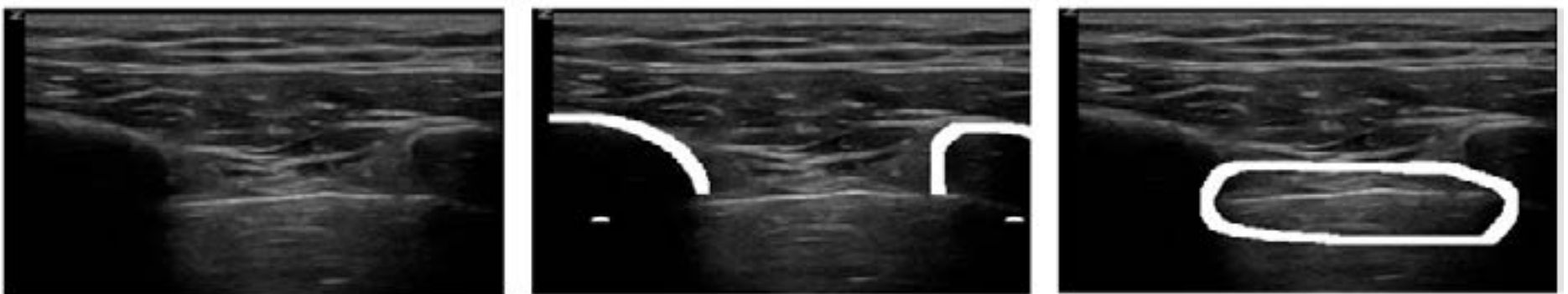
**A: Step 1: Find the landmarks**

**What is the ideal probe to use to look for pneumonia? Which orientation should be used?**

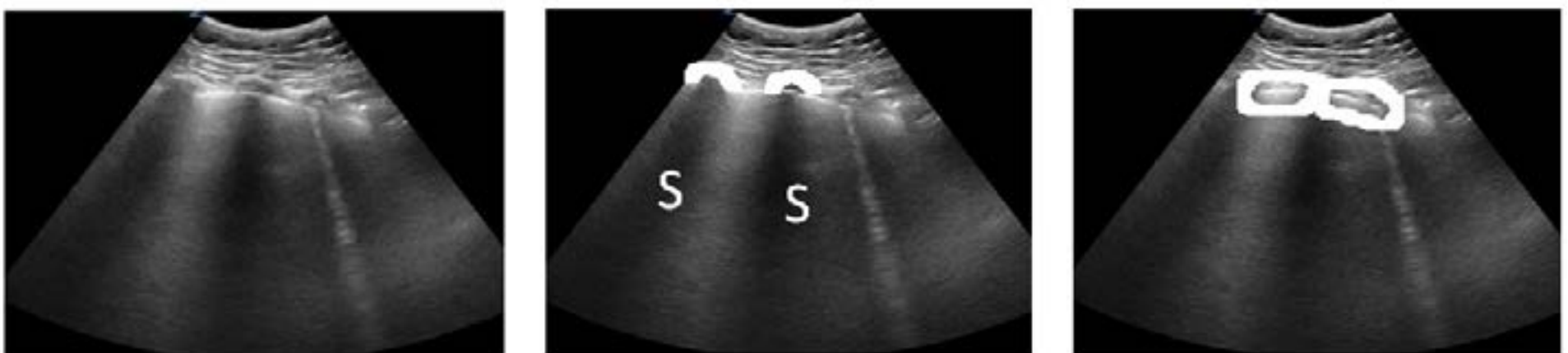The pneumonia scan starts by placing a high-frequency probe in the longitudinal plane on the child's chest. This will help identify landmarks and the pleura. Depending on the child's body size, the low-frequency probe will be needed to look deeper into the chest cavity to identify any evidence of pneumonia. Rotating the probe into the transverse plane to look between the ribs and sweep can also be used.

**What are the landmarks of pneumonia POCUS?**

Identify two rib shadows (hypoechoic shadows streaking down the screen). The hyperechoic, horizontal line approximately 1 cm below the rib is the pleural line. Lines horizontal to the pleural line are A-lines.



The high frequency view of the lung, with white crescents indicating ribs, S indicating rib shadows, and white circle 1 cm below ribs circling the pleura.



The low frequency view of the lung with ribs (white crescents), rib shadows (white S), and pleura (white circle) approximately 1 cm below ribs. The area in the far field between the shadows is the lung.



## **Step 2: Scan each area for signs of consolidation**

Now that you've identified the landmarks and determined the best probe to use for pneumonia POCUS, you need to ensure the entire lung field is visualized. How do you do this?

There are many different approaches to ensure the entire lung field is visualized:

- 1. Thirty-two region approach:** Divides the lung into 32 regions and scans each separately
- 2. Diagonal approach:** Starts at the superior portion of the chest toward the sternum and moves diagonally toward the flank
- 3. Anterior, axillary, posterior approach:** Divides the lung into these three regions and looks superiorly and inferiorly in these areas



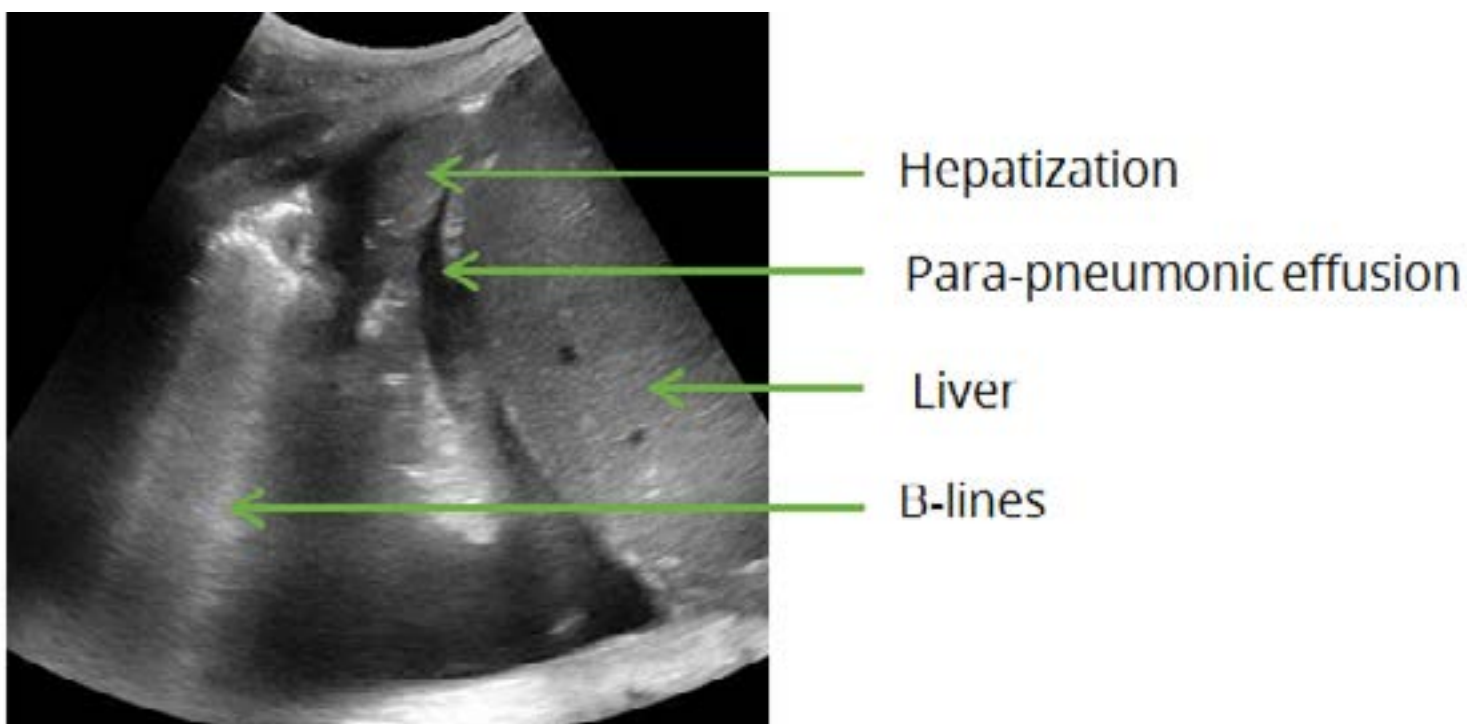
### **Clinical Pearl:**

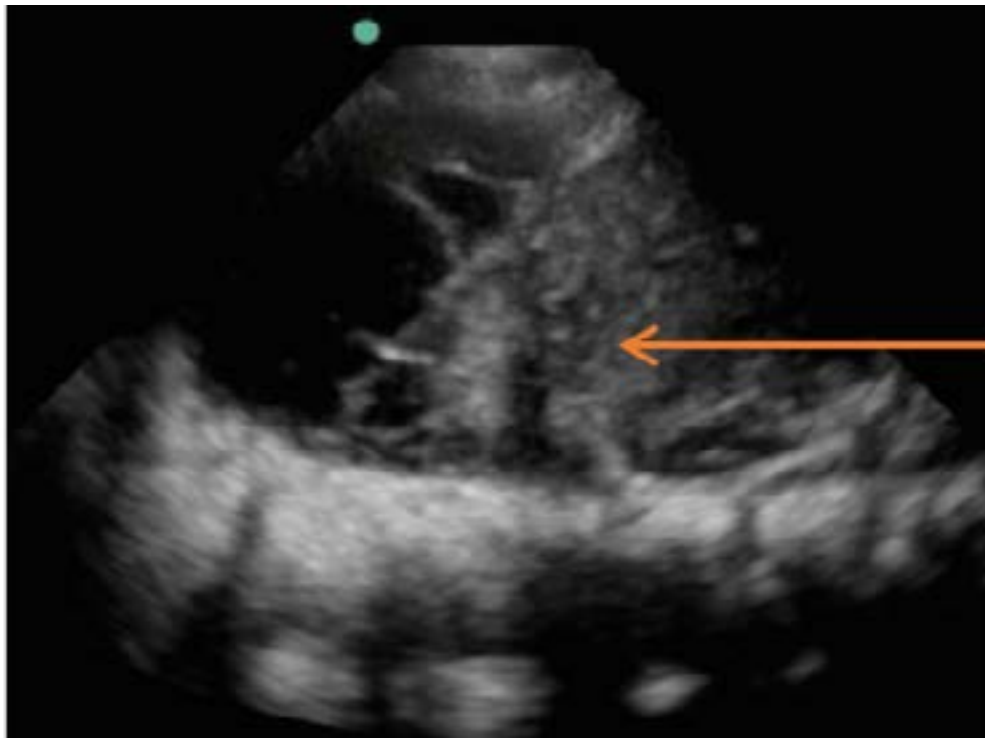Regardless of which approach is used, ensure that a combination of slides and sweeps are employed to see the entire lung field. It may require both transverse and longitudinal orientations (quite possibly even an oblique view with the probe) to see the entire lung field.

**Q: If you are looking for signs of consolidation, what do you need to watch for?**

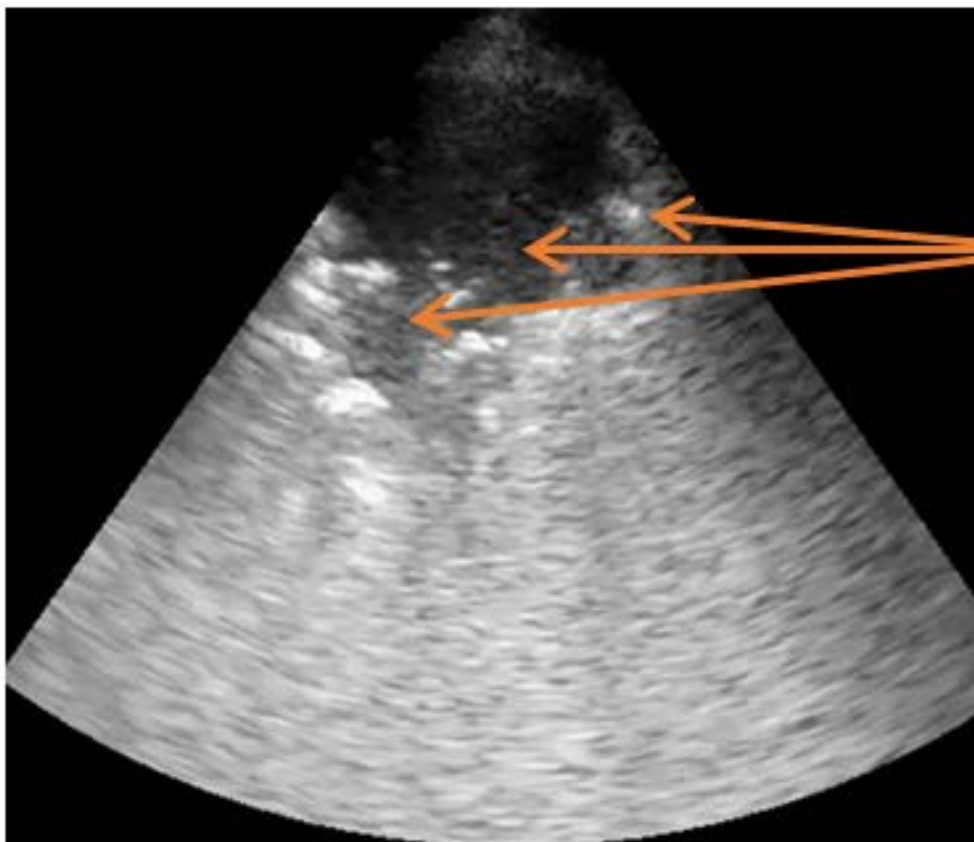
**A:** The distinctive features of consolidation on lung POCUS include:

- 1. Hepatization:** The lung looks like liver tissue
- 2. Shred sign:** Pleural edges look uneven and have irregular borders
- 3. Tissue sign:** Looks like tissue instead of normal lung appearance





Tissue sign of consolidation



Shred sign (pleural edges are uneven and have irregular borders)



### Clinical Pearl:

**Retro-cardiac pneumonia** can be diagnosed by performing a parasternal long view of the heart and looking in the far field. In the setting of retro-cardiac pneumonia there will be loss of mirror artifact, presence of B-lines, and other signs of consolidation. Retro-cardiac pneumonia is often missed, even on chest X-ray.



**Q: You think you are seeing consolidation, but you wonder if it could just be atelectasis. How do you differentiate between consolidation and atelectasis on POCUS?**

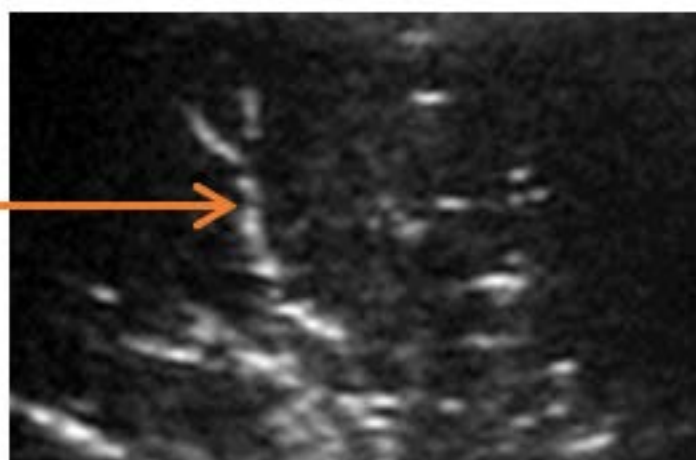
**A:** It is very difficult to determine the difference between atelectasis and consolidation on POCUS. A characteristic to help distinguish between the two is air bronchograms (air in the bronchus much like it is seen on a chest X-ray). Although both atelectasis and consolidation can display air bronchograms, if air bronchograms are dynamic during the respiratory cycle it should prompt a higher suspicion for consolidation. However, clinical correlation is required to help distinguish between the two.



**Pitfall:**

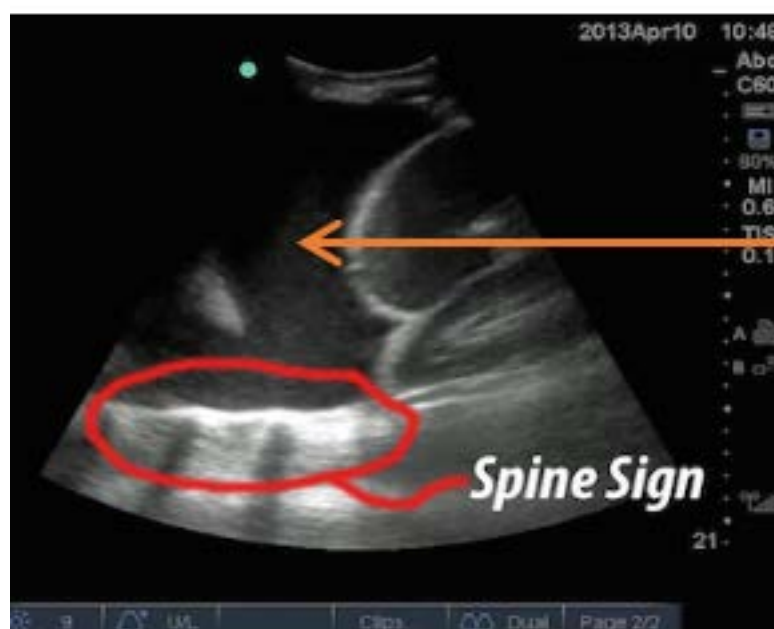Missing any part of the lung fields with the ultrasound probe may miss important lung pathology.

Air bronchogram



**Clinical Pearl:**

When scanning the lungs on the FAST exam, seeing the spine in the far field cephalad to the diaphragm can indicate the presence of lung pathology (e.g., hemothorax, pleural effusion, parapneumonic effusion).



Pleural effusion

**Q: When you are scanning, you may notice a bright white line above the diaphragm, consistent with the spine. Why is the spine seen so clearly in the setting of a hemothorax or pleural effusion?**

**A:** The lung is normally filled with air, which causes scatter of the ultrasound beam. Thus, no far-field structures are seen through the lung, as it makes for a poor acoustic window for the ultrasound beam. However, when fluid is present in the lung from a hemothorax or pleural effusion, it provides an excellent acoustic window, which allows beams to pass through and identify far-field structures such as the spine. (Analogy: Pregnant women need to fill their bladder before an obstetric ultrasound to see the fetus through the bladder. If the bladder is not filled, it is difficult to visualize the fetus.)

**Video:** [Click here to watch a video of lung POCUS by Dr. Mike Stone.](#)



### Comments?

[Click here to leave a comment or to listen to this podcast.](#)

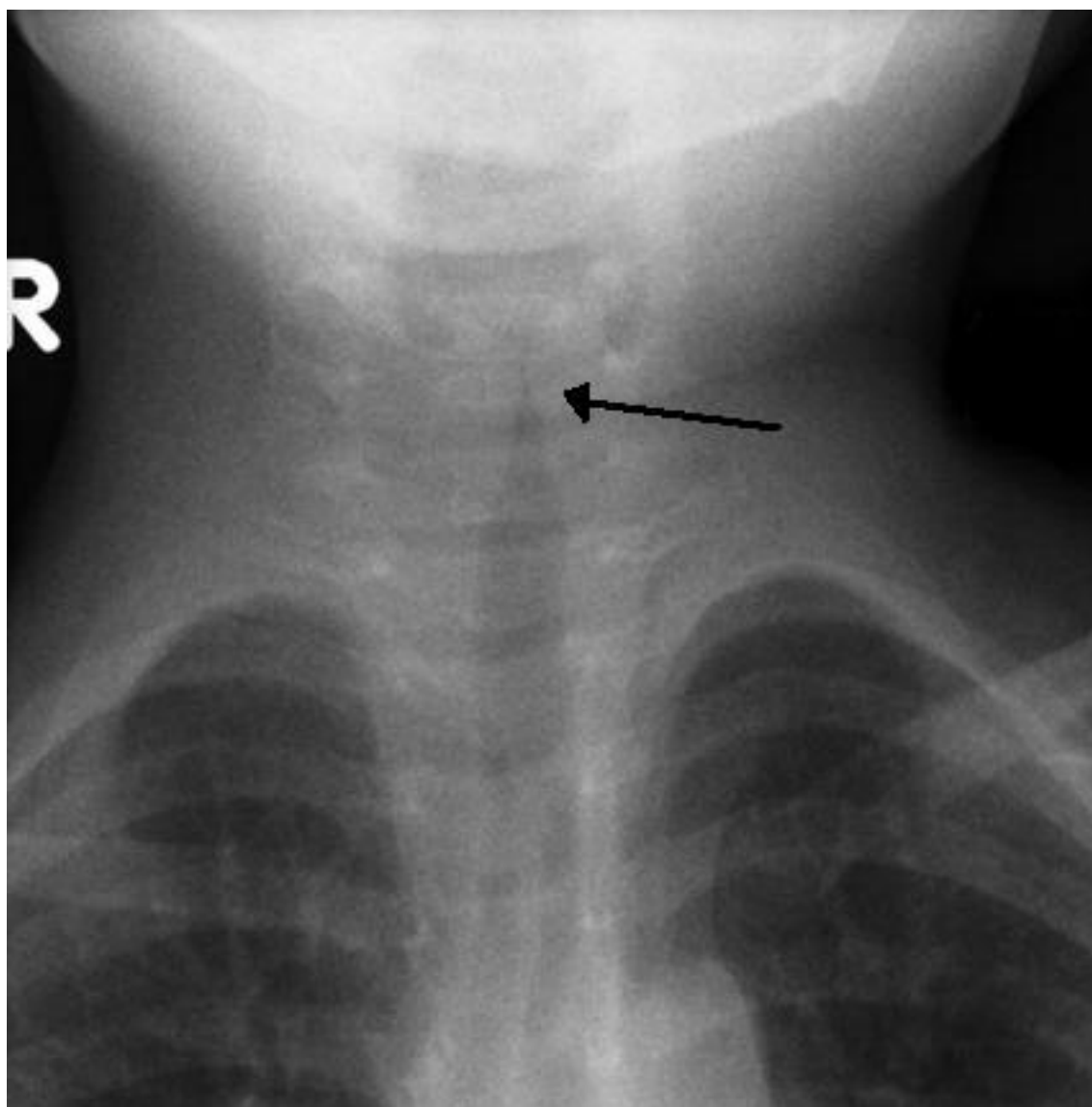
---

## KEY REFERENCES:

1. Cortellaro F, Colombo S, Coen D, Duca PG. Lung Ultrasound is an Accurate Diagnostic Tool for the Diagnosis of Pneumonia in the Emergency Department. *Emerg Med J.* 2012; Jan;29(1):19-23.
2. Shah VP, Tunik MG, Tsung JW. Prospective evaluation of POCUS for the diagnosis of pneumonia in children and young adults. *JAMA Pediatrics*, 2013; Feb;167(2):119-25.
3. Lichtenstein D, Meziere G, Seitz J. The dynamic air bronchogram: A lung ultrasound sign of alveolar consolidation ruling out atelectasis. *Chest.* 2009; Jun;135(6):1421-5.

# CHAPTER 15: PEDIATRIC CROUP

SPECIAL THANKS TO DENNIS SCOLNIK AND SANJAY MEHTA

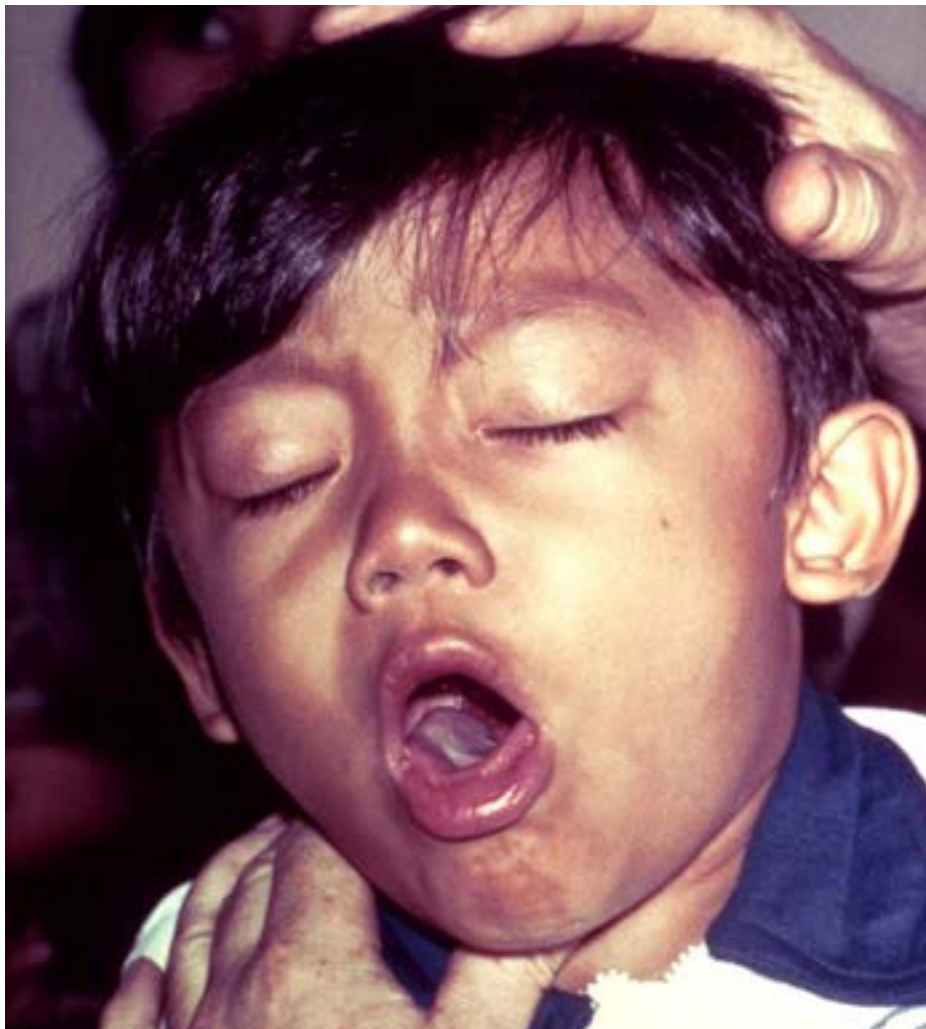

## Objectives

1. Review the differential diagnosis of stridor in children
2. Understand the value of imaging in children with stridor
3. List the evidence-based medications for croup
4. Review the criteria for admission for children with croup

## CASE 1: A BARKING COUGH

A four-year-old boy is brought in to the ED by his mother on an early winter evening. She is concerned about his strange sounding cough, hoarse voice, and noisy breathing that she noticed while her son was sleeping that evening. For the past few days he has had a mild cough and runny nose. On exam he has a heart rate of 130, respiratory rate of 40, blood pressure 90/60, an oxygen saturation of 99%, and temperature of 37.9°C. As you enter the patient's room, you can hear a croupy cough and stridorous respirations from across the room.



**Q: As you start to examine this patient, what are you thinking about in terms of a differential diagnosis?**

**A:** The differential diagnosis of stridor in a child includes croup, bacterial tracheitis, epiglottitis, foreign body, retropharyngeal abscess, and anaphylaxis.

Other less common diagnoses to be considered are:

- Upper airway injury
- Congenital upper airway anomalies
- Acute angioneurotic edema
- Neck mass
- Laryngeal diphtheria
- Measles

Features that are not consistent with croup:

- Toxic-looking child
- Drooling
- Posturing to protect airway
- Sore throat



### **Clinical Pearl:**

In children younger than six months of age, check for cutaneous hemangiomas as a clue that there may be a subglottic hemangioma causing stridor.

**Q: Common things being common, you think this might be croup. What is croup?**

**A:** Croup is a common upper airway infection caused mostly by parainfluenza, but also by RSV, rhinovirus among others. It is seen in children three months to six years of age with a peak incidence at two years of age. It is typically seen in the fall and early winter and preceded by a viral prodrome. The symptoms become more prominent at night with peak symptoms around the second night of the illness.

**Q: This boy is not very happy and keeps throwing the oxygen saturation probe off of his finger. As you're encouraging him to keep it on, you wonder about the utility of an oxygen saturation in a child with croup. How can the oxygen saturation of a child with croup be misleading?**

**A:** Oxygen saturation may be normal in a child with severe croup, or, conversely, substantially lowered in a child with mild to moderate croup. This variability presumably relates to ventilation-perfusion mismatching caused by lower-airway disease.



**Q: You finish assessing your patient and you are wondering about ordering an X-ray. Under what conditions should a soft tissue X-ray of the neck be obtained for presumed croup?**

**A:** Croup is a clinical diagnosis and laboratory and imaging are not required to make the diagnosis.

Performing an X-ray of the soft tissues of the neck is generally not necessary or advisable in presumed croup, as information that would alter the management of croup is rarely derived from an X-ray.

Imaging is typically reserved for children with findings suggestive of another diagnosis, such as epiglottitis, retropharyngeal abscess, or aspirated foreign body. Direct visualization via nasotracheal fibre-optic scope is generally preferred over imaging.

Subglottic narrowing, radio-opaque foreign bodies, and supraglottic swelling may be apparent on a technically good radiograph of the airway, but the risk of the procedure generally outweighs any benefits, as the neck extension required for the procedure may lead to sudden severe obstruction. Managing a life-threatening upper airway obstruction in the radiology department is not without challenges and risks!

**Q: What treatments would you order for this four-year-old boy with presumed croup?**

**A:** Dexamethasone 0.6 mg/kg (max 20 mg) should be given to all patients with croup in the ED. This is the preferred steroid due to its long half-life. The literature shows an improvement in croup scores at six and 12 hours after the first dose (but no difference at 24 hours) and a reduction in the need for nebulized epinephrine treatment, as well as a reduction in the need for hospital admission, length of stay, and return visits to the ED. The literature shows, however, that there is no difference in the need for intubation with dexamethasone when compared with placebo.



If the patient is unable to tolerate oral medications, use nebulized budesonide 2 mg (4 ml of 0.5 mg/ml solution) delivered along with nebulized epinephrine (if necessary). Alternatively, dexamethasone IM or methylprednisolone IV may also be given.

**Q: What are the indications for treating croup with nebulized epinephrine?**

**A:** Nebulized epinephrine is indicated for stridor at rest or marked suprasternal retractions. It works through the vasoconstrictive alpha effects to decrease airway mucosal edema. The onset of action is 10 minutes and the effects can last up to one hour. The literature demonstrates that croup scores are improved at 30 minutes after first dose, but at two hours and six hours there is no difference in croup scores compared with placebo. The use of nebulized epinephrine has been shown to reduce the rate of intubation, admission to hospital, and admission to ICU for moderate to severe croup.



Racemic and regular epinephrine have equivalent efficacy and safety in the management of croup. Racemic epinephrine was previously thought to have fewer complications, but there are no data to support this. The dosing of nebulized epinephrine is 0.5 ml/kg of 1:1000 epinephrine (max. 5 ml). This can be repeated once in 20 minutes in cases of severe croup.

**Q: You begin to form your disposition plan for this four-year-old boy. How long do children with croup need to be monitored in the ED, and what are the criteria for sending them home?**

**A:** Children who are treated with epinephrine they should be observed for a minimum of three hours before being discharged from medical care.

### **Criteria for Safe Discharge Home**

Absence of inspiratory stridor at rest and respiratory distress (suprasternal, intercostal and chest wall indrawing).

### **Criteria for Hospital Admission**

Persistence of stridor at rest and respiratory distress for **four hours or more after treatment with dexamethasone** (or another corticosteroid) and repeated doses of nebulized epinephrine.

### **Criteria for transfer to Children's Intensive Care Unit**

Persistent severe croup (stridor, often biphasic, severe chest wall indrawing, and agitation) despite treatment with two doses of nebulized epinephrine and oral dexamethasone within the first two hours of assessment and treatment.



### Clinical Pearl:

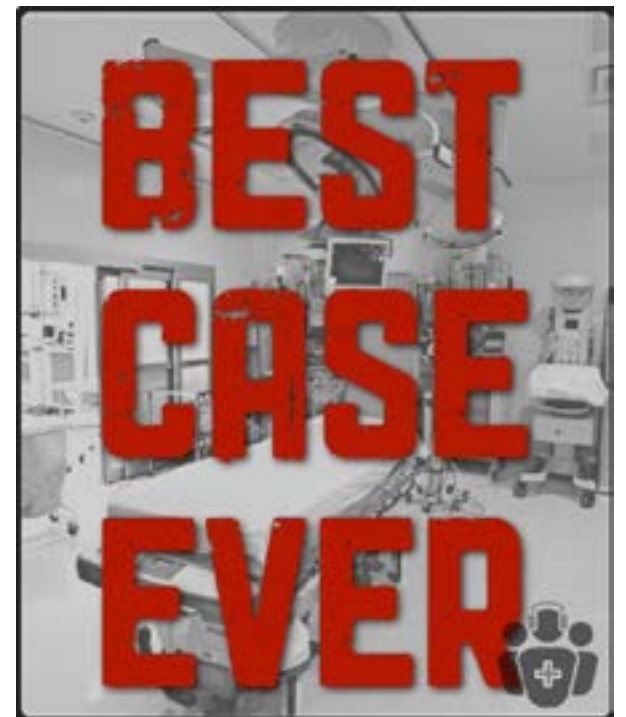
Always inform the family the child's cough can last up to several weeks and the stridor may recur during episodes of agitation/excitement.

**Q: After you give the parents your discharge instructions, they ask you about ways they can help their child recover from croup at home. Is there any evidence for effectiveness of humidified air, mist therapy, or antitussives in the treatment of croup?**

**A:** There is no evidence for **antitussives**. They have no proven effect on the course or severity of croup and may increase sedation, thus interfering with assessment.

Codeine, in particular, should never be used in children or breastfeeding mothers, as there have been several case reports of death following codeine ingestion at therapeutic doses.

There is no added benefit for treatment with **humidified air**. It was previously widely used and is still commonly recommended as a home treatment. Three studies in hospital emergency settings provided data on 135 children with moderately severe croup symptoms. No outcome measures were significantly different between groups. Further research is needed in primary-care settings and using more sensitive measures of benefit. **Mist therapy** is not effective in improving clinical symptoms in children presenting to the ED with moderate croup.



[For Dr. Anthony Crocco's rant on codeine use in children, click here to listen to his Best Case Ever.](#)

**Another case:** A few shifts later, you have another four-year-old child with a croupy cough and stridor. The child receives oral dexamethasone and nebulized epinephrine and three hours later continues to be stridorous with worsening retractions.

**Q: How would you manage this child differently compared with the previous case?**

**A:** You may consider using heliox. However, heliox has **not** been shown to reduce the need for intubation in severe croup.

In a child whose croup is progressing despite treatment in the ED, you should prepare for intubation. Approximately 3 in 1,000 cases of croup require intubation, with a mortality rate of < 0.5% in intubated patients.



**Clinical Pearl:**

When considering intubation in patients with croup, one must anticipate a challenging airway and use a 1–1.5 mm smaller size ETT than otherwise indicated.



**Pitfall:**

Kids should never be discharged from the ED with stridor at rest!

**Q: As you are assessing the child again, the mother mentions this is their fourth visit to the ED for the same issue. When should you worry about the child with recurrent croup?**

**A:** Recurrent croup (three or more episodes) should be considered a red flag for an alternative underlying cause. Anatomic abnormalities have been reported in a significant proportion of patients with recurrent croup. Most, if not all, of these patients will require bronchoscopy by ENT to rule out anatomic abnormalities.



## KEY REFERENCES:

1. Rihkanen H, Rönkkö E, Nieminen T, et al. Respiratory viruses in laryngeal croup of young children. *J Pediatr*. 2008; May;152(5):661-5,
2. Stoney PJ, Chakrabarti MK. Experience of pulse oximetry in children with croup. *J Laryngol Otol*. 1991; Apr;105(4):295-8.
3. Bjornson CL, Klassen TP, Williamson J, et al. A randomized trial of a single dose of oral dexamethasone for mild croup. *N Engl J Med*. 2004; Sep;351(13):1306-13.
4. Ledwith CA, Shea LM, Mauro RD. Safety and efficacy of nebulized racemic epinephrine in conjunction with oral dexamethasone and mist in the outpatient treatment of croup. *Ann Emerg Med*. 1995; Mar;25(3):331-7.
5. Prendergast M, Jones JS, Hartman D. Racemic epinephrine in the treatment of laryngotracheitis: can we identify children for outpatient therapy? *Am J Emerg Med*. 1994; Nov;12(6):613-6.
6. Waisman Y, Klein BL, Boenning DA, et al. Prospective randomized double-blind study comparing L-epinephrine and racemic epinephrine aerosols in the treatment of laryngotracheitis (croup). *Pediatrics*. 1992; Feb;89(2):302-6.
7. Bjornson C, Russell K, Vandermeer B, Klassen TP, Johnson DW. Nebulized epinephrine for croup in children (Review). *Cochrane Database Syst Rev*. 2013; Issue 10.
8. Moore M, Little P. WITHDRAWN: Humidified air inhalation for treating croup. *Cochrane Database Syst Rev*. 2011; Issue 6.
9. Neto GM, Kentab O, Klassen TP, Osmond MH. A randomized controlled trial of mist in the acute treatment of moderate croup. *Acad Emerg Med*. 2002; Sep;9(9):873-9.
10. Joshi V, Malik V, Mirza O, Kumar BN. Fifteen-minute consultation: structured approach to management of a child with recurrent croup. *Arch Dis Child Educ Pract Ed*. 2014; Jun;99(3):90-3.
11. Rankin I, Wang SM, Waters A, Clement WA, Kubba H. The management of recurrent croup in children. *J Laryngol Otol*. 2013; May;127(5):494-500.

# CHAPTER 16: PEDIATRIC SYNCOPE

[LISTEN TO THE PODCAST WITH ERIC LETOVKSY AND ANNA JARVIS HERE](#)



## Objectives

1. Develop an approach to assessing a child who presents to the ED with syncope
2. Distinguish between syncope and seizure
3. Understand the key historical and physical exam features that distinguish benign versus serious causes of syncope
4. Develop an approach to reading the ECG of a child who presents to the ED with syncope

## CASE 1: A STICKY LOC SITUATION

Sammy is a 15-year-old male out with his friends at a summer concert watching a cool new band, The Crew, at the town festival. It is a hot summer day. Sammy starts to feel warm and nauseated, and begins to sweat profusely. Sammy loses consciousness and drops to the ground. There are a few jerking movements of his limbs. He is unconscious for only half a minute and quickly regains consciousness. His shirt is soaked with sweat. When his friends question him, Sammy tells them he remembers feeling warm and nauseated before he passed out, but does not remember being unconscious. When you assess him in the ED he says he feels fine, and his vital signs are all normal.



**Q: What is your general approach to a sudden loss of consciousness in a child?**

**A:**

- **Step 1:** Differentiate syncope from seizure
- **Step 2:** Categorize syncope by the underlying cause as benign or serious/life-threatening, and whether the cause is autonomic, cardiac, or non-cardiac
- **Step 3:** Assess the risk for a future cardiovascular event or sudden death

**Step 1:**

**Q: Was Sammy's episode at the concert a syncopal episode or a seizure?**

**A:** Syncope is a symptom, not a diagnosis. It is characterized by a sudden loss of consciousness as a result of decreased cerebral blood flow, with full recovery to a baseline level of awareness within seconds to minutes. There are often a few jerking limb movements associated with syncope as cerebral blood flow decreases, which can be confused with seizure. Soft tissue injuries at multiple body sites, posturing, and a rigid (tonic) phase before rhythmic activity (clonus) are more consistent with a seizure than with syncope. Both syncope and seizure can cause urinary incontinence, but unlike seizure, patients with syncope return quickly to a their baseline level of alertness.

**Step 2:**

**Q: Was Sammy's episode at the concert a syncopal episode or a seizure?**

**A:** While Sammy's episode is quite classic for vasovagal syncope, more serious causes need to be ruled out.

Vasovagal syncope commonly presents with presyncopal symptoms—increased warm or cold sensation, nausea, diaphoresis—occurring with prolonged standing (or changing position from a lying or sitting position to a standing position), followed by a brief loss of consciousness (usually between five and 20 seconds) with a quick resolution.

Patients with vasovagal syncope typically display pallor, with cold skin, profuse diaphoresis, and occasionally dilated pupils. In general, this phase is not typically recalled by the patient. Rarely, patients can describe feeling “disconnected” or being able to hear bystanders' voices while being unable to respond to them.



**Clinical Pearl:**

Vasovagal syncope almost never occurs in a supine position. In the supine position, venous pooling is less likely to occur, which is a key mechanism of vasovagal syncope.



## Major Categories of Syncope

- **Vasovagal:** Prodrome of nausea, presyncope, and sweating; triggered by pain, anxiety, distress, or by prolonged standing or kneeling in a warm and/or crowded place
- **Situational:** Occurs with micturition, cough, defecation; or by carotid sinus pressure (e.g., turning head, shaving), subclavian steal (e.g., during arm exercises), or breath-holding spell
- **Orthostatic:** Dehydration, alcohol, blood loss
- **CNS:** Rarely the cause of syncope as the only symptom
- **Cardiovascular:** Dysrhythmia, structural heart disease, or ischemia; historical clues include a family history of sudden/unexplained death, exertional syncope and no prodrome

### Q: How is syncope evaluated in the pediatric population?

**A:** A detailed history and physical exam will identify the cause of syncope in nearly 50% of the patients. A 12-lead ECG should be obtained in every patient. Routine labs and neuroimaging are not recommended.

### Q: We know that a good history is essential in evaluating the child after a syncopal episode. What are some of the key historical features that help distinguish benign from serious causes of syncope?

**A:**

- **Pattern:** Is this the first presentation, or is there a pattern of recurring episodes?
- **Position:** What position was the patient in?
- **Exertion:** Was physical exertion involved?
- **Situation:** What was happening at the time before syncope?



- **Signs/symptoms:** Diaphoretic or dry; flushed, cyanotic, pallor, chest pain, palpitations. What signs/symptoms was the patient experiencing or was noticed by eyewitnesses?
- **Onset:** How acute was the onset? Prodrome or acute?
- **Movements:** Were there involuntary movements (jaw locking, tongue biting)? When did the movements start (before, at, or after the onset of syncope)?
- **Colour:** What colour was the patient (pallor, flushed, cyanotic)?
- **Time:** How long did the unconsciousness last (seconds or minutes)?
- **Recovery:** Confusion versus no confusion: How aware was the patient after? Was there confusion?
- **Injury:** Did the patient sustain injury (e.g., tongue biting, multiple sites of trauma)?

**Q: Which groups of patients are considered high risk and need further workup?**

**A:** Patients presenting with any of the following require a thorough evaluation to rule out potential cardiac or neurological cause of syncope:

1. Syncope during physical exertion
2. Family history of sudden cardiac death or deafness
3. Chest pain
4. History of structural heart disease
5. Abnormal cardiac exam
6. Focal neurological findings

The Modified Calgary Syncope Syndrome Score is a risk-stratification tool that can help guide you in differentiating benign autonomic causes of syncope from serious cardiac causes in children.



## Risk-Stratification Tool: Modified Calgary Syncope Syndrome Score

1. Is there a history of bifascicular block, asystole, or supraventricular tachycardia? (if yes, -5 points )
2. At times have bystanders noted that you **turned blue** during your faint? (if yes, -4 points)
3. Did your syncope start when you were five years of age or younger? (if yes, -3 points)
4. Do you remember anything about being unconscious? (if yes, -2 points)
5. Do you feel faint with **prolonged sitting or standing**? (if yes, +1 points)
6. Do you **sweat** before a faint? (if yes, +2 points)
7. Do you feel faint with **pain or in medical settings**? (if yes, +3 points)

.....

A score of -2.5 has a sensitivity of 95.4% and specificity 67.7% for differentiating cardiac syncope from neurocardiogenic syncope.

A score of -2.5 has a sensitivity of 96.3% and specificity of 72.7% for differentiating cardiac syncope from postural orthostatic tachycardiasyndrome (POTS).

A score lower than -3 means cardiac syncope should be considered.

**Case resolution:** The history is unremarkable for high-risk features. Accucheck is 7.0 mmol/l. Orthostatic vitals are unremarkable. The physical exam is unremarkable. ECG reveals normal sinus rhythm. A urine drug screen was negative. Sammy is sent home with instructions to keep well hydrated during such events and to find a place to sit or lie down at the first signs of dizziness.

## CASE 2: CENTREFIELD COLLAPSE

John is an athletic 14-year-old male who was out with his friends playing football when suddenly he collapsed mid-stride. He spontaneously recovered after about one minute. EMS was called and arrived on scene. On route to the hospital, John told the paramedic that he felt some chest pain and a bit short of breath before he collapsed. John further explained that while working out last week at the gym, he felt chest pain, which made him a bit dizzy. Sal, John's father, arrived at the hospital and mentioned that his brother suddenly died while playing hockey in his 30s, and his son suddenly collapsing reminded him of his brother's story. On physical exam, John was found to have an outflow murmur that increases with valsalva. An ECG was ordered.



**Q: What elements of this case are concerning for a cardiac etiology?**

**A:** The concerning elements of this case for a cardiac etiology are that John collapsed while exerting himself physically, there was no prodrome, and the syncopal event occurred mid-stride. His father, Sal, also tells of a family history of his brother dying of sudden cardiac death at a young age.



### **Clinical Pearl:**

Syncope with cardiac etiology typically includes at least one of the following features which warrants further workup:

1. Exertional syncope
2. Chest pain, palpitations, dyspnea
3. Abnormal physical exam: irregular rhythm, pathological murmur, abnormal heart sound
4. Abnormal ECG
5. Cardiac family history: positive family history or sudden cardiac death before the age of 50



### **Caution:**

Any patient with abrupt syncope with little or an absence of a prodrome must undergo a more extensive evaluation because of an increased risk of serious cardiac disease and risk of future sudden death.



### **Key References:**

In a recent large observational study of pediatric patients presenting to the ED with syncope, a cardiac cause was found in 0.1%. Of these three patients, syncope with exertion, preceded by palpitations, and absence of prodrome were the most significant historic features. The presence of at least two features yielded a sensitivity of 100% and a specificity of 100% for syncope having a cardiac etiology.



**Clinical Pearl:**

An outflow murmur that increases with valsalva or standing is hypertrophic cardiomyopathy until proven otherwise.

John's history is worrisome for cardiac pathology as a cause of his syncope.

**Q: How can the physical exam help you differentiate the serious causes of syncope?**

**A:** An outflow murmur that increases with valsalva or standing is hypertrophic cardiomyopathy (HCM) until proven otherwise. Another etiology of syncope that can occur with exertion and reveals an outflow murmur that is important to recognize is aortic stenosis.

HCM is one of the most common inherited cardiac disorders (affecting ~ 1 in 500 people) and is the number one cause of sudden cardiac death in young athletes. Hypertrophic obstructive cardiomyopathy (HOCM) is a subset of HCM and is characterized by left ventricular outflow tract obstruction—systolic anterior motion of the mitral valve and impingement on the hypertrophied basal septum. In the majority of cases (75%), HCM is not associated with left ventricular outflow obstruction.

Aortic stenosis is another cause of syncope that can occur with exertion. A mid-systolic ejection murmur is heard at the right upper sternal border, with radiation into the neck. The murmur decreases with valsalva or standing, and increases with handgrip or squatting. The murmur of aortic stenosis has the opposite characteristics of the murmur heard in HCM.



**Clinical Pearl:**

Signs of serious physical injury on physical exam, such as facial trauma or head injury, are more suggestive of a serious cardiac etiology.



**Q: We know that an ECG is the single most important test in evaluating patients after a syncopal episode. What is your general approach to interrogating the ECG of a patient who has a history of syncope?**

**A:** The intervals to interrogate on the ECG of patients who present to the ED with syncope:

- **PR interval:**
  - Short PR: Wolff-Parkinson-White (WPW) syndrome
  - Long PR: AV conduction block
- **QRS interval:**
  - Narrow, deep QRS: Hypertrophic obstructive cardiomyopathy
  - Wide QRS: Ventricular tachycardia, WPW syndrome
  - Wide QRS + epsilon waves: Arrhythmogenic RV hypertrophy
- **QT interval:**
  - Long QT syndrome, short QT syndrome



**Clinical Pearl:**

ECG interpretation in patients who present with syncope is all about the **ECG intervals!**

Plus interrogate the ECG for:

1. Brugada syndrome
2. Ischemia
3. Pulmonary embolism



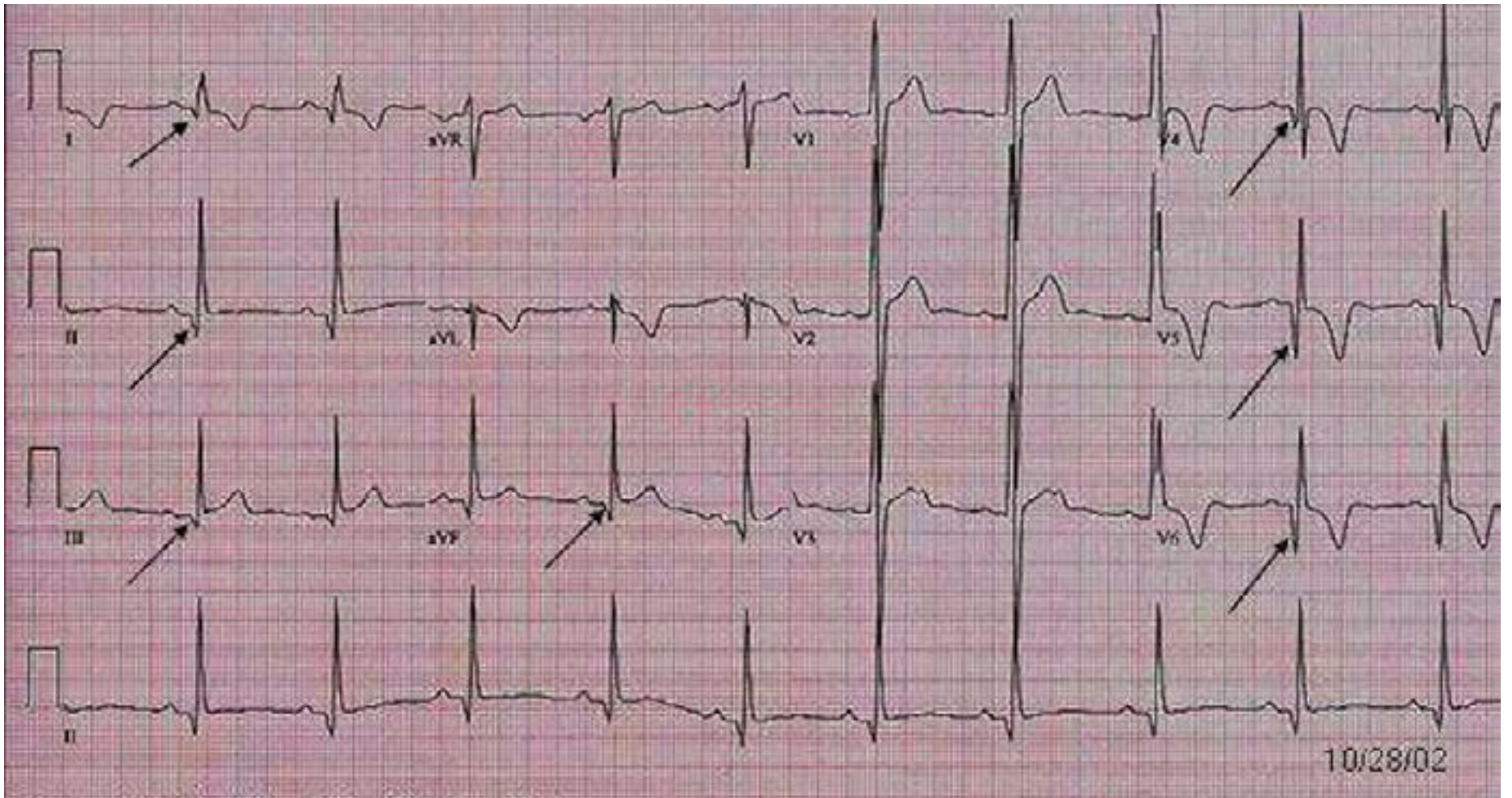
**Caution:**

Comotio cordis is a life-threatening dysrhythmia causing cardiac arrest, often confused with syncope. The cause is a direct, non-penetrating, low-impact blow to the chest, directly over the heart (the precordial region), at a critical time during the heart cycle. Comotio cordis often occurs during sporting events, but has been reported to occur as a result of abuse, fighting, snowballs, and hollow plastic toys. Ventricular fibrillation is the most common dysrhythmia, but heart block, ventricular tachycardia, bundle branch block, ST abnormalities, and asystole can occur.

**Q: What do you expect the ECG to look like in patients with HCM?**

**A:** ECG findings of HCM include:

- Increased QRS complex voltage (“Dagger-Like Q waves”)
- ST-segment and T-wave signs of LV hypertrophy
- Q-waves in leads II, III, aVF, V5, V6



ECG showing signs of HCM: Dagger-like Q waves in inferior and lateral leads. Courtesy of *Life in the Fast Lane* blog.



**Caution:**

HCM is the most common cause of sudden death during exercise in young adults and children!

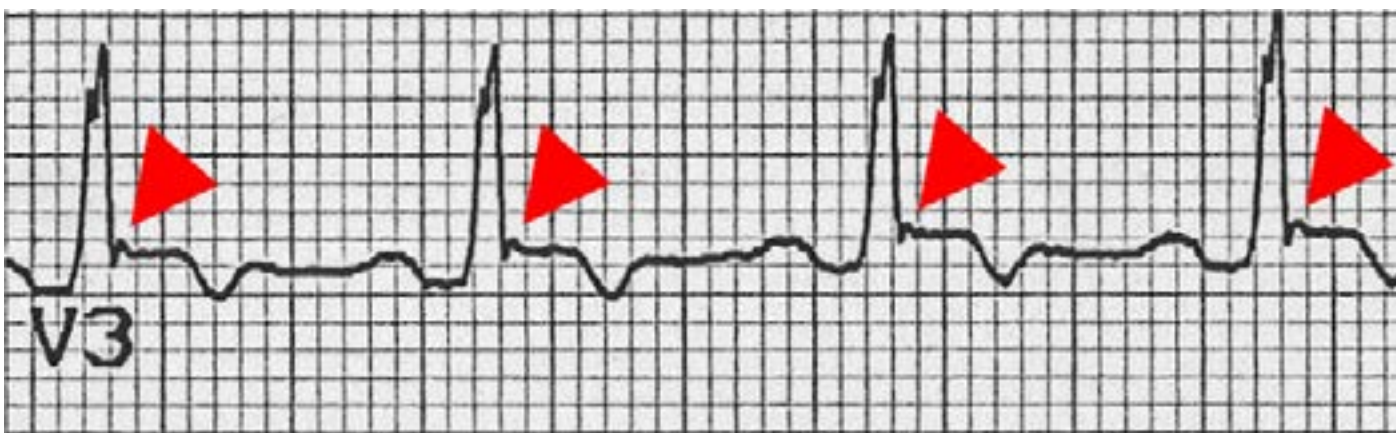
**Q: What else can be done at the bedside to support your diagnosis of HOCM?**

**A:** Bedside ultrasound can reveal a dilated, hypertrophic myocardium. Assessment for fluid status evaluation (IVC), tamponade/contractility (cardiac), and free fluid in the abdomen can rule in or rule out other causes of syncope.

*[Video: Click here to watch a video of HOCM on echocardiography.](#)*

**Q: What is arrhythmogenic right ventricular cardiomyopathy (ARVC), and what are the typical ECG findings?**

**A:** ARVC is a genetic disorder leading to cardiac fibro-fatty changes, which may result in sudden cardiac death in young people.



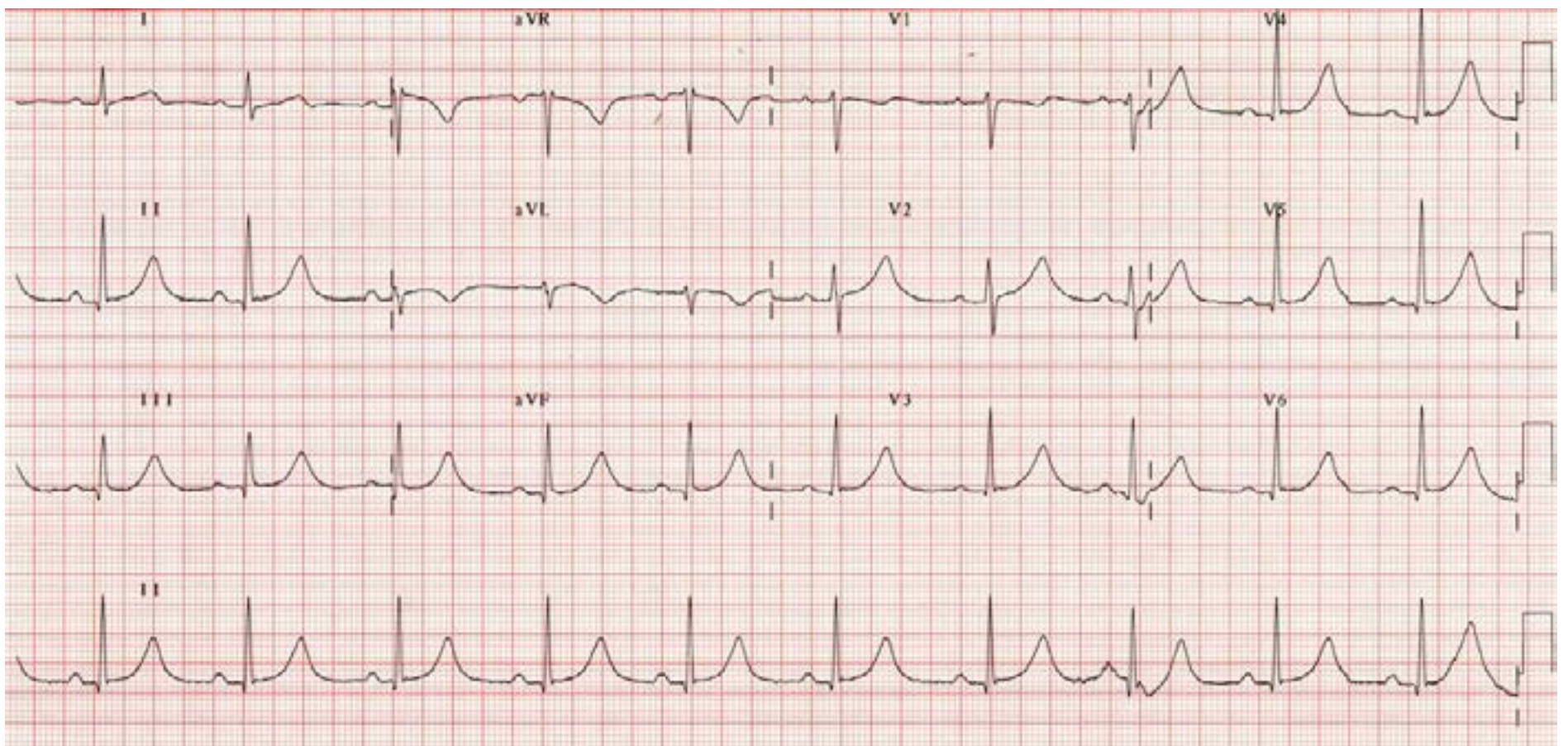
The classic ECG findings of ARVC are:

- Inverted T waves in right precordial leads (V1, V2, V3)
- QRS in Lead 1 > 110 msec
- **Epsilon waves** (low amplitude notches after QRS and before T wave) in the right precordial leads (V1- V3)



**Q: Is benign early repolarization (BER) really benign?**

**A:** BER is common in young, otherwise healthy people and has historically been considered to portend no significant clinical sequelae. However, recently a BER pattern in the inferolateral leads has been found to be associated with ventricular fibrillation in a small subset of patients. Consider referring patients with a BER pattern in the inferolateral leads who present to the ED with syncope to a cardiac electrophysiologist.



ECG showing a benign early repolarization pattern in the inferolateral leads. This pattern may predispose patients to ventricular fibrillation.

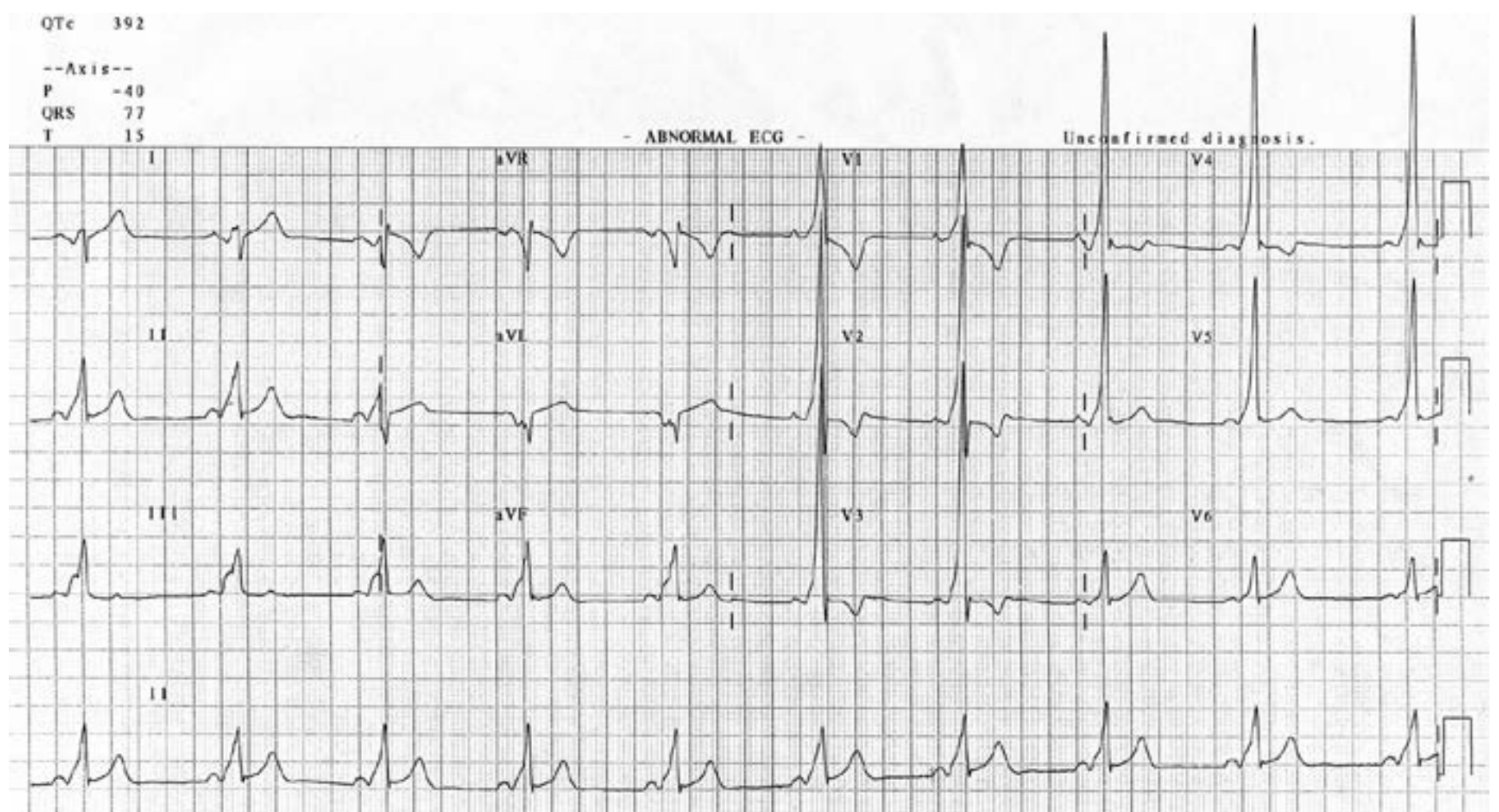


**Clinical Pearl:**

Acquired heart block found on ECG can be caused by infectious myocarditis (most commonly Lyme disease), neonatal lupus, congenital heart disease, or cardiomyopathy. Second- and third-degree heart block in the setting of syncope usually requires urgent placement of a cardiac pacemaker.

**Q: How would you describe an ECG with WPW characteristics?**

- A:**
- Short PR interval of less than three small squares (120 ms)
  - Slurred upstroke to the QRS indicating pre-excitation (delta wave)
  - Broad QRS
  - Secondary ST and T wave changes



ECG showing WPW syndrome. Courtesy of *Life in the Fast Lane* blog.



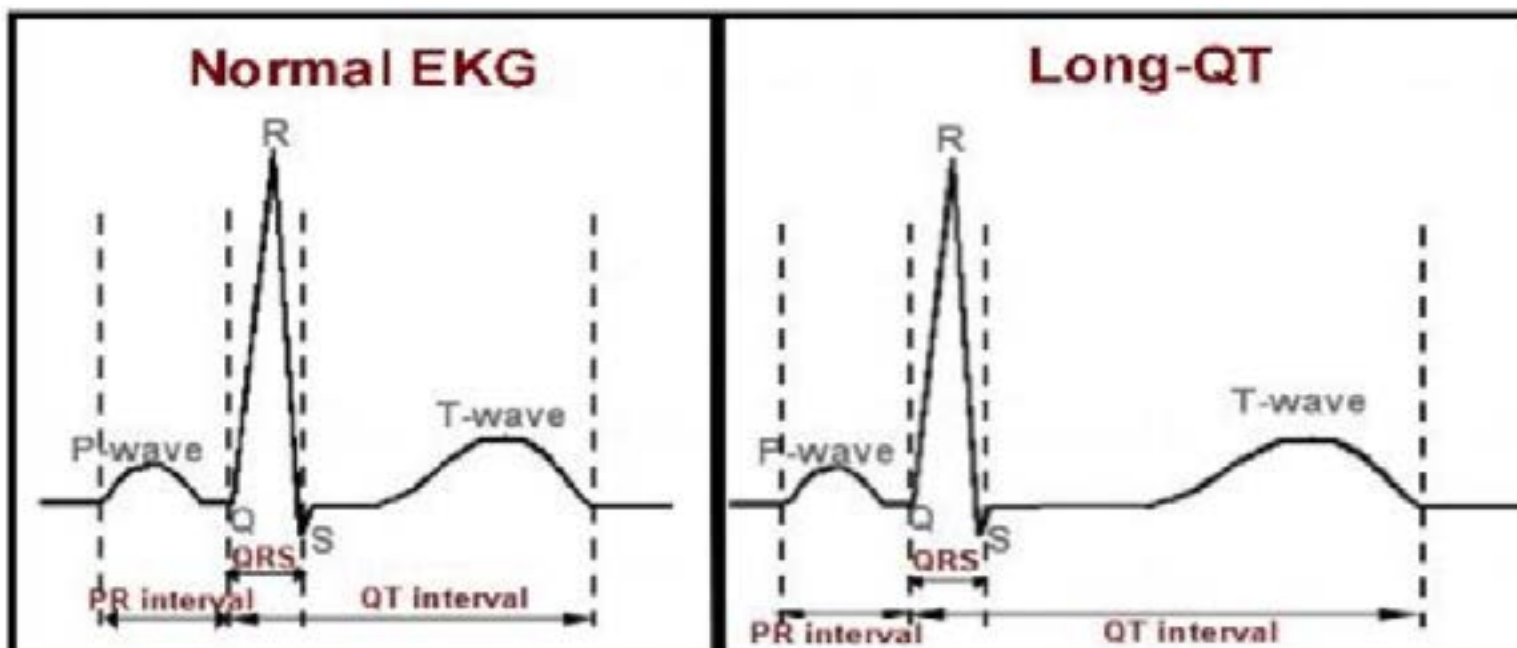
**Clinical Pearl:**

Atrial arrhythmias are rarely associated with syncope, with the important exception of WPW syndrome.



**Q: What is the typical story of a patient who suffers a syncopal episode as a result of long QT syndrome?**

**A:** The history of pediatric patients who present to the ED with syncope related to long QT syndrome typically involves exertion such as swimming, or emotional distress. These patients can also suffer an abrupt onset of syncope due to fright or awakening by a loud noise, such as an alarm clock. Congenital long QT is often associated with congenital deafness. Many medications as well as hypokalemia, hypocalcemia, and hypomagnesemia can result in a prolonged QT interval that may trigger the syncopal episode.



Normal ECG versus ECG with long QT, Courtesy of [www.washingtonhra.com](http://www.washingtonhra.com).

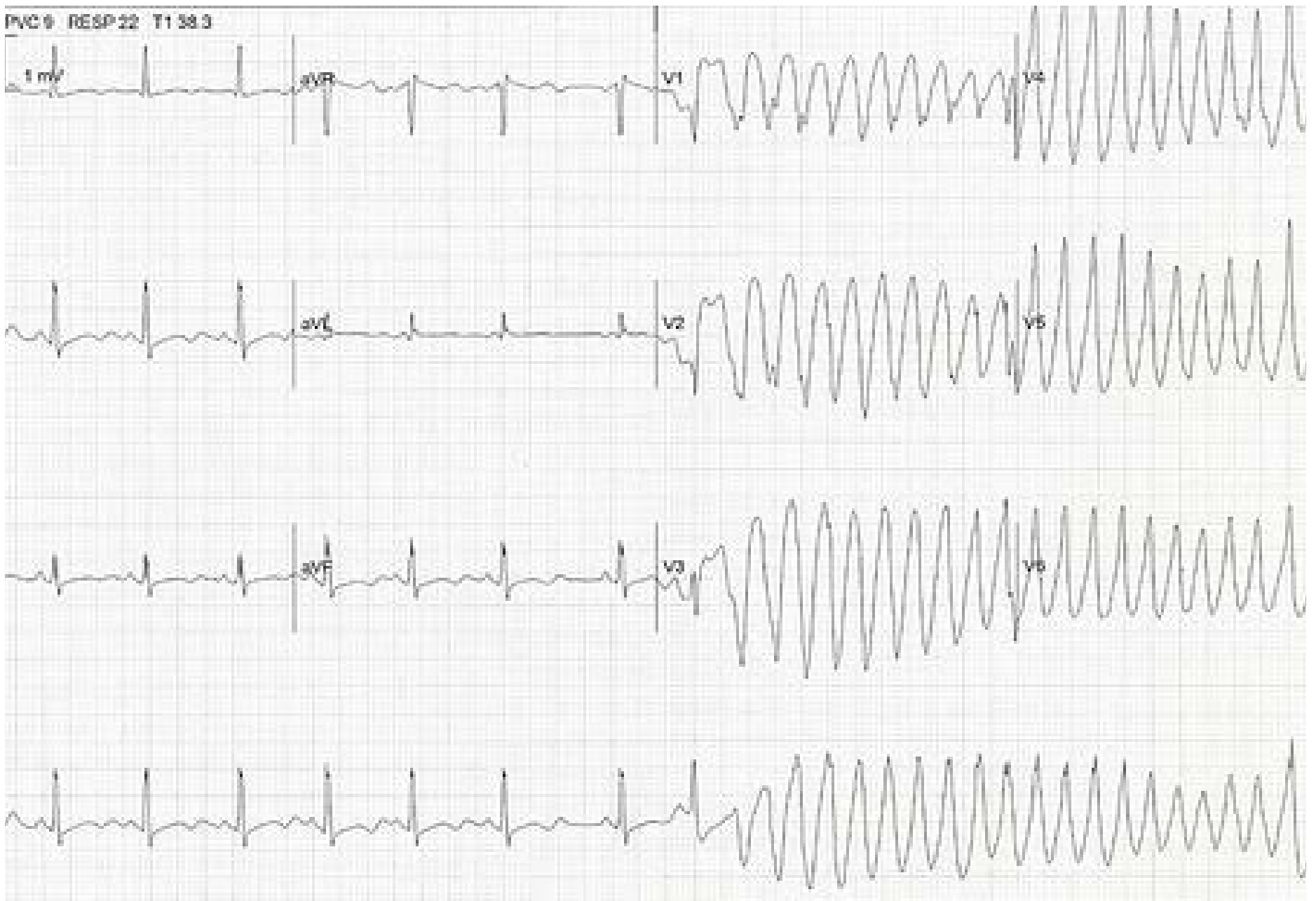


**Clinical Pearl:**

While a QTc interval  $> 500$  is considered high risk for torsades de pointes and sudden death, in children a QTc interval  $> 450$  is considered high risk warranting referral to an cardiac electrophysiologist.

Short QT syndrome (QTc  $< 340$ , or  $< 360$  in patients with a family history of sudden death) is also a rare but lethal ECG finding, and must be investigated.

[Click here for a list of medications to avoid in patients with long QT.](#)



*Long QT leading to torsades de points*

**Q: Can Brugada syndrome occur in children?**

**A:** Brugada syndrome is rare in children. It usually occurs in adulthood between the ages of 22 to 65. An Ajmaline challenge test at the start of puberty in asymptomatic patients with a family history of Brugada syndrome can unmask Brugada ECG changes. Brugada ECG changes are more likely to occur during febrile illnesses.



**Caution:**

Sudden cardiac death may be the first and only presenting symptom of Brugada syndrome.

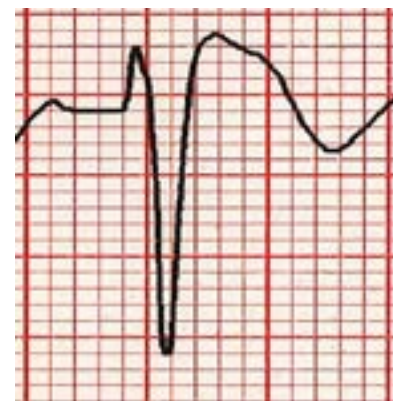
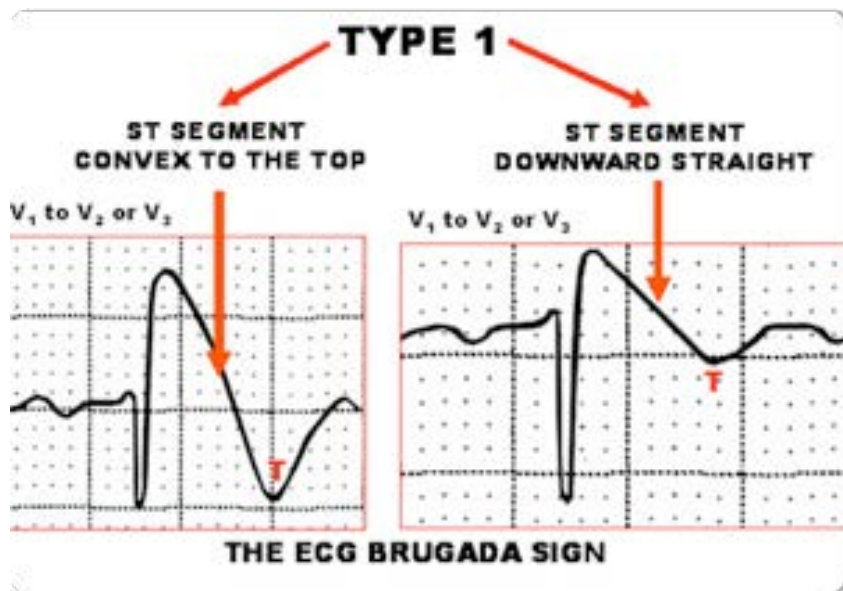




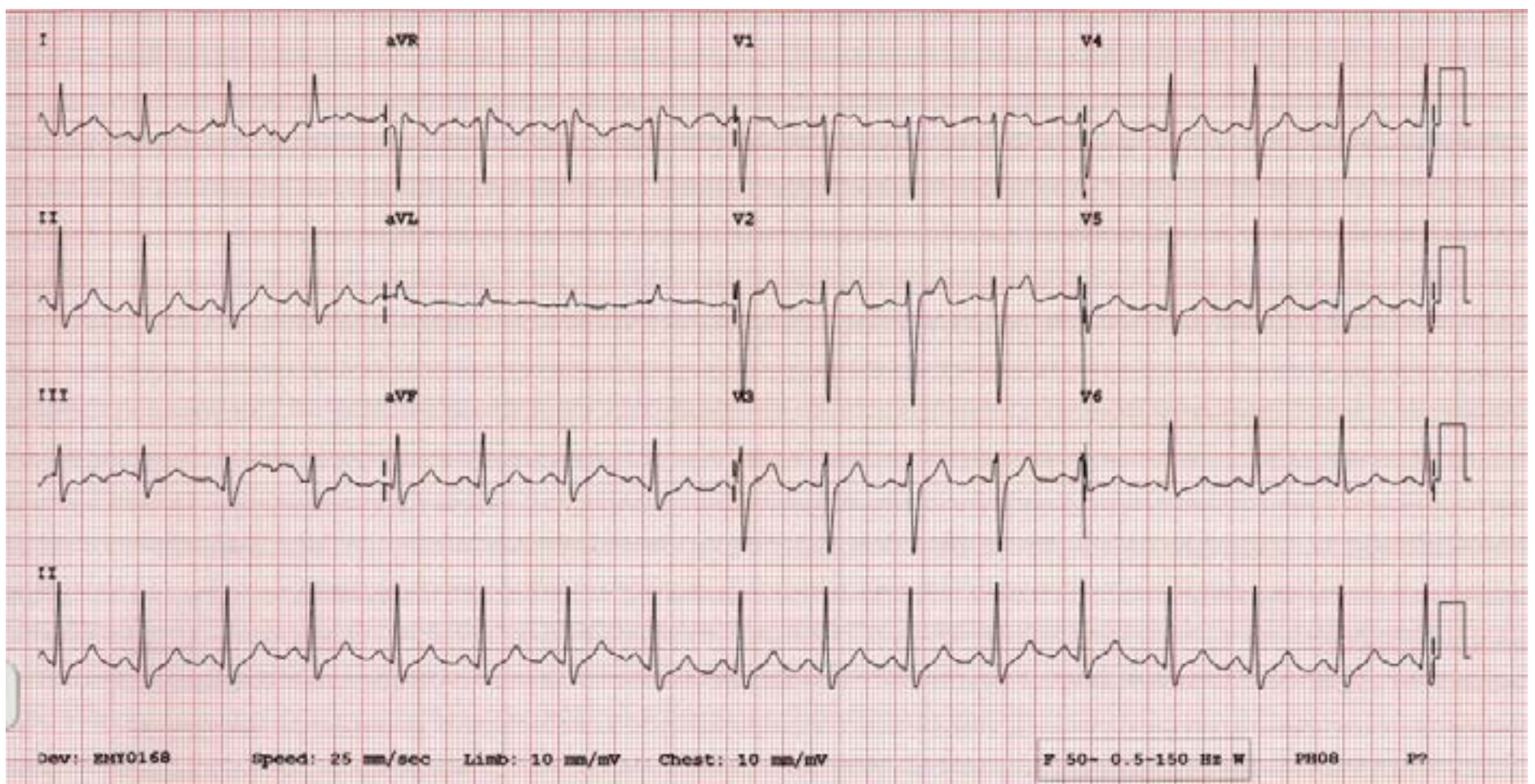
## Clinical Pearl:

The ECG of a patient with Brugada syndrome is divided into two types:

- Type 1 shows a pseudo-RBBB pattern with a triangular-shaped ST elevation in the anterior precordial leads (V1 to V3)
- Type 2 shows a  $> 2\text{mm}$  of saddleback-shaped ST elevation



Type 1 Brugada sign



Type 2 Brugada sign. Courtesy of *Life in the Fast Lane* blog.

**Q: What lab tests would you consider ordering in a patient with syncope who has an ECG showing a prolonged QT interval?**

**A:** Routine blood tests are of low diagnostic value in patients who present to the ED with syncope. However, in a patient whose ECG shows a prolonged QT interval, an electrolyte panel may be revealing as hypokalemia, hypocalcemia, and hypomagnesemia can all cause a prolonged QT interval.



**Caution:**

Some of the more common medications that can prolong the QT interval include the following:

- Tricyclic antidepressants
- Antipsychotics
- Macrolide antibiotics
- Antihistamines

**CASE 3:  
BREATHLESS & BLUE**

Sarah is a 14-month-old girl brought in to the ER by her nanny after “fainting” this afternoon. Sarah was playing with the household cat, Patches, when the cat swatted and scratched her arm. Sarah gave a loud cry and then stopped breathing, according to the nanny. She then turned pale, then blue, and her body jerked a couple of times before going limp. After about 30 seconds, Sarah gasped for air, followed by a few deep inspirations, and she returned to normal.

**Q: What are the two main types of breath holding spells and how do they present?**

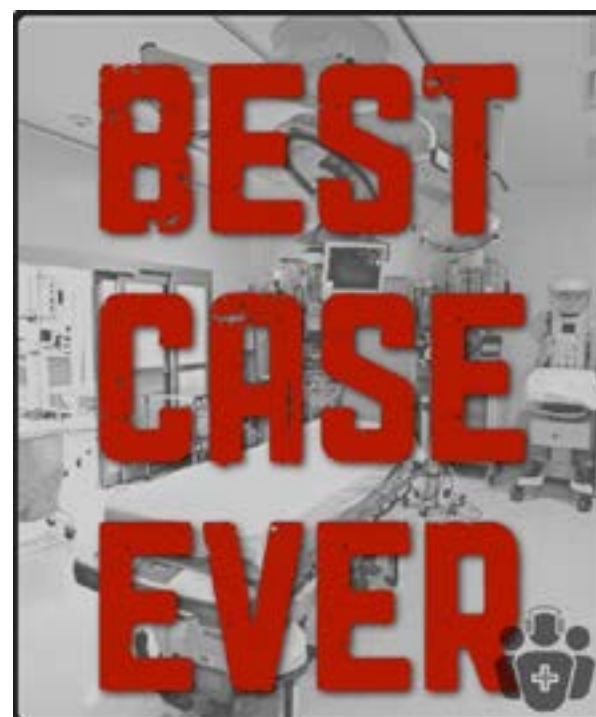
**A:** Breath-holding spells are seen in children between six months and 24 months of age. There are two forms, cyanotic and pallid. The cyanotic form occurs at six months of age, peaks at two years, and is completely gone at 5 years. The episode is



brought on by injury or pain resulting in a loud cry followed by apnea. The pallid form occurs between 12 months and 24 months, and is also brought on by injury or pain, similar to the cyanotic form. There is no crying (in contrast to the cyanotic form) and the loss of consciousness occurs quickly. No treatment is required.

In the cyanotic form, the child turns pale or cyanotic. There may be jerky or myoclonic movements followed by the body going limp. The entire episode lasts less than one minute.

In the pallid form, the child turns pale and hypotonic, and develops rhythmic muscle contractions. On cardiac monitoring, the episodes are associated with bradycardia and/or asystole.



[Want more syncope stories?](#)  
[Listen to Dr. Jarvis' Best Case Ever for more helpful tips and memorable stories!](#)



### **Clinical Pearl:**

Cough can cause syncope called tussive syncope. It is often associated with bronchospasm from acute infection, asthma, pertussis, or cystic fibrosis. The paroxysms of coughing cause high intrathoracic pressure and reduced cardiac output.



### **Comments?**

[Click here to leave a comment or to listen to this podcast.](#)

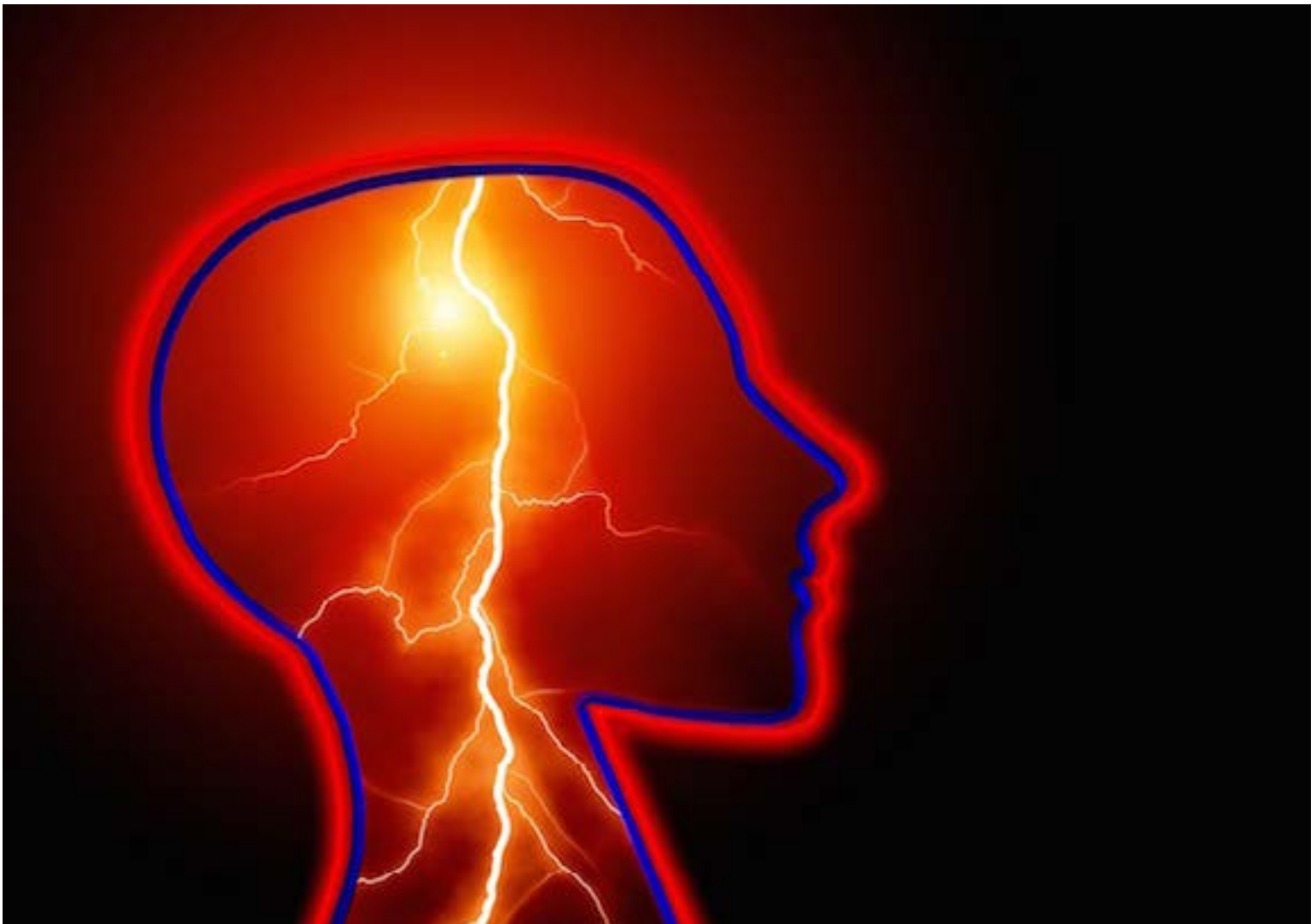

## KEY REFERENCES:

1. Kaniwal K, Calkins H. Syncope in children and adolescents. *Cardiol Clin*. 2015; Aug;33(3):397-409.
2. Tretter JT, Kavey RE. Distinguishing cardiac syncope from vasovagal syncope in a referral population. *J Pediatrics*. 2013; Dec;163(6):1618-23.
3. Yang J, Zhu L, Chen S, et al. Modified Calgary score in differential diagnosis between cardiac syncope and postural orthostatic tachycardia syndrome-associated syncope in children. *Cardiol Young*. 2013; Jun23(3):400-4.
4. Timmermans C, Smeets JL, Rodriguez LM, Vrouchos G, van den Dool A, Wellens HJ. Aborted sudden death in Wolf-Parkinson-White syndrome. *Am J Cardiol*. 1995; Sep;76(7):492-494.
5. Brugada J, Brugada R, Brugada P. Right bundle branch block and ST segment elevation in leads V1 through V3. *Circulation*. 1998; Feb;97(5):457-60.
6. Prodinge RJ, Reisdorff EJ. Syncope in children. *Emerg Med Clin North Am*. 1998; Aug;16(3):617-26.
7. Maron BJ. Hypertrophic cardiomyopathy: a systematic review. *JAMA*. 2002; Mar;287(10):1308-20.
8. Maron BJ. Sudden death in young athletes. *N Engl J Med*. 2003; Sep;349(11):1064-75.
9. Gersh BJ, Maron BJ, Bonow RO, et al. ACCF/AHA guidelines for the diagnosis and treatment of hypertrophic cardiomyopathy: a report of the American College of Cardiology Foundation/American Heart Association Task Force on Practice Guidelines. *J Am Coll Cardiol*. 2011; Dec;58(25):2703-38.
10. Probst V, Denjoy I, Meregalli PG, et al. Clinical aspects and prognosis of Brugada syndrome in children. *Circulation*. 2007; Apr;115(15):2042-8.
11. Haïssaguerre M, Derval N, Sacher F, et al. Sudden cardiac arrest associated with early repolarization. *N Engl J Med*. 2008; May;358(19):2016-23.
12. Hurst D, Hirsh DA, Oster ME, et al. Syncope in the pediatric population emergency department -- can we predict cardiac disease based on history alone? *J Emerg Med*. 2015; Jul;49(1):1-7.
13. DiMario FJ. Prospective study of children with cyanotic and pallid breath holding spells. *Pediatrics*. 2001; Feb;107(2):265-9.
14. Steinberg LA, Knilans TK. Syncope in children: diagnostic tests have a high cost and low yield. *J Pediatr*. 2005; 146:355-8.
15. Zangwill SD, Strasburger JF. Commotio cordis. *Pediatr Clin North Am*. 2004; Oct;51(5):1347-54.

# CHAPTER 17: PEDIATRIC SEIZURES

[LISTEN TO THE PODCAST WITH LAWRENCE RICHER & ANGELO MIKROGIANAKIS HERE](#)



## Objectives

1. Differentiate between benign febrile seizures and complex febrile seizures
2. Learn the appropriate workup for both febrile and non-febrile seizures
3. Review the management of seizures in the emergency department
4. Know the medication options for status epilepticus

## CASE 1: THE BLUE CHILD

A 14-month-old boy is brought in by his mother as she is worried that he had a seizure at home. He was playing quietly on the living room floor and his mother stepped briefly into the kitchen. She heard a bang, then a cry, and went running into the room to find her son lying on the floor looking a bit blue. He made a couple of jerky movements and then started to move and breathe normally. After the episode, he woke up within minutes and was completely back to normal on arrival in the ED. His vital signs were normal and he was happily playing with his mother in the examination room.

**Q: How can we determine if what parents witnessed at home was truly a seizure? What conditions can be mistaken for seizure?**

**A:** Much of this is going to hinge on the history. Ask about the onset; duration and nature of the movements; tongue biting; eye findings and the recovery phase after the episode. The level of responsiveness during the episode is also important, as parents can sometimes mistake rigors for seizure activity. The recovery phase is critical, as a rapid/immediate return to normal activity is unlikely to follow a true seizure. Breath-holding spells, syncope, and pseudoseizures can be difficult to differentiate from true seizures.



### **Clinical Pearl:**

Elements highly suggestive of seizure activity include:

- Postictal phase
- Lateral tongue biting
- Flickering eyelids
- Blank stare or deviated eyes
- Lip smacking
- Increased heart rate and blood pressure during the event

**Q: This child turned blue, which can be seen with a breath-holding spell. How do you distinguish breath-holding spells from true seizures?**

**A:** Breath-holding spells are most common in the six-to-18-month age range. Usually there is a clear trigger, such as emotional distress or pain. The episode can still involve very brief seizure activity due to temporary decrease in cerebral oxygenation. Recovery is rapid and complete as there is no postictal phase.

**Q: Could this 14-month-old have had a pseudoseizure? How do you distinguish pseudoseizures from true seizures?**

**A:** Pseudoseizures tend to be seen in the adolescent population since younger children cannot feign seizure activity for secondary gain. As such, this 14-month-old did not have a pseudoseizure. Pseudoseizures can be difficult to distinguish from true seizures, particularly on history. They are often easier to diagnose if witnessed directly in the emergency department. Movements may include side-to-side motion of the head, back arching, asynchronous movements (e.g., bicycling). The level of consciousness may be preserved and patients may respond during the episode.

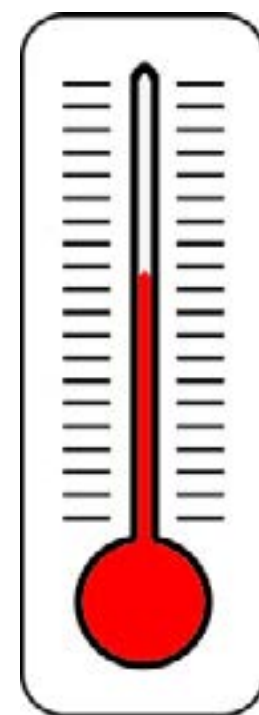
**Q: On further questioning the parents, there is a family history of sudden death at an early age, and you wonder whether this child could have suffered a syncopal episode rather than a seizure. How do you distinguish syncope from true seizure?**

**A:** In a syncopal episode, loss of consciousness precedes any abnormal movements. The patient may have a few myoclonic twitches but should not have ongoing tonic-clonic movements. Recovery is rapid and complete.

For more on pediatric syncope, go to [Chapter 16: Pediatric Syncope](#).

## CASE 2: FEBRILE SEIZURES

Panicked parents bring their eight-month-old to your Emergency Department. Thirty minutes ago, they saw their daughter suddenly become unresponsive and start shaking. The episode lasted about five minutes, and the child is now waking up. They mention that she has had a fever for the past four days and they have been giving her acetaminophen for this at home. She has not had any respiratory or GI symptoms over the past few days. She is otherwise healthy and fully immunized.



On exam, the child is awake but a bit drowsy. She has moist mucous membranes and normal capillary refill. Her neck is supple, she is moving all four limbs well and is beginning to interact with her parents. Her vital signs are normal other than a temperature of 38.3°C. Her ENT and respiratory exams are normal and her abdomen is benign. She does not have a rash. As you are examining her, she begins to seize again.

**Q: You are convinced by both the history and seizure you see in the emergency department that this child has had a seizure associated with a febrile illness. The distinction between simple versus complex febrile seizures is important, as complex febrile seizures may indicate a more serious underlying disease process and warrant a workup. How do you distinguish simple from complex febrile seizure clinically?**

**A:** A diagnosis of complex febrile seizures is made if there is any deviation from the criteria of a simple febrile seizure.

	Simple	Complex
<b>Age</b>	6 months – 5 years	Any
<b>Frequency</b>	Single seizure in 24 hours	Multiple seizures in 24 hours
<b>Nature</b>	Generalized	Generalized or focal
<b>Duration</b>	< 15 mins	Can be prolonged
<b>Recovery</b>	Return to baseline after short post-ictal period	May not return fully to normal if multiple seizures





### Clinical Pearl:

Simple febrile seizures tend to occur within the first 24 hours of a febrile illness. If the seizure occurs > 24 hrs after the onset of fever as in this case, the index of suspicion for a serious bacterial illness should be heightened.

**Q: A repeat temperature is taken that shows a temp of 39.7°C. The parents are very concerned about the “dangerously high fever.” Does the height of the fever correlate with the chances of having a febrile seizure?**

**A:** The height of fever does not correlate with seizures; however, the rapidity of the rise in temperature is thought to correlate with the occurrence of seizures.

**Q: You’ve decided that this child has suffered a simple febrile seizure. Does she require blood work? Urinalysis? X-rays? What workup is required for a patient with a simple febrile seizure?**

**A:** No dedicated seizure workup is required for simple febrile seizures. The workup should focus on looking for the source of the fever, and the approach should be the same as if the child had only the fever with no seizure. The child with a simple febrile seizure is at no greater risk for serious bacterial infection than age-matched controls with fever who have not seized.

For more on pediatric fever go to [Chapter 1 on Fever Without a Source](#).

**Q: What workup is required for a patient with a complex febrile seizure?**

**A:** The workup of complex febrile seizures requires a stepwise approach given the wide breadth of presentations in this category. Keep in mind that the younger the child, the more aggressive the workup should be. Children who return to baseline after a complex seizure and at no point displayed any focal neurologic symptoms usually do not require an extensive workup. Even though studies have shown that febrile seizures do not increase the risk of serious bacterial infection compared with fever alone, meningitis should always be on the differential diagnosis in a child with complex febrile seizures. About 25% of children with meningitis will present with a new onset febrile seizure; however, they will almost always display persistent mental status abnormalities along with other signs of meningitis, such as nuchal rigidity, focal seizures, and petechia.

If the seizure was focal, one should consider CNS infection, neuroimaging, and EEG testing. Otherwise, in the child older than six months who has had somewhat prolonged or multiple seizures in 24 hours, a combination of limited testing and observation with frequent reassessment is reasonable. Initial tests generally include CBC, glucose, electrolytes, and urinalysis.



**Q: Let's say that this child looked toxic after a complex febrile seizure. Would you perform a lumbar puncture? What are the indications for doing a lumbar puncture in a child with a febrile seizure? Would you send the patient for a CT scan of the head? When would you consider neuroimaging in the ED in the child with a febrile seizure?**

**A:** There is no clear, exhaustive list of indications for doing a lumbar puncture, so some clinical judgment must be used.



### **BMJ Article on Febrile Seizures (2015)**

Red flags to warrant considering a lumbar puncture:

- Postictal symptoms lasting > one hour
- Any physical exam signs of meningitis (bulging fontanelle, neck stiffness, focal neurologic deficits, photophobia, petechial rash)
- Irritability or lethargy
- Already on antibiotics
- Incomplete immunization (HiB and *Strep pneumo*)
- Complex febrile seizures



Indications for neuroimaging in the ED in the child with a febrile seizure:

- Suspicion of non-accidental injury
- Signs of increased ICP
- Patient who does not return to neurologic baseline
- Underlying known CNS disorder (e.g., VP shunt)

**Q: You diagnose this child with a viral illness and simple febrile seizure and decide to send her home. What discharge instructions will you give the parents?**

**A:**

**Safety:** Place the child in the recovery position and do not place anything in the child's mouth

**Risk of recurrence** is approximately 33% overall, with a higher risk in children with these risk factors:

- Younger than 18 months
- Temperature < 40.0°C at first convulsion
- Less than one hour between onset of fever and first seizure
- Family history of febrile seizures

If the child has all four of the risk factors, the risk of recurrence is 70%. If the child doesn't meet any criteria, the risk falls to 20%.

**Risk of epilepsy** is approximately 2% after a simple febrile seizure and 5% after a complex febrile seizure (compared with 1% in the general population)

**Q: As you're about to discharge this child, the parents ask you about how to keep the child's fever at bay to prevent another seizure from occurring. Does the use of antipyretics alter the risk of febrile seizure?**

**A:**



**Clinical Pearl:**

Parents will often blame themselves for not treating the seizure appropriately or quickly enough to prevent the seizure. It is important to educate them that the height of the fever does not predict risk of suffering a seizure, and that prophylactic antipyretics do not have any effect on the rate of seizure recurrence.

## CASE 3: NON-FEBRILE SEIZURE

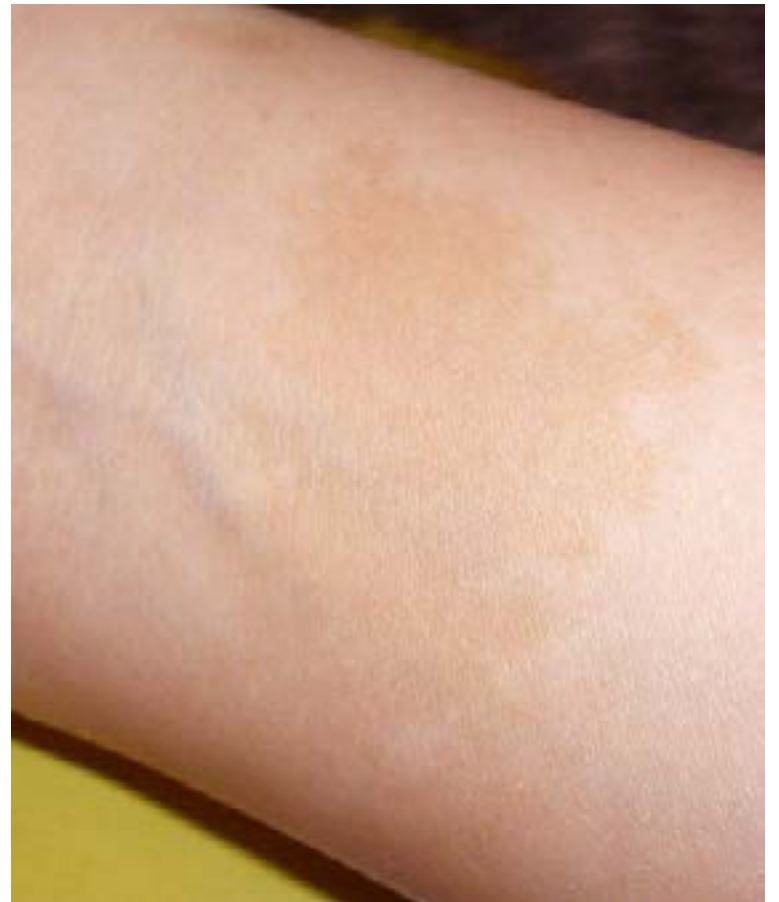A two-month-old girl is brought in to the ED by her parents. Over the past 24 hours she has become increasingly drowsy. She has no fever, respiratory symptoms or GI symptoms. Thirty minutes ago, the parents witnessed what you determine to be a generalized tonic-clonic seizure lasting two minutes. She is now beginning to rouse. The infant was born at term with no issues during pregnancy or with the delivery. She is otherwise healthy. There is no family history of seizure disorders.

On exam, the infant is drowsy but rousable, and has reasonable tone. Her mucous membranes are moist and capillary refill is normal. Vitals are normal and her rectal temperature is 36.1°C. Her ENT, chest, abdominal, and skin exams are unremarkable.

**Q: What specific physical exam findings are you looking for when you examine this two-month-old girl after her non-febrile seizure?**

**A:** The physical exam is tailored to looking for potential underlying causes for the seizure:

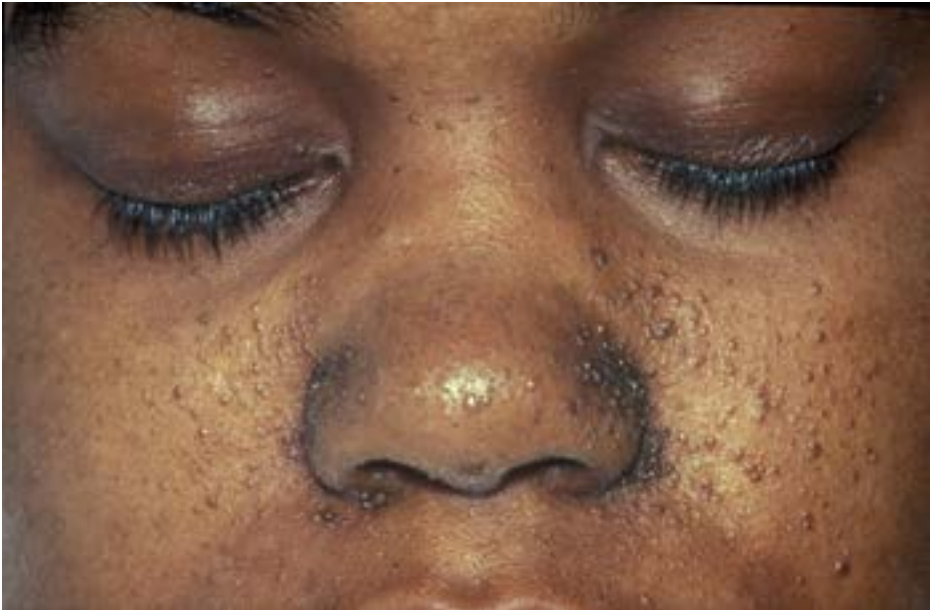**Skin:** Look for lesions such as *café au lait* spots (neurofibromatosis), angiofibromas or ash leaf spots (tuberous sclerosis), or port-wine stains (Sturge-Weber syndrome). Unexplained bruising raises suspicion for bleeding diathesis or non-accidental injury.



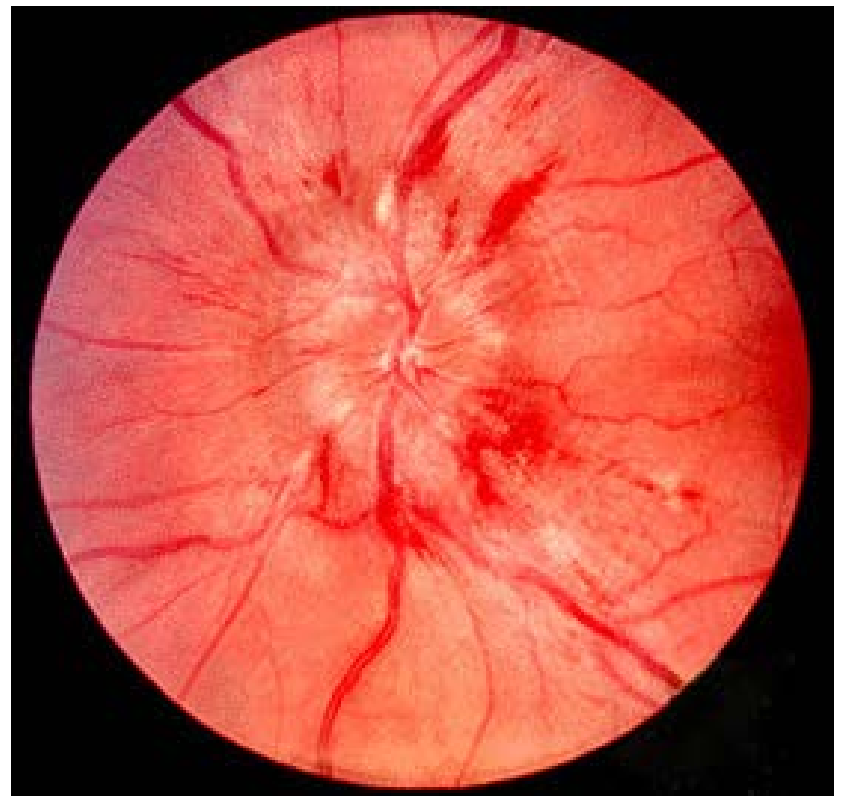Café au lait spots



Port-wine stain



Angiofibromas



Papilledema and retinal hemorrhages

**Eyes:** Papilloedema and retinal hemorrhages

**Head:** Bulging fontanelle, head circumference, dysmorphic features, signs of trauma

**Neck:** Signs of meningeal irritation

**Abdomen:** Hepatosplenomegaly may indicate a metabolic or glycogen storage disease



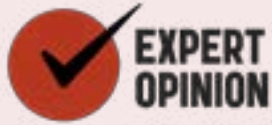**Pitfall:**

Children younger than two years of age who present to the ED with a non-febrile seizure are almost always found to have a worrisome underlying etiology, as apposed to epilepsy. Even if the history and physical do not reveal any obvious etiology for the seizure, these patients need further assessment to rule out ominous causes of their seizure.

**Q: Does this child require laboratory studies in the ED?**

**A:** Lab tests may not be necessary for the child who has suffered a brief seizure and is now alert and back at baseline level of function. A thorough history and physical exam in patients who have no identifiable risk factors have been shown to yield more diagnostic information than a laboratory evaluation.





Consider ordering labs on patients who:

- Suffer prolonged seizures
- Are younger than six months of age
- Have a history of diabetes, metabolic disorder, dehydration, or excess free water intake
- Have a persistent altered level of awareness or other neuro deficits
- Are taking an anticonvulsant medication whose serum levels can be assessed

**Q: Which laboratory studies are required in the ED?**

**A:** Specific laboratory tests should be guided by the clinical assessment. Some tests to consider are:

- Capillary glucose
- CBC
- Electrolytes including sodium, calcium, and magnesium
- Ammonia (for inborn errors of metabolism)
- Toxicology screen
- Serum level of anticonvulsant (if patient is already on an anticonvulsant medication)
- ECG (if you are considering syncope for a cardiac cause of event; e.g., long QT)

**Q: Would you order a CT scan on this two-month-old girl who has suffered a non-febrile seizure? Why or why not?**

**A:** Neuroimaging is generally not necessary in the ED in a child after a non-febrile seizure who returns to neurologic baseline. This child has not returned to her baseline level of awareness, and so neuroimaging might be a reasonable consideration.

Some high-risk criteria for finding a culprit lesion on a CT scan of the head are:

- Focal seizure or persistent seizure activity
- Focal neurologic deficit
- VP shunt
- Neurocutaneous disorder suggested on skin exam
- Signs of elevated increased ICP
- History of trauma
- Travel to an area endemic for neurocysticercosis
- Immunocompromised state
- Hypercoagulable state (e.g., sickle cell disease) or bleeding disorder

**Q: The head CT is interpreted as normal and the laboratory tests come back showing a serum sodium level of 115. What is the most likely cause of this child's seizure?**

**A:** The differential diagnosis of non-febrile pediatric seizures is extensive, encompassing metabolic derangements to mass lesions to non-accidental trauma. However, in this case the most likely cause is hyponatremia secondary to over-dilution of infant formula.



**Clinical Pearl:**

One particular diagnosis that is one of the more common causes of non-febrile seizure in children younger than six months of age and is relatively easy to pick up (thus avoiding an extensive invasive workup) is hyponatremia secondary to formula over-dilution. In a paper from the *Annals of Emergency Medicine*, hyponatremia was the cause of seizures in 70% of 47 infants younger than six months of age who lacked other findings suggesting a cause.

On further questioning, you find out that this child's parents have indeed been watering down the infant formula.

**Q: You decide to consult the pediatric team. While you are waiting to for them to arrive, the child seizes again. What medications will you administer to this child besides the usual benzodiazepines?**

**A:** For children with seizures as a result of severe hyponatremia, 3 cc/kg of hypertonic (3%) saline IV bolus is recommended.

**Q: While this child requires admission to hospital, some children who have suffered a non-febrile seizure can be discharged home safely. Which children can be safely discharged from the ED after a non-febrile seizure?**

**A:**  **EXPERT  
OPINION**

**< Six months:**

Generally require a full workup and are usually admitted for observation.

**Six to 24 months:**

Disposition will depend on blood work, reassessment, and the ability to have close follow-up for an EEG +/- MRI.

**> 24 months:**

Those who have returned to baseline and have a normal neurological exam with normal workup are often safe to be discharged to close outpatient follow-up for EEG +/- MRI. Otherwise, admit.

**Q: Suppose that this patient was not found to have any underlying etiology for her non-febrile seizure. What is the risk of recurrence after a non-febrile seizure?**

**A:** Approximately 50% of patients with first episode non-febrile seizure will have a recurrent seizure. The decision to start an anticonvulsant medication will generally not be made in the ED. Arrange follow-up either with general pediatrics or pediatric neurology, who will usually do an EEG and possibly an MRI in order to risk-stratify those who may require anticonvulsant medications.

## CASE 4: STATUS EPILEPTICUS

A three-year-old boy is brought in by an EMS crew. The mother called 911 after her son seized at home, and en route to hospital the child began to seize again. By the time they arrive in your ED the child had been seizing continuously for eight minutes.



**Q: What are your initial priorities in the management of this case?**

**A:** Initial interventions include:

1. Evaluation of the airway and administration of supplemental oxygen
2. Administration of antiepileptic agents
3. IV/IO access
4. Cardiac monitoring

**Q: This child has been seizing for eight minutes. Does this constitute status epilepticus? How is status epilepticus defined?**

**A:** Status epilepticus has traditionally been defined as seizure activity lasting more than 30 minutes. However, recently a more practical and conservative definition has been accepted by the emergency medicine community:

1. Seizure lasting more than five minutes, OR
2. Consecutive seizures without a return to baseline in between



### **Pitfall:**

A common pitfall in the management of seizures is delayed administration of benzodiazepines. Complications of prolonged seizures include hypoxia, lactic acidosis, rhabdomyolysis, hyperkalemia, hyperthermia, and hypoglycemia, along with permanent neurologic damage. Status epilepticus also becomes progressively more resistant to anticonvulsant drugs over time, so prompt recognition and treatment are paramount.



### **Clinical Pearl:**

Essentially, if a child is still seizing on arrival to hospital, treat as status epilepticus.



### **Clinical Pearl:**

Early administration of benzodiazepines is a priority in status epilepticus.

**Q: This child has no IV access and is still seizing. His parents are freaking out, the resuscitation room is teeming with people, and your heart rate has gone way up. You know this child needs a benzodiazepine. What is the best way to deliver the first dose of benzodiazepine?**

**A:** The priority is to get a dose of a benzodiazepine into the patient as quickly as possible. Often, attempting to get an IV in an actively seizing child is difficult and can delay the delivery of drugs. There are many alternative routes available (intramuscular, intraosseous, intranasal, buccal, rectal) that require slightly different dosing of the various benzodiazepines. Rectal diazepam is helpful outside of the hospital setting, but in hospital IM, IN, or buccal midazolam or lorazepam are preferred due to their rapid onset of action.





## Benzodiazepine Dosing

Agent	Route	Dosing
Midazolam	Intramuscular	0.1-0.2 mg/kg (max 10 mg)
	Intranasal	0.2 mg/kg (max 5 mg/nare)
	Buccal	0.2 mg/kg (max 10 mg)
Lorazepam	Buccal	0.1 mg/kg (max 4 mg)
	Rectal	0.1 mg/kg (max 4 mg)
Diazepam	Rectal	0.5 mg/kg (max 20 mg)



The choice of benzodiazepine and the choice of route are not the major determinants of efficacy. Rather, the most important determinant of benzodiazepine efficacy in stopping seizures is **time to administration**. Again, early administration of a benzodiazepine is a priority.

**Q: Another priority in the management of status epilepticus is looking for an underlying cause. What are the causes of status epilepticus that require specific treatment beyond (or instead of) anticonvulsant medications?**

**A:** There are a number of specific situations that require specific treatment. Some can be established on history and others will require specific laboratory tests.



### Pitfall:

All seizing children should get a capillary glucose measurement early in their assessment to check for hypoglycemia as a cause for the seizure.

Some important specific causes of seizures and their treatments are as follows:

Cause	Treatment
Hyponatremia	3 cc/kg of hypertonic (3%) saline IV
Hypoglycemia	Dextrose IV
Anticholinergic toxicity	Sodium bicarbonate (if QRS > 100)
Isoniazid toxicity	Pyridoxine
Eclampsia	Magnesium Sulphate



### Clinical Pearl:

Once you have started giving your antiepileptic medications, start drawing up the next dose of medication so it is ready to administer if seizure activity continues to persist.

**Q: This child received two doses of diazepam but continues to seize. What is your next move?**

**A:** Generally, the second-line drug would be fosphenytoin or phenytoin. If fosphenytoin is available, this is preferred over phenytoin because of the reasons listed below.

	Fosphenytoin	Phenytoin
Route of administration	IV or IM	IV only
Rate of administration	150 mg/kg/min	50 mg/kg/min
Extravasation	Few side effects of extravasation	Can cause tissue necrosis (purple glove syndrome)
Fluid in administration	Can be given in saline or dextrose	Precipitates in dextrose solution



### Caution:

Avoid using phenytoin/fosphenytoin in toxin-related seizures (e.g., cocaine, local anesthetics, theophylline, TCAs). If you are suspicious of a toxin-related seizure, consider using phenobarbital or valproate as second-line drugs.

**Q: When would you consider using phenobarbital instead of fosphenytoin/phenytoin as a second-line drug?**

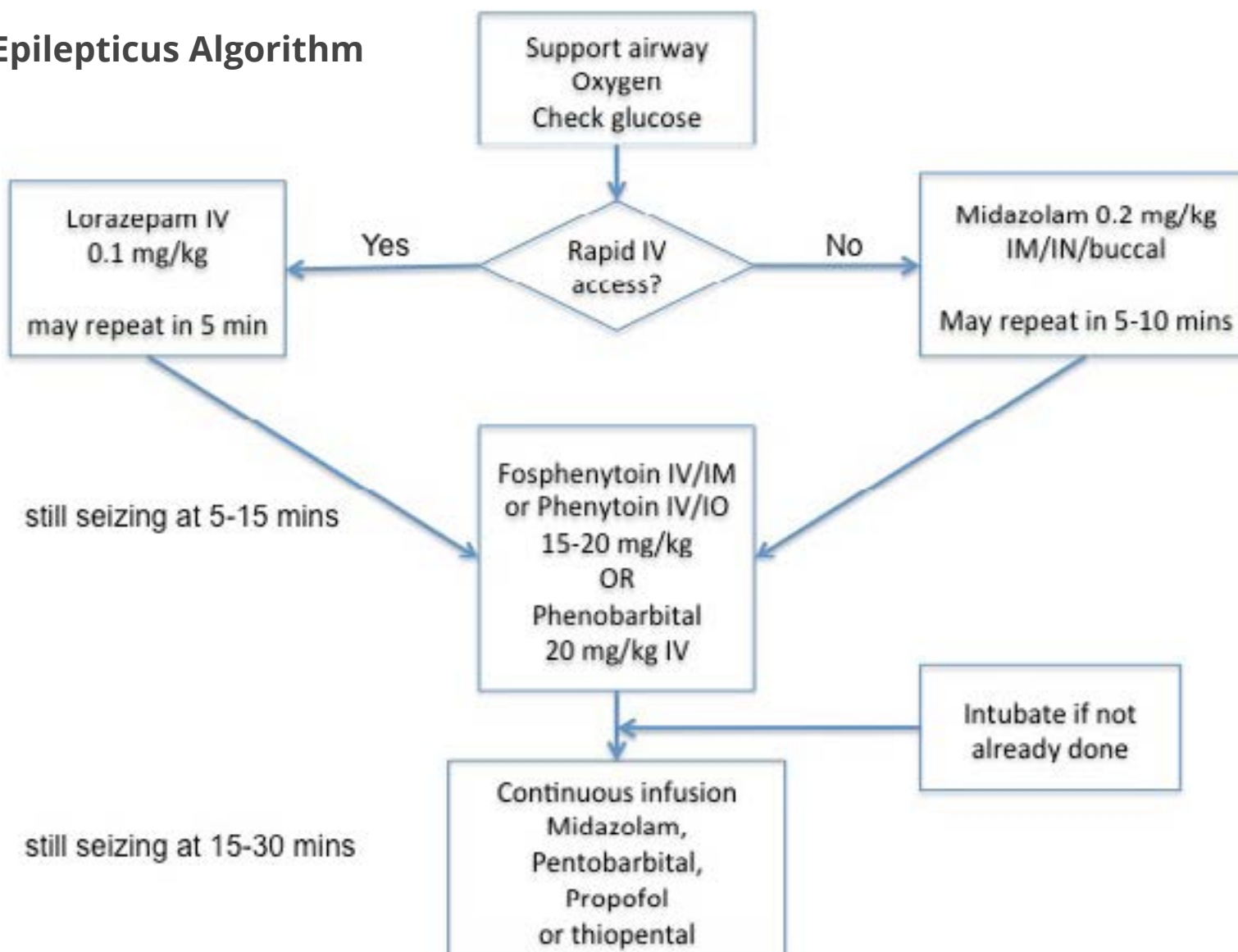
**A:** There are a few situations in which phenobarbital is preferable to phenytoin/fosphenytoin:

- Neonatal seizures
- Febrile seizures
- Patient with previous SE responsive to phenobarbital
- Toxin-related seizure

**Q: You have given three doses of benzodiazepines and a fosphenytoin load, and the patient is still seizing. This is now refractory status epilepticus. What are your next moves?**

**A:** If the patient is still seizing and has not already been intubated, the airway should be secured. In terms of medications, the options include an infusion of midazolam, pentobarbital, or propofol.

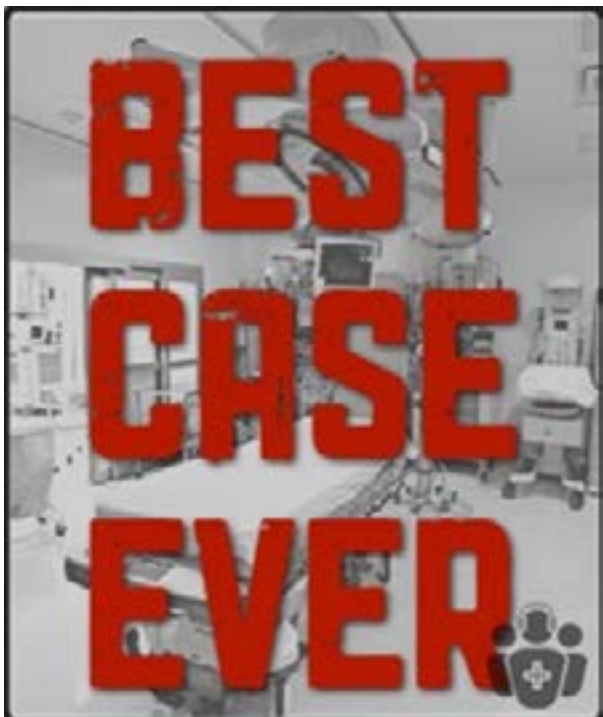
**Status Epilepticus Algorithm**



**Q: Your job is not over yet. What are your priorities of management once this child has finally stopped seizing?**

**A:** A full reassessment and management of the ABCs would be the first priority. If the patient is not already intubated, consider definitive airway management depending on clinical assessment. Monitor and manage bradycardia, hypotension, and hypoxia. If you are not in a hospital that has a PICU, arrange transport to a tertiary pediatric centre.

The next priority is to identify any underlying causes for the seizure if it hasn't been identified already. Double-check blood work, including sodium and calcium levels. Do an ECG to look for evidence of toxins or primary cardiac causes of the event (e.g., long QT). Think about other reversible causes, such as hypertensive encephalopathy, structural CNS disease, non-accidental injury, toxins, etc.



[When was the last time you saw ventricular fibrillation in a 4 month old? Listen to Dr. Rob Simard's Best Case Ever of a Pediatric Cardiac Arrest.](#)



**Comments?**

[Click here to leave a comment or to listen to this podcast.](#)

## KEY REFERENCES:

1. Alford EL, Wheless JW, Phelps SJ. Treatment of Generalized Convulsive Status Epilepticus in Pediatric Patients. *J Pediatric Pharmacol Ther*. 2015; 20(4):260-89.
2. Berg AT, Shinnar S, Darefsky AS, et al. Predictors of recurrent febrile seizures. A prospective cohort study. *Arch Pediatr Adolesc Med*. 1997; Apr;151(4):371-8.
3. Hirtz D, Berg A, Bettis D, et al. Practice parameter: Treatment of the child with a first unprovoked seizure Report of the Quality Standards Subcommittee of the American Academy of Neurology and the Practice Committee of the Child Neurology Society. *Neurology*. 2003; Jan;60(2):166-75.
4. Larry. Seizures and Status Epilepticus: Diagnosis and Management in the Emergency Department. 2007; 1-32.
5. Patel N, Ram D, Swiderska N, Mewasingh LD, Newton RW, Offringa M. Febrile seizures. *BMJ*. 2015; Aug; 351:h4240.
6. Silbergleit R, Durkalski V, Lowenstein D, et al. Intramuscular versus Intravenous Therapy for Prehospital Status Epilepticus. *N Engl J Med*. 2012; Feb;366(7):591-600.
7. Subcommittee on Febrile Seizures, American Academy of Pediatrics. Neurodiagnostic evaluation of the child with a simple febrile seizure. *Pediatrics*. 2011; Feb;127(2):389-94.
8. Warden CR, Brownstein DR, Del Beccaro MA. Predictors of Abnormal Findings of Computed Tomography of the Head in Pediatric Patients Presenting With Seizures. *Ann Emerg Med*. 1997; Apr;29(4):518-23.



# **RAPID REVIEW QUESTIONS**



**TEST YOUR NEW KNOWLEDGE IN A FUN  
RAPID REVIEW  
QUESTION-BASED FORMAT**

## CH. 1: PEDIATRIC FEVER WITHOUT A SOURCE

**Q: What rule can we use to correct for a child's heart rate and respiratory change in the setting of a fever? Apply this rule in a 12-month old girl who presents to your ED with a rectal temp of 39.0°C, heart rate 125 and respiratory rate of 25.**

**A:** Heart rate: increases by 10 beats per minute for every degree of fever above 38°C  
Resp rate: increases by 5 breaths per minute for every degree of fever above 38°C

Corrected HR =  $125 - (10 \times 1) = 115$

Corrected RR =  $25 - (5 \times 1) = 20$

**Q: Which two vaccines are the most important in reducing rates of bacteremia in children and at which ages are they given?**

**A:** Haemophilus influenzae type b and Pneumococcal conjugate vaccine. There is a very low rate of bacteremia in children with 2 or more doses of these two vaccines. In Canada, the Haemophilus vaccine is given at 2, 4, 6 and 18 months and the Pneumococcal vaccine is given at 2, 4, and 12 months.

**Q: An 18 month old child presents to your emergency department with a fever without an obvious source after your initial assessment. What are the 5 most common sources of fever you consider in this age group?**

**A:** LUCAS mnemonic: Lung, urine, CNS, abdomen, skin

**Q: What are risk factors for a UTI in the pediatric population?**

**A:** The risk factors for UTI are:

- Females < 24 months
- All males < 6 months
- Uncircumcised males < 24 months
- Fever for more than 2 days or fever > 39°C
- History of previous UTI

## CH. 1 CONT'D: FEVER WITHOUT A SOURCE

**Q: If you suspect a UTI in a child, how do you decide when to use a bag vs. catheter vs. midstream urine in a child based on the age of the child?**

**A:** < 2 months: obtain urine sample by catheterization and send every sample for a culture (as the urinalysis may be normal with a true infection)

2 months until toilet trained: bag urine is acceptable to screen by microscopy, if positive (ie. > 10-20 WBCs/hpf) a catheter sample is necessary

Toilet trained: obtain a mid-stream urine after adequate cleaning of the genitals.

**Q: Which children require additional urological imaging after a diagnosis of UTI?**

**A:** All children < 2 years with a first time UTI should have an outpatient ultrasound to look for vesico-ureteral reflux and structural anomalies. A voiding cysto-urethrogram (VCUG) is no longer recommended for children with a first time UTI.

**Q: What does a full septic workup include and what age group is this recommended in?**

**A:** A full septic workup is recommended in infants under 28 days of age. It includes:

- CBC
- Blood cultures
- Urinalysis collected by catheter
- Urine culture
- CSF sampling (send for: cell count, culture, gram stain, protein, glucose and viral studies)

## CHAPTER 2: PEDIATRIC SEPSIS & SEPTIC SHOCK

**Q: Is hypotension necessary for you to make the diagnosis of sepsis?**

**A:** Absolutely not. Hypotension is a late sign of pediatric septic shock and imminent arrest. Do NOT wait for hypotension to make the diagnosis of septic shock.

**Q: You should quickly move to place an intraosseous line in your critically ill child if obtaining IV access is delayed by how long?**

**A:** If your team cannot obtain IV access within the first 60 seconds, put in an IO line.

**Q: If you have made the call that your critically ill child is in septic shock, how much fluid should you be giving as an initial resuscitative measure?**

**A:** Fluids, typically crystalloids such as normal saline or Ringer's lactate, are given in boluses of 20cc/kg, repeated up to a total of 60cc/kg within the first hour, as long as there are no signs of hepatomegaly, crackles in the lungs, or sonographic evidence of pulmonary edema.

**Q: How would you infuse these fluids in the child who is in septic shock? IV normal saline "wide open"?**

**A:** IV fluids "wide open" may not deliver fluids fast enough. In order to deliver fluids faster, for younger children (<2yo), fill a 30-60cc syringe with saline and manually bolus them by IV push. For older children, use a level 1 infuser.

**Q: What quick test is essential to obtain right after the ABC's?**

**A:** ABC – DEFG = ABC, DON'T EVER FORGET GLUCOSE

## CH. 2 CONT'D: SEPSIS & SEPTIC SHOCK

**Q: What electrolyte abnormality should you be on the lookout for in the septic pediatric patient and how can you best treat it?**

**A:** Hypocalcemia is commonly seen in critically ill children with sepsis and it is recommended to treat hypocalcemia even in the absence of clinical manifestations such as seizures, cardiac arrhythmias. It is treated with calcium gluconate or calcium chloride if a central line has been placed.

**Q: At what point should you be considering vasopressors for your hypotensive septic pediatric patient?**

**A:** Pressors should be considered if your patient is in fluid-refractory shock defined as persistent clinical signs of septic shock after receiving 60 cc/kg of crystalloid.

**Q: How do you distinguish between warm and cold septic shock in your patient and which would be more common in children?**

**A:** Warm shock, as seen in most adults in septic shock presents with warm extremities and flash capillary refill, while cold shock, as seen in most children in septic shock presents with cool extremities and delayed capillary refill.

**Q: Which inotrope would be the best initial choice for your patient if you determine they are in cold shock? How about if you determine it's warm shock instead?**

**A:** Epinephrine would be best if you determine its cold shock while norepinephrine is preferable for warm shock.



## CH. 2 CONT'D: SEPSIS & SEPTIC SHOCK

**Q: As you are resuscitating your critically ill septic child, what markers of a successful resuscitation would you be looking for?**

**A:**

- Capillary refill < 2 sec
- Normal blood pressure
- Normal pulses with no differential between central and peripheral pulses
- Warm extremities
- Urine output > 1 ml/kg/hr
- Normal mental status
- Normal lactate

**Q: If neither fluids nor pressors are successful at improving the hemodynamic status of your patient, what other treatment could you try?**

**A:** Up to 25% of kids with sepsis have adrenal insufficiency either from prior steroid use, from the cause of sepsis itself or primary adrenal insufficiency. Adrenal insufficiency in this setting may lead to fluid and pressor refractory shock. Treatment is hydrocortisone 2mg/kg IV.

## CHAPTER 3: PAIN MANAGEMENT

**Q: You have ordered appropriate analgesia for your pediatric patient, what are some non-pharmacologic methods to reduce pain?**

**A:** Be creative, use distraction techniques with music, toys, cell phone videos, or books. You can also use physical elements such as heat, cold and proper positioning. You can try having a child breast feed if age-appropriate, or giving oral sucrose to children <6 months. Also remember to get your interprofessional team on board -- if you have Child Life Specialists, call them, too!

**Q: In a child who is still experiencing pain despite appropriate dosages of Ibuprofen 10 mg/kg and Acetaminophen 15 mg/kg, what could be your next option orally? IV? to maintain analgesia for hours?**

**A:** A good oral option would be morphine oral suspension at a dose of 0.2 – 0.5 mg/kg PO (max 15 mg) q4-6h. IV morphine is dosed at 0.1 mg/kg IV push and titrated to effect.

**Q: Why should Codeine be avoided in kids?**

**A:** Although long thought of as the preference for managing pain in children, codeine is a pro-drug that gets converted into morphine. Some people are ultra-rapid metabolizers of codeine, and receive a huge surge of morphine systemically along with its adverse effects.

**Q: Your pediatric patient is in a lot of pain and you are having trouble starting an IV. What you would do next?**

**A:** This is a great time to use intranasal fentanyl. The dose of IN fentanyl is 1-1.5mcg/kg to a max of 100mcg. It acts fast within 3 minutes. Use only a volume of 1.5ml per nare, use both nares if needed. A general rule of thumb is to use twice the IV dose. Always remember you can use naloxone IN in the event of respiratory depression.

## CHAPTER 4: PEDIATRIC HEAD INJURY

**Q: In assessing a child with head injury, what are the 6 criteria from the PECARN study that should be a part of your assessment?**

**A:** 1. Altered mental status  
2. Non-frontal scalp hematoma  
3. Loss of consciousness for at least 5 seconds  
4. Severe mechanism of injury  
5. Palpable skull fracture  
6. Not acting normally according to the parent

**Q: If the child's history included either isolated vomiting would that necessitate a CT head to rule out traumatic brain injury?**

**A:** Isolated vomiting should not automatically lead to CT as it is not predictive of traumatic brain injury. Persistent vomiting associated with other signs of increased ICP, in contrast, has been shown to have a positive predictive value for traumatic brain injury.

**Q: If you are suspecting a basilar skull fracture, what signs might you be expecting to find in your pediatric patient?**

**A:** Such signs might include hemotympanum, periorbital ecchymosis (raccoon eyes), mastoid bone ecchymosis (battle's sign) or a cerebrospinal fluid leak from the nose or ears (otorrhoea/rhinorrhoea).

**Q: If you are sending your patient with mild or moderate head injury home is it necessary for their parents to wake them up every 2 hours to ensure they are acting appropriately?**

**A:** No; however, if overnight includes the first 6 hours after injury it would be reasonable to wake them up once to ensure they are acting appropriately.

## CHAPTER 5: PROCEDURAL SEDATION

**Q: Why are pediatric patients at higher risk for airway obstruction than adults?**

**A:** Pediatric patients are at a higher risk of airway obstruction due to anatomical factors such as large occiput and tongue, and narrower, more pliant airways.

**Q: What is the anxiolytic of choice for facilitating a CT scan in a child?**

**A:** For non-painful procedures, distraction should be attempted before medications are administered. Some departments are equipped with visual equipment that can distract children in the radiology department.

If distraction techniques are ineffective, IN midazolam is recommended as first line therapy for sedation. If IN midazolam is not available, oral midazolam is recommended.

- Intranasal dose: 0.3mg/kg (max 10mg); time of onset: 7-10min
- Oral dosing: 0.7mg/kg (max 20mg); time of onset: 15-20min

Before administering midazolam, consider the recovery time and that it may cloud your physical and neurological assessments of the patient. Perform a good neurological exam before the sedation!

**Q: After an uncomplicated procedural sedation for a distal radius reduction, how long should you monitor a patient for?**

**A:** Length of observation time depends on agents used and on patient metabolism.

Rough guide to discharge when:

- Patient is back to developmentally appropriate motor, cognitive and social function (ex: walk by self, speaking to parents)
- Patient can tolerate a PO fluid challenge
- Reliable monitoring plan at home prior to discharge
- Family comfortable with plan

## CHAPTER 6: PEDIATRIC ORTHOPEDIC INJURIES

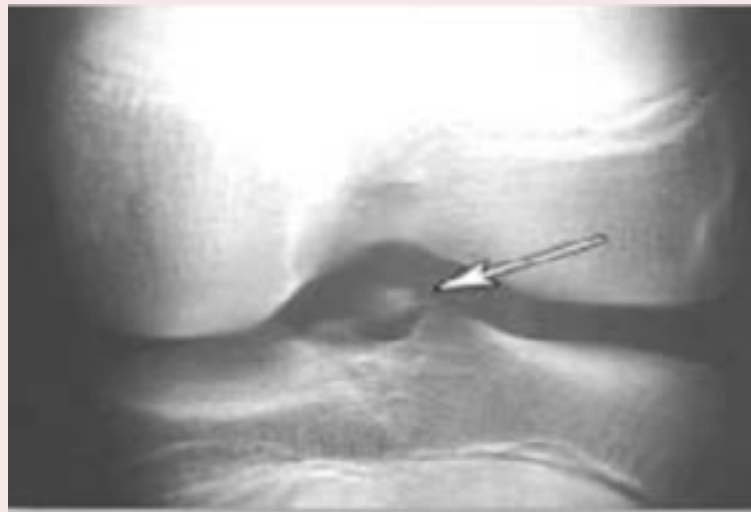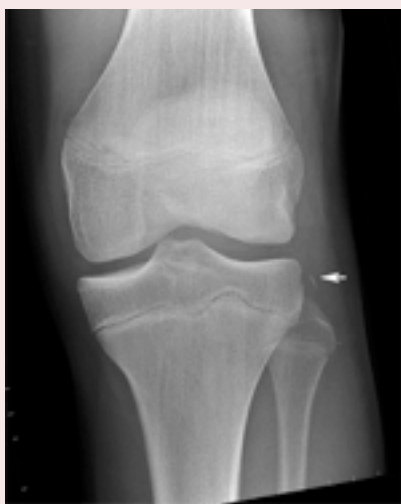**Q: What are the criteria for the Ottawa Knee Rules?**

**A:**

1. Age >55 (omitted in pediatrics)
2. Pain at the fibular head
3. Isolated patellar tenderness
4. Inability to flex the knee to 90 degrees
5. Inability to walk four weight-bearing steps both immediately & in the ED

**Q: If you suspect an ACL tear, which two fractures should you look out for on the X-ray?**

**A:** A Segond Avulsion Fracture or Tibial Plateau Fracture



**Q: What commonly missed fracture should you consider ruling out in a limping child?**

**A:** A Toddler's Fracture

**Q: What physical maneuvers should raise your suspicion of this fracture?**

**A:** Pain with calf rotation or ankle dorsiflexion.



## CH. 6 CONT'D: ORTHOPEDIC INJURIES

**Q: What pediatric age are the Ottawa ankle rules validated for?**

**A:** The Ottawa Ankle rule has been shown to have a high sensitivity for ankle and mid-foot fractures in children older than five years old.

**Q: Which method of immobilization is most appropriate for a 7 year old who sustains a buckle fracture of the distal radius?**

**A:** Buckle fractures of the distal radius heal well in a removable splint, and studies show that patients prefer this over a cast. One randomized control trial showed better physical function, less difficulty with activities, the ability to return to sports sooner, and pain scores that were either not significantly different when compared to a short arm cast, or less than with casting.

**Q: When examining an x-ray showing a pediatric distal radius fracture, what degrees of angulation are acceptable by age?**

**A:** Acceptable degrees of angulation depend on the age of the child:

- <5 years old: up to 30 degrees
- 5-10 years old: up to 20 degrees
- 10-12 years old: up to 15 degrees

**Q: What are the elements of the Kocher criteria for septic arthritis?**

**A:** Kocher Criteria is a tool to help risk stratify patients suspected of having septic arthritis. If all four criteria are met, the probability of septic arthritis is 99.6%.

The Kocher Criteria include:

- Non-weight-bearing on the affected side
- ESR >40 mm/hr
- Fever
- WBC >12,000

## CHAPTER 8: ABDOMINAL PAIN & APPENDICITIS

**Q: What are the top 5 most common diagnoses that present with the chief complaint of abdominal pain in children?**

**A:** Gastroenteritis; respiratory tract infection (including otitis media, pharyngitis, and pneumonia); UTI; constipation; appendicitis

**Q: If you administer pain medications to a child with suspected appendicitis, will it mask your physical exam?**

**A:** No. The myth has long been dispelled that providing analgesia can mask physical exam findings leading to misdiagnosis in appendicitis.

**Q: What is the value of a WBC in ruling in/out appendicitis?**

**A:** There is no laboratory marker that can be used in isolation to definitively rule in or rule out appendicitis.

A WBC is of limited utility in diagnosing the cause of pediatric abdominal pain. The likelihood ratios associated with the presence or absence of leukocytosis are not sufficient to either rule in or rule out appendicitis. Children with gastroenteritis may have a high WBC with a left shift, while as many as 40% of those with appendicitis may have no leukocytosis. Nonetheless, a normal WBC does make the diagnosis less likely.

**Q: If you are worried about a patient that may have appendicitis but the ultrasound report was inconclusive, what should your next step be?**

**A:** If you have a high clinical suspicion, consultation with a pediatric surgeon or proceeding with a low dose CT would be the next step. If you have a low to moderate clinical suspicion, consider having the patient return in 12-24hrs for a repeat ultrasound, as the sensitivity of ultrasound increases with time from symptom onset.

## CHAPTER 10: GASTROENTERITIS, CONSTIPATION & OBSTRUCTION

**Q: If you have a pediatric patient in whom you suspect a diagnosis of gastroenteritis, what are some key diagnoses that should cross your mind to at least consider prior to making the diagnosis?**

**A:**

- Intracranial Mass
- Meningitis
- Intussusception
- Diabetic Ketoacidosis
- Cholinergic Syndrome
- Pneumonia
- Myocarditis
- Appendicitis
- Urinary Tract Infection

**Q: If you are trying to determine if this child is dehydrated, what are the 4 most useful clinical exam findings that you should look for?**

**A:** From the Gorelick Score, 2 or more of the following suggests > 5% dehydration:

- Capillary Refill > 2 seconds
- Absent tears
- Dry mucous membranes
- Ill general appearance

**Q: If on history you hear of ingestion of an undercooked hamburger and have at least a suspicion of Hemolytic Uremic Syndrome what is the classic triad of lab findings you should expect to see and what would you look for on exam?**

**A:** The classic triad of HUS is microangiopathic hemolytic anemia, thrombocytopenia, and renal insufficiency. Clinical features that should raise suspicion for HUS include bloody stool, abdominal pain, lethargy, low-grade fever, paleness and tachycardia, petechia, periorbital edema (especially upon waking) and tea colored urine.

## CHAPTER 11: DIABETIC KETOACIDOSIS

**Q: What are the initial management steps in pediatric cerebral edema associated with DKA?**

**A:**

- Elevate the head of the bed to 30 degrees
- Mannitol 0.5-1g/kg over 20 minutes or
- 3% Hypertonic Saline 5-10cc/kg IV over 30 minutes

**Q: What is the only situation you would consider giving a child with DKA fluid boluses?**

**A:** Fluid boluses are only indicated in pediatric DKA patients who are in decompensated shock. If a child has a blood pressure below  $70 + (2 \times \text{Age})$ , judicious fluids should be given until the pressure corrects above this range.

**Q: What is the timing, dose and rate of initial IV insulin treatment for the child in moderate or severe DKA?**

**A:** Initial insulin infusion should be between 0.05-0.1 unit/kg/hour. There is no role for insulin boluses in pediatric patients with DKA due to an association with cerebral edema.

Insulin should be administered after 1-2 hours of intravenous fluids.

**Q: How is the severity of DKA categorized?**

**A:** The severity of DKA is classified based on the degree of acidosis and the  $\text{HCO}_3^-$  level.

Mild DKA	Moderate DKA	Severe DKA
pH < 7.3	pH < 7.2	pH < 7.1
$\text{HCO}_3^- < 15$	$\text{HCO}_3^- < 10$	$\text{HCO}_3^- < 5$

## CH. 11 CONT'D: DIABETIC KETOACIDOSIS

**Q: Which blood tests are most useful to monitor treatment in a child in DKA?**

**A:** Serum ketones or a decreasing anion gap are both useful in monitoring ketosis and treatment.

**Q: How does the management of DKA differ between adult and pediatric patients?**

**A:**

- 1. IV fluids** – While adult DKA guidelines recommend multiple fluid boluses in the first 2 hours of care, fluid boluses are only indicated in pediatric patients who are in decompensated shock. Judicious use of IV fluids is encouraged with twice maintenance being the upper limit of administration.
- 2. Potassium management** – Adult DKA patients have strict potassium cut-offs that guide insulin administration, but potassium management in pediatric DKA is less stringent. This is likely a result of pediatric patients being less prone to arrhythmias with hypokalemia.
- 3. Sodium bicarbonate** – While sodium bicarbonate is recommended in adult DKA with a pH < 7.1, its use in pediatric DKA is limited to patients with cardiovascular collapse.



## CHAPTER 12: PEDIATRIC BRONCHIOLITIS

**Q: Is it normal for a 6 month old patient to breathe 50 breaths per minute?**

**A:** No! The upper limits of normal for respiratory rate in children are:

- Term Neonate – 50 breaths/min
- 6 month old – 40 breaths/min
- 12 month old – 30 breaths/min

**Q: If clinically you suspect bronchiolitis in your patient, do they require a chest x-ray to confirm the diagnosis?**

**A:** Chest x-rays are not recommended as a routine test in children suspected of bronchiolitis according to The American Association of Pediatricians guidelines.

**Q: Is salbutamol (Albutarol or Ventolin) indicated in children with suspected bronchiolitis?**

**A:** A trial of salbutamol is reasonable if there is a strong family history of asthma, atopy or in the patient who has had multiple wheezing episodes.

**Q: How about nebulized epinephrine for the child suspected of bronchiolitis?**

**A:** There isn't great evidence for the use of nebulized epinephrine in bronchiolitis; however, a Cochrane Review did find some benefit in those patients who were admitted to hospital so nebulized epinephrine may be considered in patients in whom you suspect admission will be the likely disposition.

**Q: Are steroids of any benefit in treating bronchiolitis?**

**A:** Corticosteroids alone are not recommended in bronchiolitis, however there is some evidence to suggest that the combination of steroids and nebulized epinephrine may be of some benefit.

## CH. 12 CONT'D: PEDIATRIC BRONCHIOLITIS

### **Q: How about nebulized hypertonic saline for bronchiolitis?**

**A:** The evidence for hypertonic saline is equivocal but it is reasonable to try in kids likely requiring admission.

### **Q: What are the risk factors for apnea in bronchiolitis?**

**A:** The overall incidence of apnea with bronchiolitis is 2.7%.

Risk factors for apnea with bronchiolitis include:

- Age < 2 months
- Small for gestational age (weight < 2.3kg)
- Previous episode of apnea
- Oxygen saturation < 90%

### **Q: What are the published criteria for admission in bronchiolitis?**

**A:** From the Canadian Pediatric Society 2014 guidelines:

- Signs of severe respiratory distress (ie. indrawing, grunting, or RR>70)
- Supplemental O<sub>2</sub> required to keep saturations >90%
- Dehydration or history of poor fluid intake
- Cyanosis or history of apnea
- Family unable to cope
- Infant at high risk for severe disease (born at < 35 weeks gestation, <3 months old, hemodynamically significant cardiopulmonary disease, immunodeficiency)

## CHAPTER 13 & 15: PEDIATRIC ASTHMA & CROUP

**Q: In evaluating an asthmatic child, what aspects of their past history will you solicit in order to gauge the severity of their asthma?**

**A:**

- Previous life-threatening exacerbations
- Admissions to ICU
- Intubation
- Deterioration while already on systemic steroids
- Using more than 2 canisters of short acting B-agonist per month
- Cardiopulmonary and psychiatric comorbidities

**Q: What are the features on history or physical exam that you might elicit that should make you consider ordering an x-ray for your pediatric patient with a clinical asthma exacerbation?**

**A:**

- Focal chest findings (unilateral wheezing, or crackles)
- Fever
- Extreme distress
- Subcutaneous emphysema
- History of choking

**Q: How long do corticosteroids given to a child with an asthma exacerbation take to show a clinical benefit?**

**A:** Corticosteroids typically take at least 2 hours to work and should therefore be given early in the ED presentation.

**Q: If you elect to treat your patient with the severe exacerbation with magnesium, why would it be important to infuse it slowly?**

**A:** Magnesium should be administered over at least 20 minutes to avoid the most common side effect of hypotension.

## CHAPTER 16: PEDIATRIC SYNCOPE

**Q: What are features you might elicit on history and physical exam that should prompt a further evaluation to rule out a cardiac or neurological cause of the syncope?**

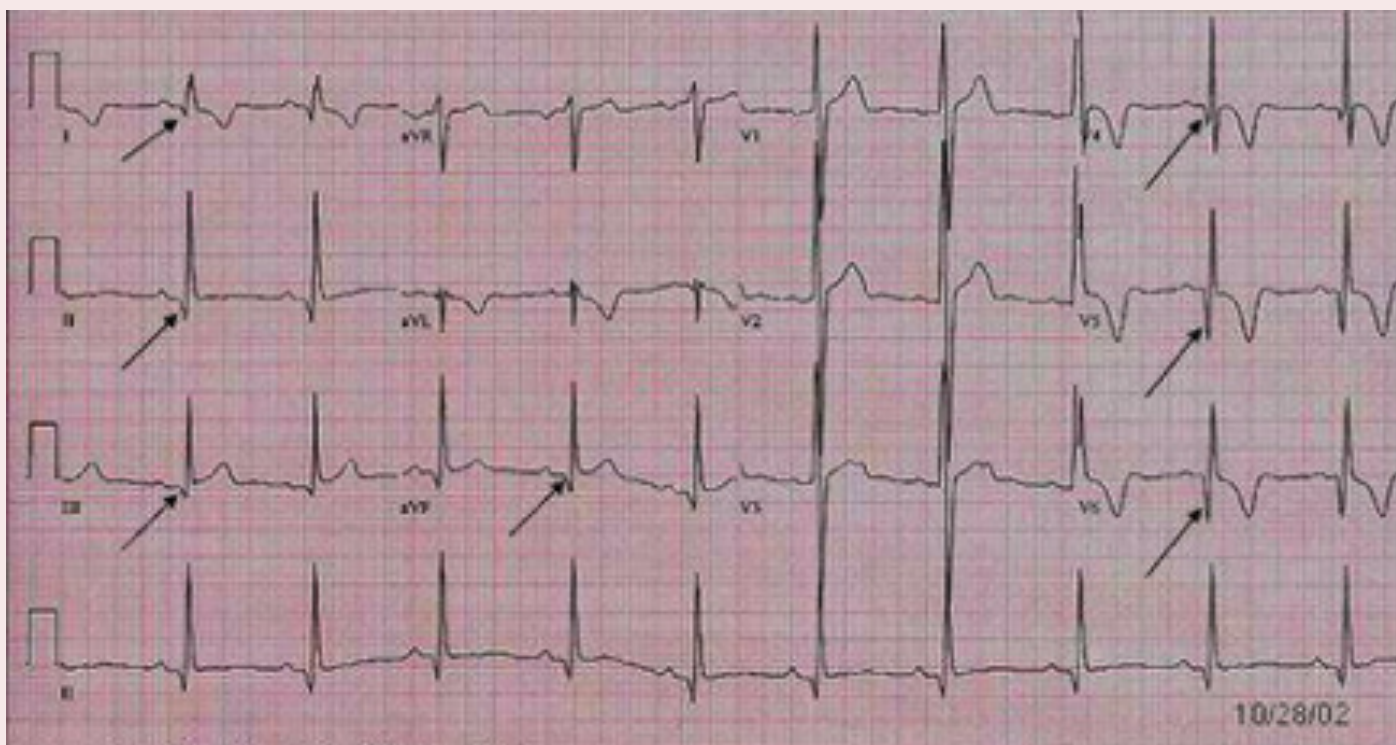
**A:**

- Syncope during physical exertion
- Family history of sudden cardiac death or deafness
- Chest pain, palpitations or dyspnea
- History of structural heart disease
- Abnormal cardiac exam
- Focal neurological findings

**Q: In a pediatric patient in whom you auscultate an outflow murmur that increases with valsalva or standing, what pathology must be considered?**

**A:** An outflow murmur that increases with valsalva or standing in a child presenting with syncope is hypertrophic cardiomyopathy until proven otherwise.

**Q: What are the key features of this ECG and what is the disease are they typical of?**

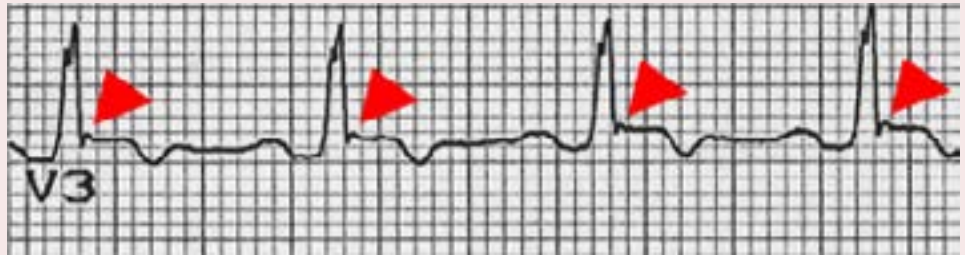


## CH. 16 CONT'D: PEDIATRIC SYNCOPE

**A:** This ECG is suggestive of hypertrophic cardiomyopathy (HCM) courtesy of the Life in the Fast Lane blog. ECG findings of HCM include:

- Increased QRS complex voltage ('Dagger Q waves')
- ST-segment and T-wave signs of LV hypertrophy
- Q-waves in leads II, III, aVF, V5, V6

**Q: What pathology is this ECG suggestive of?**



**A:**

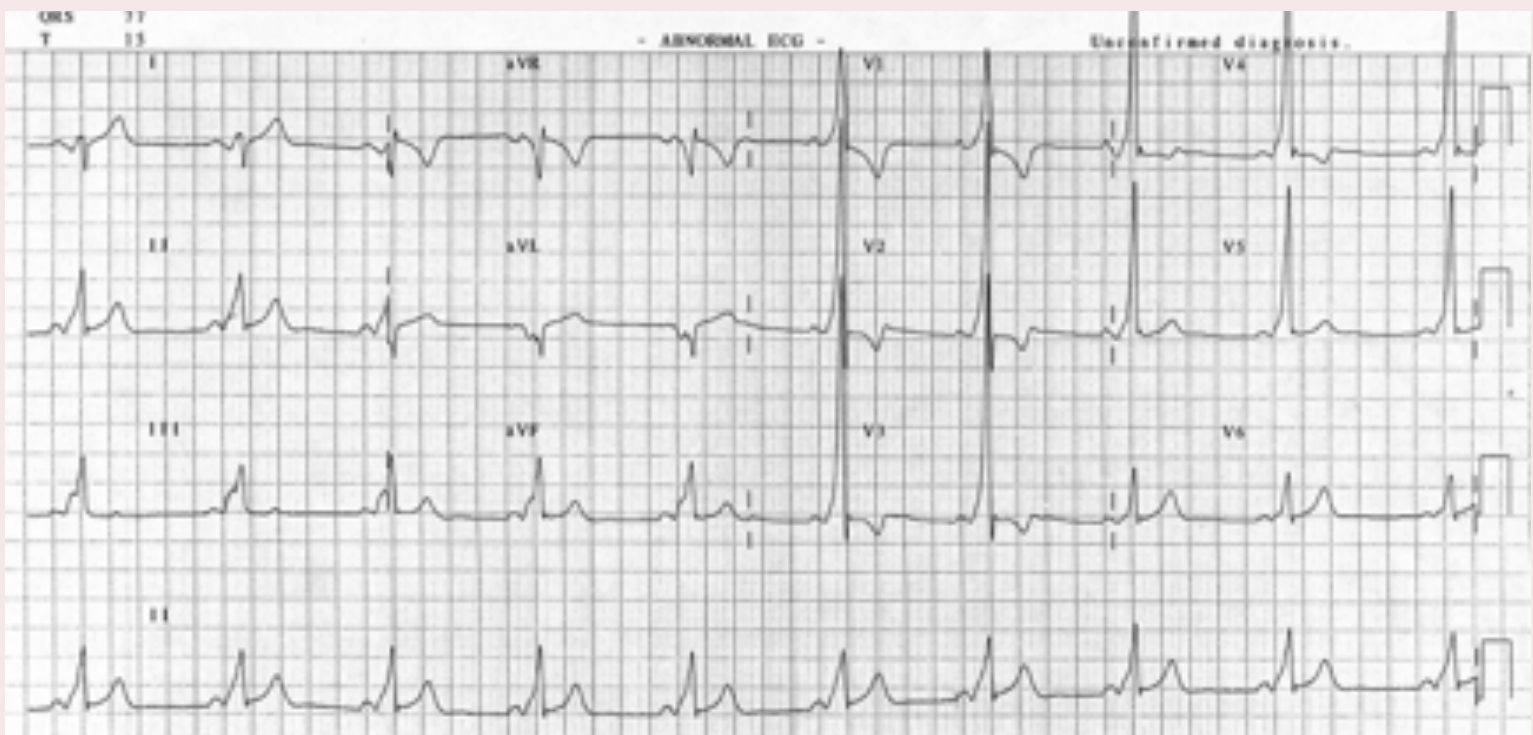
This ECG is suggestive of arrhythmogenic right ventricular cardiomyopathy (ARVC).

Key ECG findings in ARVC include:

- Inverted T waves in right precordial leads (V1, V2, V3)
- QRS in Lead 1 > 110 msec
- Epsilon waves (low amplitude notches after QRS and before T wave) in the right precordial leads (V1- V3)

**Q: This ECG is suggestive of what cardiac disease that can cause syncope and sudden death?**

**A:** Courtesy of Life in the Fast Lane blog





## CH. 16 CONT'D: PEDIATRIC SYNCOPE

**A:** This ECG is suggestive of Wolf Parkinson White (WPW) syndrome, which typically includes the following elements:

- Short PR interval of less than 3 small squares (120 ms),
- Slurred upstroke to the QRS indicating pre-excitation (delta wave)
- Broad QRS
- Secondary ST and T wave changes

**Q: What is the typical story of a patient who suffers a syncopal episode as a result of Long QT Syndrome?**

**A:** The history of pediatric patients who present to the ED with syncope related to Long QT Syndrome typically involves exertion such as swimming, or emotional distress. These patients can also suffer an abrupt onset of syncope due to fright or awakening by a loud noise, such as an alarm clock.

**Q: What QTc length in the ECG of a pediatric patient would warrant referral to a cardiac electrophysiologist?**

**A:** In children a QTc interval  $>450$  is considered high risk in contrast to adults where a QTc  $>500$  is considered high risk.

## CHAPTER 17: PEDIATRIC SEIZURES

**Q: If parents come to your ED with a child with a history of shaking, what features might suggest you are dealing with a true seizure?**

**A:**

- Post-ictal phase (rapid/immediate return to normal activity is unlikely to follow a true seizure)
- Lateral tongue biting
- Flickering eye lids
- Blank stare or deviated eyes
- Lip smacking
- Increased heart rate and blood pressure during the event

**Q: How do you differentiate a seizure from a breath holding spell?**

**A:** The temporary decrease in cerebral oxygenation in a breath holding spell can cause very brief seizure activity making the diagnoses difficult to distinguish. However, a breath holding spell typically has a Clear trigger (emotional distress or pain) and rapid and complete recovery (no post ictal phase).

**Q: What features of a witnessed seizure might you elicit that would tend to favour the diagnosis of pseudoseizure?**

**A:**

- Adolescent population
- Movements such as side to side head motion, back arching, asynchronous movement (ie bicycling)
- Preserved level of consciousness

## CH. 17 CONT'D: PEDIATRIC SEIZURES

**Q: In evaluating a febrile seizure in a pediatric patient, what features would suggest a complex rather than simple febrile seizure?**

**A:**

	Simple	Complex
Age	6 months – 5 years	Any
Frequency	Single seizure in 24 hours	Multiple seizures in 24 hours
Nature	Generalized	Generalized or focal
Duration	< 15 mins	Can be prolonged
Recovery	Return to baseline after short post-ictal period	May not return fully to normal if multiple seizures

**Q: If the parents of your patient with the febrile seizure tell you that this is his third day of fever would this be more or less worrisome for an underlying serious bacterial infection?**

**A:** Simple febrile seizures tend to occur within the first 24 hours of a febrile illness. If the seizure occurs > 24 hrs after the onset of fever the index of suspicion for more severe bacterial illness should be heightened.

**Q: What workup does a child suffering a simple febrile seizure require?**

**A:** If your history suggests that the seizure is a simple febrile seizure, then no specific workup is required for the seizure, other than investigating the fever as you would in any other febrile child.

**Q: Does every complex febrile seizure patient require a CT Head? If not, then which patients with febrile seizures do require a CT Head?**

**A:** Indications for neuroimaging in the ED in the child with a febrile seizure:

- Suspicion of non-accidental injury
- Signs of increased ICP
- Patient who do not return to neurologic baseline
- Underlying known CNS disorder (eg VP shunt)

## CH. 17 CONT'D: PEDIATRIC SEIZURES

**Q: How would you counsel the parents of this febrile seizure patient regarding the risk of recurrence and the risk of epilepsy for their child?**

**A:** Risk of recurrence is approximately 33% overall with a higher risk in children

- <18 months of age
- Temperature < 40.0°C at first convulsion
- <1hr between onset of fever and first seizure
- Family history of febrile seizures

If they have all 4 of the factors, their risk of recurrence is 70%. If they don't meet any criteria, their risk falls to 20%.

The risk of epilepsy is approximately 2% after a simple febrile seizure and 5 % after a complex febrile seizure (compared to 1% in the general population).

**Q: If a child presents to your ED with a non-febrile seizure, should you automatically order a head CT head? If not, what are some features on history that might push you to do so?**

**A:** Neuroimaging is generally not necessary in the ED in a child after a non-febrile seizure who returns to neurologic baseline. Some high-risk criteria for finding a culprit lesion on a CT scan of the head are:

- Focal seizure or persistent seizure activity
- Focal neurologic deficit
- VP shunt
- Neurocutaneous disorder suggested on skin exam
- Signs of elevated increased ICP
- History of trauma
- Travel to an area endemic for neurocysticercosis
- Immunocompromised state
- Hypercoagulable state (eg sickle cell disease) or bleeding disorder

## CH. 17 CONT'D: PEDIATRIC SEIZURES

**Q: If an infant presents with a non-febrile seizure and is found to be hyponatremic, what is the likely cause of their seizure?**

**A:** Overdilution of infant formula, either from attempts at cost savings or error, would be the most likely cause.

**Q: If a child arrives to your department in status epilepticus with no IV access, what are 4 alternate routes you could consider for medication deliver?**

**A:** Intramuscular (midazolam), intranasal (midazolam), buccal (midazolam, lorazepam) or rectal (lorazepam, diazepam).

**Q: If your status epilepticus patient is still seizing after 2 or 3 rounds of an appropriately dosed benzodiazepine, what medication would you next move to?**

**A:** Fosphenytoin is the recommended second line medication for status epilepticus. If fosphenytoin is not available in your department then phenytoin can be substituted.

**Q: If you have given 3 rounds of benzos to your seizing patient and a load of phenytoin or fosphenytoin but they are still seizing, what is your next step?**

**A:** The next step would be a continuous infusion of either midazolam, pentobarbital, propofol or thiopental.



