

## CASE REPORT

# Torus Mandibularis: Excision and Closure with Cyanoacrylate Tissue Glue

<sup>1</sup>Poonam P Bhandari, <sup>2</sup>Pankaj Rathod, <sup>3</sup>Rohit Punga, <sup>4</sup>Rohit Chawla

## ABSTRACT

Exostosis is a slowly growing bony outgrowth, which is a common clinical finding in the oral cavity. They increase in size slowly with age and usually do not cause any inconvenience to the patients. Occasionally they produce pain and discomfort when prosthesis needs to be placed over or adjacent to that area, and food accumulation, pressure with ulceration, limited tongue space can occur, which makes their removal or reduction mandatory. Mandibular tori are often nodular or lobulated in shape and commonly occur bilaterally on the lingual cortical plate (canine, premolar region), whereas the maxillary tori are often flat or spindle-shaped present in the mid-palatine region.

**Keywords:** Cyanoacrylate, Phonation, Torus mandibularis, Torus palatinus.

**How to cite this article:** Bhandari PP, Rathod P, Punga R, Chawla R. Torus Mandibularis: Excision and Closure with Cyanoacrylate Tissue Glue. *Int J Oral Care Res* 2016;4(2):134-138.

**Source of support:** Nil

**Conflict of interest:** None

## INTRODUCTION

Tori ("to stand out" or "lump" in Latin) are exostosis that are formed by a dense cortical bone and some amount of bone marrow covered with poorly vascularized mucosa.<sup>1</sup> They are often bilateral and commonly found on the lingual aspects of the canine or premolar regions in the mandible (torus mandibularis) and the mid-palatine region of the maxilla (torus palatinus). Occasionally, they can also occur on the buccal surfaces or the alveolar processes of the jaw bones in a solitary location or extensively spread bilaterally.<sup>2</sup> They are asymptomatic and have slowly growing benign bony overgrowths that rarely predispose any problem to the patients, except in edentulous jaws where they hinder with the

fabrication of prosthesis. Larger tori can also cause perturbed phonation,<sup>3</sup> produce pain or create ulceration of the overlying mucosa due to constant trauma, and sometimes even trap the lingual frenum causing further obstruction in tongue movement. The potential malignant transformation has not yet been reported.<sup>4</sup>

## CASE REPORT

A 63-year-old male patient reported with a chief complaint of discomfort in the lower right and left posterior tooth region with slight difficulty in speech, recurrent ulcerations, and food lodgment since 9 months, and was also willing for replacement of all the missing teeth.

The patient was moderately built and appeared to be well nourished. His face was bilaterally symmetrical and extraoral examination did not reveal any abnormal features. Dental history revealed history of full mouth extraction 6 months back.

In this regard, the intraoral examination revealed completely edentulous maxillary and mandibular arches with four painless, nodular, bony hard masses of approximately 1.5×1 cm sizes on the left side and two masses of approximately 2×1 cm and 1×0.5 cm each on the right side, in the premolar regions with thin overlying normal mucosa. Examination also revealed bony spicules on the labial surfaces of the lower canine, premolar regions (Fig. 1).

After radiographic evaluation and routine hematological investigations, patients consent was taken for surgical

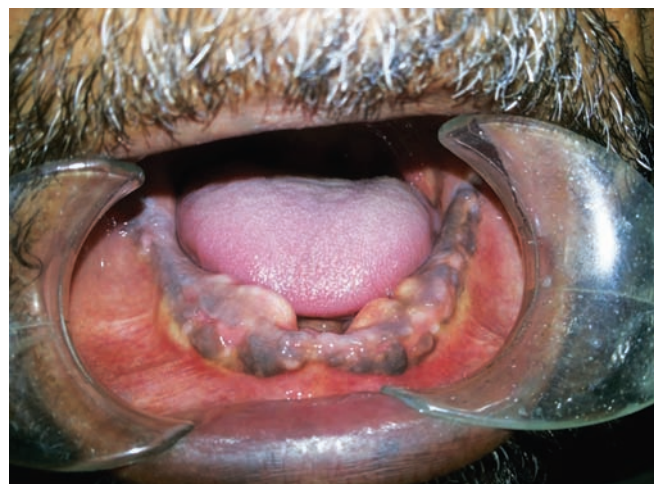

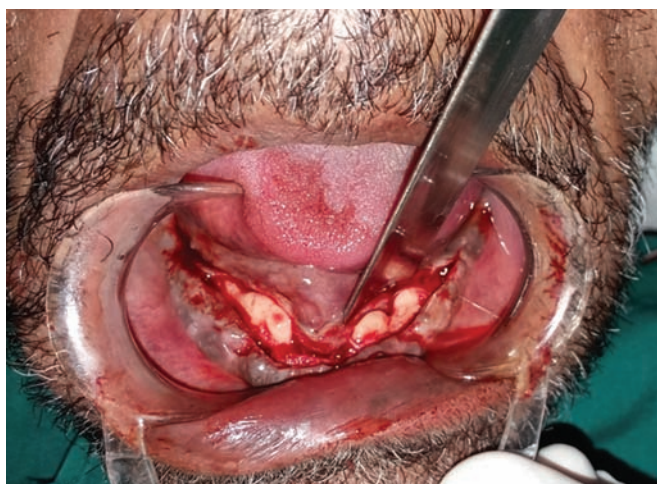Fig. 1: Mandibular tori in the bilateral premolar region

<sup>1</sup>Professor and Head, <sup>2,4</sup>Senior Lecturer, <sup>3</sup>Reader

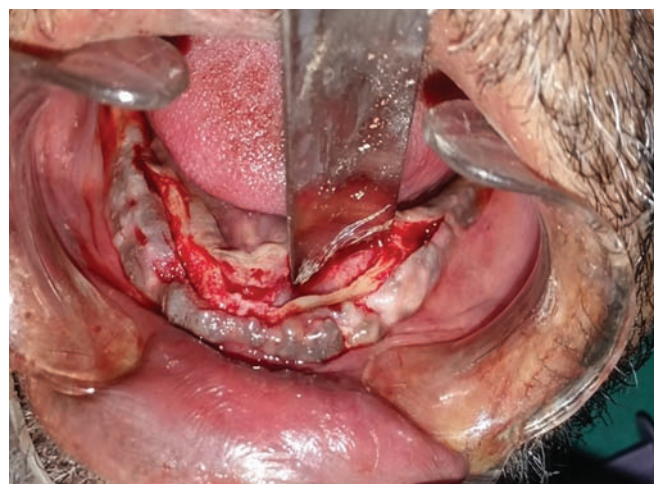<sup>1-3</sup>Department of Oral and Maxillofacial Surgery, PDM Dental College & Research Institute, Bahadurgarh, Haryana, India

<sup>4</sup>Department of Oral and Maxillofacial Surgery, Genesis Institute of Dental Sciences & Research, Ferozpur, Punjab, India

**Corresponding Author:** Pankaj Rathod, Senior Lecturer Department of Oral and Maxillofacial Surgery, PDM Dental College & Research Institute, Bahadurgarh, Haryana, India Phone: +919992029736, e-mail: drpankajr1982@gmail.com pankajr1982@rediffmail.com



**Fig. 2:** Exposure of the toris bilaterally



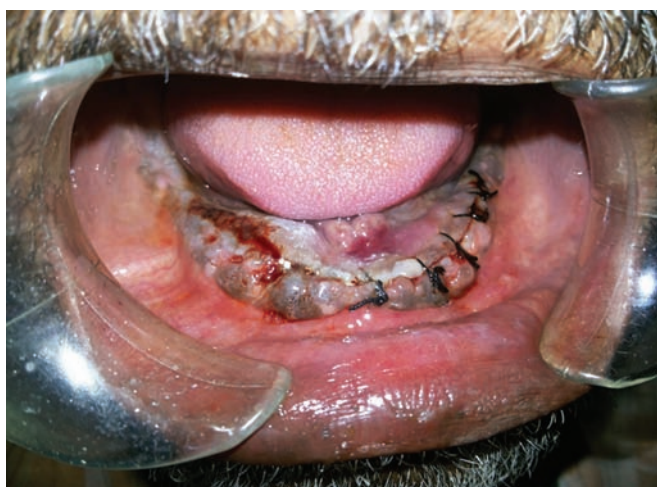**Fig. 3:** Surgical view after excision of the toris bilaterally

excision of the mandibular torus. Bilateral inferior alveolar nerve block with local infiltration (2% lignocaine hydrochloride with adrenaline 1:80,000) was administered. A crestal incision was placed at the center of the alveolar ridge extending from the first molar region of right side to the left side. Full-thickness mucoperiosteal flaps were raised, taking care that the thin flaps do not lacerate or tear, and the tori were exposed lingually (Fig. 2).

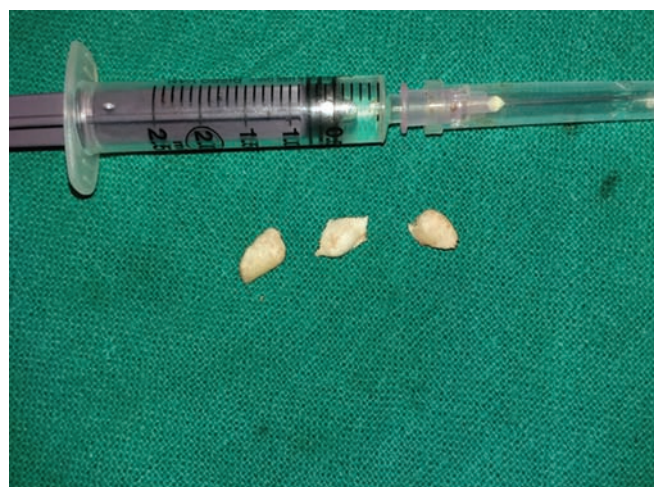A horizontal guiding groove was made at the base of the tori using a straight fissured bur under copious saline irrigation. Periosteal elevator was placed at the base of the tori to protect the underlying lingual tissues. Following the guided groove, the tori were resected in bloc using chisel and mallet. The anterior torus on the right side was removed in a similar manner and the posterior one which was smaller in dimension was surgically reduced. Alveoloplasty of the sharp bony spicules on the labial surfaces in the canine, premolar region was done. Hemostasis was achieved and thorough irrigation was done with povidone-iodine (Fig. 3).

Wound closure was done using interrupted black braided 3-0 silk sutures on the left side of the incision up to the midline. Closure on the right side was accomplished using isoamyl 2-cyanoacrylate tissue glue (Instaseal). After thorough isolation and proper approximation of the incised margins on the right side, the syringe-loaded tissue glue was slowly applied through the needle tip in a continuous flow starting from the midline toward the end of incision. The glue was allowed to set for 2 to 3 minutes. The post-operative sites were again irrigated with povidone-iodine and pressure pack was placed on both the sides (Fig. 4).

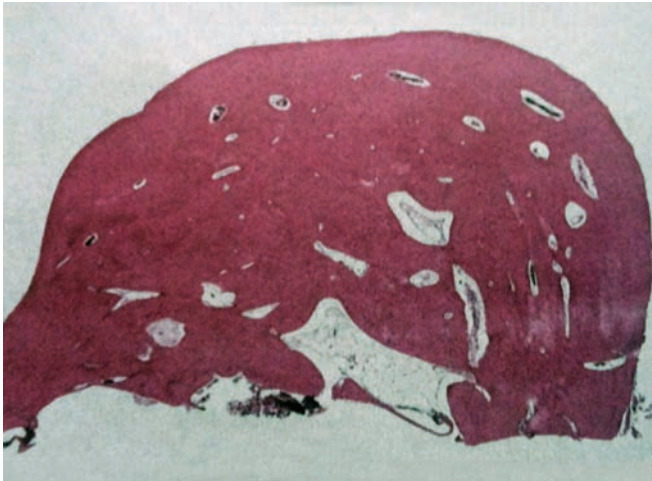
Postoperative instructions regarding wound care, diet, maintenance of good oral hygiene, and medications (antibiotics and analgesics) were given to the patient. The excised specimen was sent in 10% formalin for histopathological examination (Fig. 5). Hematoxylin and eosin staining of the specimen revealed nodular masses of dense cortical bone organized in a lamellar pattern with an associated fatty marrow tissue at the inner zone of trabecular bone (Fig. 6).



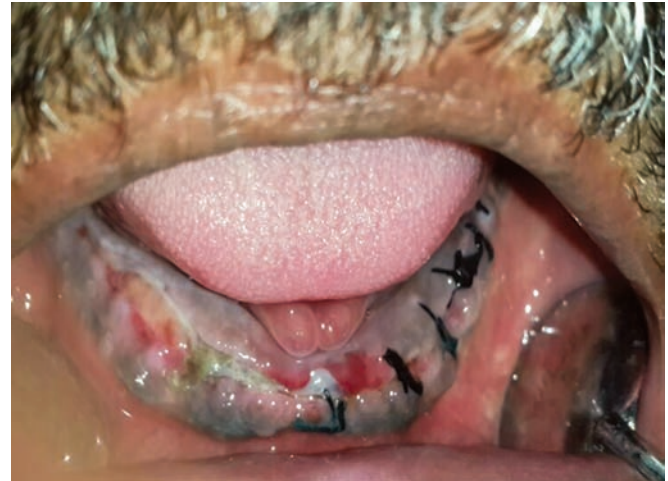**Fig. 4:** Closure of the wound with 3-0 silk sutures on left side and cyanoacrylate glue on the right side



**Fig. 5:** Excised specimen



**Fig. 6:** Histopathological picture revealing lamellar patterned nodular masses of dense cortical bone with an associated fatty marrow tissue at the inner zone



**Fig. 7:** Postoperative healing after 1 week

Evaluation of the wound was done on 1st and 3rd postoperative days and sutures were removed on the 7th postoperative day (Fig. 7). The long-term follow-up revealed excellent postoperative healing of the glued side with no pain or erythema, compared to the sutured side. The patient was referred for fabrication of the missing teeth (Fig. 8).

## DISCUSSION

Tori are small bony growths routinely found in adult patients. They are usually asymptomatic and often incidentally found during routine clinical examinations. They vary in size, shape, and number, but are often bilateral and sometimes can attain very large sizes. Tori are classified according to their shapes as flat tori which are smooth and convex in shape, spindle-shaped tori usually present in the mid-palatine region, lobular tori which are lobulated masses arising from a single base, and nodular tori which appear as multiple protuberances with individual bases.<sup>3,5</sup>

The etiology of tori is not clear, but the most commonly accepted cause is genetics, although the autosomal dominant nature has been found to be proven only in approximately 29.5% of the cases.<sup>1</sup> Another common cause is superficial injuries to the overlying mucosa, especially in individuals with well-developed chewing muscles<sup>6</sup> or in patients with abraded teeth due to occlusion.<sup>7</sup> Other rare causes include eating habits, vitamin deficiency, and drugs inducing increase in calcium hemostasis.<sup>8,9</sup>

The incidence of tori ranges from 9.2 to 66% for palatal torus and 0.5 to 63.4% for the mandibular torus.<sup>10</sup> Mandibular tori incidence varies among different races with a prevalence of 6 to 12.5% among Africans and Caucasians and 26 to 61% in Inuit and Aleutin individuals with even higher incidences in the Asians.

Surgical excision is usually not indicated unless they interfere with the normal functions of the oral cavity, produce difficulty in maintenance of oral hygiene in dentulous patients, cause technical difficulty in denture fabrication, predispose to any periodontal problems, or become inflamed or ulcerated.<sup>3</sup>

Excision of the mandibular tori is usually a safe and predictable procedure with minimum postoperative sequela.<sup>2</sup> Care should be taken at the time of reflection of flaps, as the overlying mucosa is very thin and avascular. Larger torus can be excised uneventfully using high-speed burs or chisels. However, chisels should be carefully used as their slippage can cause soft-tissue injuries. Smaller tori can be easily reduced with flame-shaped burs. However, gross reduction of adequately larger-sized torus can lead to accumulation of osseous debris underneath the flap, which can compromise healing.<sup>3</sup> Use of surgical cements is recommended after removal in dentulous patients to prevent the wound from mechanical trauma. In case of maxillary tori, surgical splints should be placed after closure to prevent hematoma formation.

Complications of tori excision with burs or chisel techniques include postoperative pain, edema, appearance of bony spicules, salivary duct injuries, lingual nerve injury, perforation of lingual plate, emphysema, wound dehiscence, and infection.

Monopolar or bipolar electrosurgical units can be used for making incisions mesial and distal to the tori, prior to their removal with burs and chisels. They offer the advantage of producing smooth flap edges than that will be produced with a scalpel incision. Bipolar electrosurgical units produce smaller temperature gradients at 1 mm tissue depth compared to monopolar electrosurgical units; also it does not produce arcing of tissues while cutting near metallic restorations or implants.<sup>2</sup> The coagulation of capillaries produced during

incision causes hemostasis, thereby providing a clear surgical field.

Use of lasers is one of the recent techniques for excision or smoothing of the torus. The laser apparatus consists of an output power source to regulate the pulse durations and fluence, and a sapphire tip of different diameters. A smaller tip diameter with low pulse durations is used for incising the overlying mucosa, which is then reflected. A larger diameter sapphire tip with higher pulse durations and fluence is then moved in a linear fashion in light contact with the base of the tori, which is then completely excised. Larger palatal tori are sometimes required to be sectioned vertically at the center, and removed in two pieces. The wound is then closed with non-resorbable sutures and removed postoperatively on the 7th day.

The advantages of lasers are that it precisely and efficiently cut the osseous structures with minimum damage to the surrounding tissues and exhibit less heat transfer to the bone. It provides a rapid technique for removal with minimum intraoperative bleeding, less discomfort to the patient, and excellent postoperative healing.<sup>3</sup> Also, the bacterial colonization at the surgical site is minimum. However, it is technique-sensitive and expensive.

Cyanoacrylate tissue glues for the closure of incisions are in use for many years in oral and maxillofacial regions, but their use after tori excisions is limited. They are acrylic resins that rapidly polymerizes in the presence of water, forming a long strong chain and bonding the surfaces together. They are safe, easy to use, and provide rapid and painless technique of closure. Also, the risk of needle stick injury to the patient and the surgeon is avoided, with good cosmetic results.<sup>11</sup> They are easily available, generally not very expensive, and the incidence of allergy is minimum. Apart from these advantages, it also reduces the risk of tissue tear during suturing, especially the thin, fragile lingual flaps, like in this case.

Generally, most of the postoperative problems after tori excisions are iatrogenic, and the patient almost always experiences significant relief in symptoms. The replacement of teeth with prosthesis or implants is usually not a problem and mostly successful.

## CONCLUSION

Surgical excision of torus is one of the routinely performed minor surgical procedures. Precautions pertaining to flap reflection, excision, and closure usually avoid most of the postoperative complications. In the current case, surgical resection of the bilateral, multiple nodular mandibular torus with the combination of surgical burs

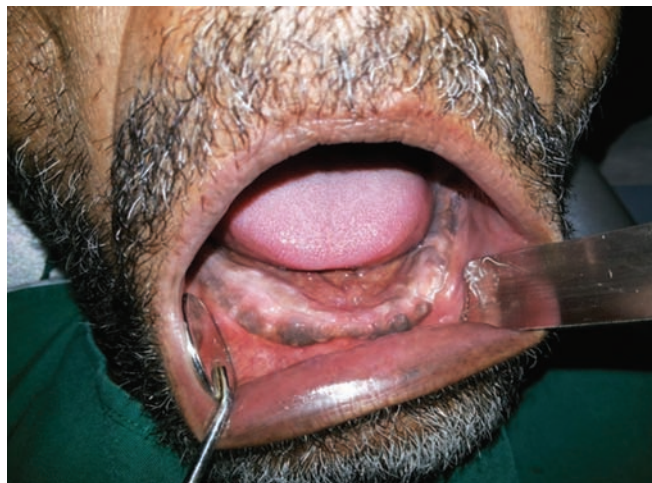

Fig. 8: Postoperative healing after 1 month

and chisel mallet technique yielded satisfactory results, and discomforts of the patient like speech difficulty, recurrent ulcerations, and food lodgment subsided completely; also the mucosa from lingual alveolar portion to the floor of mouth was smooth and intact. Closure with cyanoacrylate tissue glue on one side of the incised wound was found to be a quick procedure with minimum postoperative pain, erythema, and excellent long-term healing compared to the other sutured side of the wound. No complications like wound dehiscence, infection, emphysema, salivary duct injuries were encountered. However, a much larger sample of study is required to prove the efficacy of cyanoacrylates in intraoral closure of wounds.

## REFERENCES

- Garcia A, Gonzalez JM, Font R, Rivaderneira A, Roldan L. Current status of the torus palatinus and torus mandibularis. *Med Oral Path Oral Cir Buccal* 2010 Mar 1;15(2): e353-e360.
- Kurtzman GM, Silverstein LH, Shatz PC. A technique for surgical mandibular exostosis removal. *Compend Contin Educ Dent* 2006;27(10):520-525.
- Rocca JP, Raybaud H, Merigo E, Vescovi P, Fornaini C. Er: YAG laser: a new technical approach to remove torus palatines and torus mandibularis. *Case Rep Dent* 2012;2012: 487802.
- Seah YH. Torus palatinus and torus mandibularis: a review of the literature. *Aust Dent J* 1995 Oct;40(5):318-321.
- Haugen LK. Palatine and mandibular tori: a morphological study in the current Norwegian population. *Act Odontol Scand* 1992 Apr;50(2):65-77.
- Al Bayaty HF, Murti PR, Mathews R, Gupta PC. An epidemiological study of tori among 667 dental outpatients in Trinidad and Tobago, West Indies. *Int Dent J* 2001 Aug;51(4): 300-304.
- Jainkittivong A, Langlais RP. Buccal and palatal exostosis: prevalence and concurrence with tori. *Oral Surg Oral Med Oral Pathol Oral Radiol Endod* 2000 Jul;90(1):48-53.

8. Eggen S. Torus mandibularis: an estimation of the degree of genetic determination. *Acta Odontol Scand* 1989 Dec;47(6): 409-415.
9. Kolas S, Halperin V, Jefferis K, Huddleston S, Robinson HB. The occurrence torus palatinus and torus mandibularis in 2478 dental patients. *Oral Surg Oral Med Oral Pathol* 1953 Sep;6(9):1134-1141.
10. Shimahara T, Ariyoshi Y, Nakajima Y, Shimahara M, Kurisu Y, Tsuji M. Mandibular torus with tongue movement disorder: a case report. *Bull Osaka Med Coll* 2007 Dec;53(3): 143-146.
11. Sameena T, Sethy SP, Patil P, Shailaji K, Ashraf O. Cyanoacrylate: a bioadhesive for suture less surgery: a review. *Asian J Res Chem* 2014 Mar;7(3):349-354.