

**EMS Solutions**

*Presents*

# **The Basics of 12 Lead EKG's**

**NOTICE:** You DO NOT Have the Right to Reprint or Resell this Publication.

However, you **MAY** give this report away, provided you do not change or alter the contents.

© **Copyright EMS Solutions ALL RIGHTS RESERVED.** No part of this publication may be reproduced or transmitted in any form whatsoever, electronic, or mechanical, including photocopying, recording, or by any informational storage or retrieval system without the expressed written, dated and signed permission from the author.

**DISCLAIMER AND/OR LEGAL NOTICES:**

The information presented herein represents the views of the author as of the date of publication. Because of the rate with which conditions change, the author reserves the right to alter and update this information based on the new conditions. The publication is for informational purposes only. While every attempt has been made to verify the information provided in this publication, neither the author nor its affiliates/partners assume any responsibility for errors, inaccuracies or omissions. Any slights of people or organizations are unintentional. If advice concerning medical, legal or related matters is needed, the services of a fully qualified professional should be sought. You should be aware of any laws/practices or local policies which govern emergency care or other pre hospital care practices in your country and state. Any reference to any person or business whether living or dead is purely coincidental.

# 12-LEAD ECG INTERPRETATION

## INTRODUCTION

The objective of this report is to provide Paramedics with basic knowledge prior to the introduction of acquiring 12-lead ECGs as part of their scope of practice. Acquisition of 12-lead ECGs will become an additional tool, along with current assessment skills, for identifying patients suffering from an acute myocardial infarction. The importance of obtaining a 12-lead ECG is for early identification of potential myocardial ischemia so that the cause can be appropriately treated and, hopefully, reversed.

Don't be alarmed if you have difficulty with rhythm interpretation or reading a Lead II strip. When reading a 12-lead ECG, you are looking for different information that is not seen in the basic Lead II strip. These differences will become obvious to you as you work through this package.

### ***Why 12-Leads? I Have Enough Problems with Lead II!***

This question is constantly being asked by paramedics that see the tracings of a 12-lead ECG as something too imposing for them to even consider being useful in prehospital care. This is primarily due to the fact that we normally look at a tracing generated by our monitors (Lead II) and we are expected to be able to quickly come up with one of the fancy names for the bizarre, electrically generated line. Doctors frequently argue over what the Lead II tracing reveals and this is why it is referred to as rhythm interpretation. One individual or doctor's interpretation can be different from another and that is frequently acceptable as long as the rules of rhythm interpretation were used. A 12-lead ECG is much more specific as it is a diagnostic tool looking at the electrical activity of various sections of the heart simultaneously. It can allow the person reading the 12-lead ECG to identify early signs of ischemia, injury and infarction of very valuable heart muscle.

By obtaining a 12-lead ECG early in our prehospital assessment, we are also able to provide a "premedicated" picture of the electrical activity of the heart. How important is this? We have all heard the story of a patient that a crew picked up, assessed as having ischemic chest pain, treated with oxygen, nitroglycerin and ASA, and arrived at the hospital with the patient being pain free. The patient was assessed, including having a 12-lead ECG done, and was discharged prior to completion of the ACR. The ambulance crew working the next shift found the patient VSA. This is a scenario that can happen to any one of us. Will the 12-lead prevent this from ever happening again, if the ECG obtained in the emergency department did not show anything? No, it may not prevent it from happening again but having a 12-lead ECG of the patient's electrical conduction in the myocardium may provide enough information to encourage the doctor to order additional tests to rule out a myocardial infarction (MI) and, if necessary, take the appropriate steps to prevent a reoccurrence.

Consider this - approximately 50% of MIs result in prehospital death due to arrhythmias (VF). Paramedics, as well as the community at large, have been educated regarding the reduction of deaths due to arrhythmias possible from the use of rapid defibrillation. The next logical step is the reduction of these fatal arrhythmias. Studies show that the first 60 minutes following the onset of ischemic chest pain is the time of highest risk for VF or VT; we need to try to affect care in this 60-minute window. When you also consider that, due to denial or lack of identification, many patients wait greater than two hours before seeking assistance, we as paramedics or as one of the first links of the chain of life are already working on borrowed time. Early identification of the signs of a myocardial infarction by the patient, by EMS with appropriate prehospital care and by the emergency department should reduce this 50% mortality rate in MIs<sup>1</sup>.

## **GETTING STARTED**

We will be looking at only one main aspect of the 12-lead ECG and that is to be able to recognize and localize an Acute Myocardial Infarction (AMI). While many aspects of 12-lead interpretation require much study and practice, we will be focusing on identifying the pattern of ST segment elevation produced by an AMI. To do this we must use consistent terminology and reference points on the 12-lead printout.

We will start at the very beginning with the paper the tracing is printed on. It is the same paper the monitor normally prints on, so all of the same factors apply.

- Small squares = 1 mm in height and 1 mm in width
- Large squares = 5 mm in height and 5 mm in width

You require this knowledge because when assessing the 12-lead ECG you will be looking for ST segment elevation greater than 1 mm. Knowing that one small square is 1 mm in height means you do not require a measuring tape.

The paper runs at a constant speed of 25 mm/sec, so 1 small square (1 mm in width) equals 0.04 seconds. Each block of 5 small squares (5 mm or one large square) equals 0.20 seconds. This information is needed to help calculate rate and other timed intervals of the ECG. A major difference between a tracing used for rhythm interpretation and the tracing of the 12-lead is in the time. Strips between 6 and 10 seconds are required for rhythm interpretation to be able to review the pattern and, therefore, identify the rhythm. The 12-lead tracing prints approximately only 2.5 seconds of the rhythm which is not enough to do accurate rhythm interpretation but is usually enough to give you one good complex in each lead. With the 12-lead you compare the complexes generated simultaneously by the various “views” or leads.

## Identifying Components of the ECG (A Review)

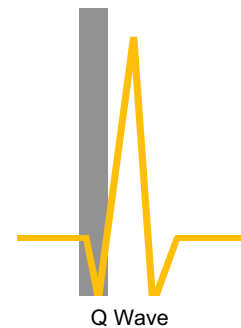
### ***P Wave***

The P wave is the first positive (upward) deflection on the ECG. It represents atrial depolarization (contraction). It is normally nicely rounded and precedes the QRS complex. The QRS complex may not always be “related” or following a P wave if conduction disturbances are present. Changes in the shape of the P wave or inversion, indicate a change in the originating site of the P wave in the atria. This is frequently referred to as a wandering pacemaker.

### ***Q Wave***

The Q wave is a negative wave preceding an R wave. Not all complexes have a visible Q wave, but if there is any negative deflection in front of the R wave, it is labeled a Q wave.

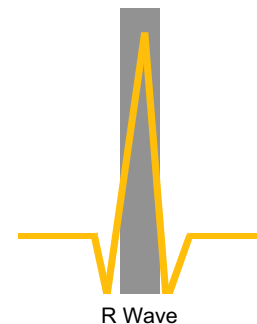
When a Q wave is noted in any lead, always measure its width and height. The width is measured from the start of the downward deflection to its return to the isoelectric line. When present a Q wave that is less than 0.04 seconds (<1 small square in width) in duration is referred to as a physiological Q wave and is considered a normal occurrence. A Q wave that is greater than 0.04 seconds (>1 small square in width) and is at least 25% of the height of the R wave is considered a pathological Q Wave and indicates irreversible damage (necrosis). This may be part of the presenting complaint or indicative of a previous infarction.



### ***R Wave***

The R wave is the first positive deflection of the QRS complex. No matter where it occurs in the complex, the R wave is the first positive deflection above the isoelectric (base) line.


The R wave includes the upstroke and the down stroke returning to the isoelectric line.



### ***S Wave***

The S wave is a negative deflection following the R wave. Measuring the S wave is the same as the Q and R waves; it starts at the base line and returns to the base line.

The R and S waves combined represent the sum of electrical forces resulting from simultaneous depolarization of the right and left ventricles (systole, contraction). It is possible to have more than one R wave and more than one S wave in a complex. This will be discussed further at a later time but, for now and for your reference, this is often what you will hear people refer to as “bunny ears” which is indicative of a bundle branch block.



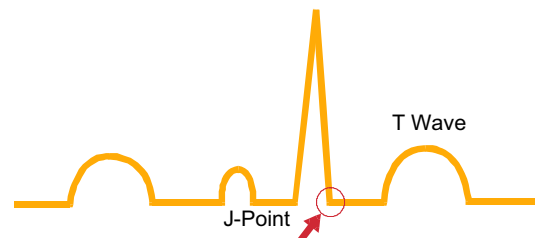
The combination of the Q, R and S waves makes up the QRS complex. The normal QRS complex is narrow and sharply pointed. Its width is considered normal if less than 0.12 seconds or 3 small boxes. If the QRS complex is equal to or greater than 0.12 seconds or 3 boxes, this is indicative of some sort of conduction problem through the heart tissue.

### ***T Wave***

The T wave follows the QRS complex and represents the repolarization of the ventricular myocardial cells. It is identified as the first deviation from the ST segment and ends where the wave returns to the baseline. The shape of the T wave can indicate different aspects of myocardial health. Healthy myocardial tissue will produce a rounded, slightly asymmetrical positive deflection. Inverted or depressed T waves may indicate previous or current cardiac ischemia but are usually an early sign of an ongoing or current ischemic event. Elevated T waves (> half the height of the QRS complex) are referred to as peaked or tented T waves and are usually indicative of new ischemia or hyperkalemia.

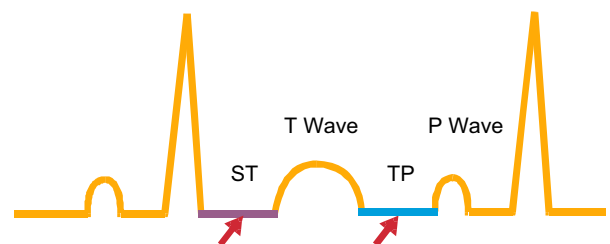
### ***J-Point***

The J-point is the junction between the end of the QRS complex and the beginning of the ST segment. It is best located by looking for the point where the QRS stops and makes a sudden sharp change in direction. Any time that you have measured the width of a QRS complex you have measured from the start of the Q wave to the end of the S wave which means you have identified the J-point many times so this should not be new to you, it now just has a name. The J-point is used to help determine the length of the ST segment.



### ***ST Segment***

The ST segment is the portion of the ECG located between the J-point and the start of the T wave. For our purposes in reading a 12-lead ECG the ST segment is probably the single most important element when looking for



evidence of an Acute Myocardial Infarction. To determine if the ST segment is elevated or depressed, we need an isoelectric base line. The TP segment is used to determine the isoelectric baseline.

### ***TP Segment***

The TP segment is the section of the ECG between the end of one complex's T wave and the beginning of the next complex's P wave. This is where the tracing returns as close as possible to the baseline or isoelectric line. It is important to use the TP segment as your reference point as there are times that if the PR segment was used it could be depressed and give the illusion of ST segment elevation.

## **WHAT'S IN A LEAD?**

An important point in 12-lead interpretation is knowing which part of the heart each lead "views". This, combined with knowing what changes can take place in each of those leads, can result in the recognition of an acute myocardial infarction. Early identification of an acute myocardial infarction and early treatment can lead to reperfusion of valuable myocardium preventing both tissue death and the potential for a life threatening arrhythmia.

Let's review some basic terminology so that we are all talking the same language about the same things:

- Electrode – the end of the wire that connects the patient to the monitor

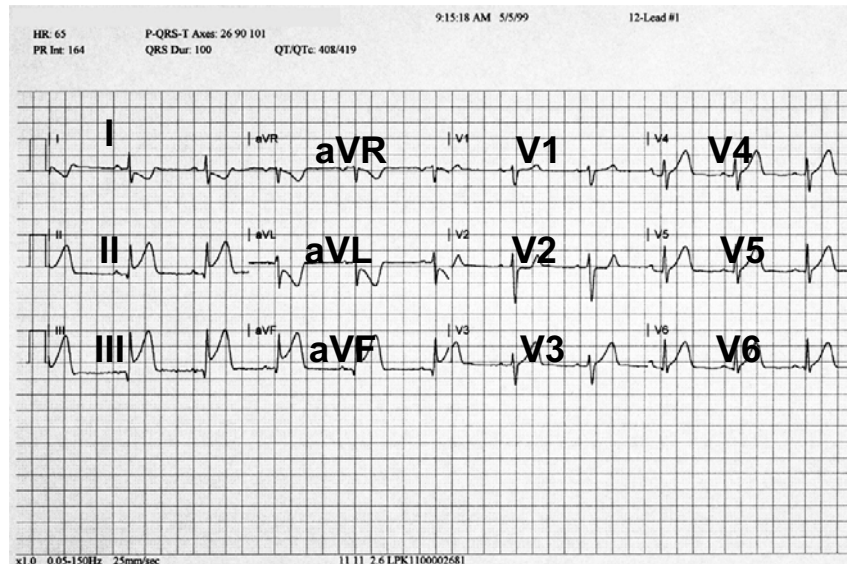
- Cables – the bundle of wires used to connect electrodes from the patient to the monitor

- Lead – made up of a negative and positive electrode that looks at different aspects of the heart depending on where the electrodes are located relative to each other.

This may seem basic but keeping these terms straight will help out as we move along.

A 12-lead ECG is made up of a tracing of the electrical activity of the heart from 12 different points of view. The point of view comes from the location of the positive electrode of each lead. The positioning of these electrodes is broken down into 3 categories, the limb leads (lead I, II & III), the augmented leads (aVR, aVL & aVF) and the precordial or chest leads (V1, V2, V3, V4, V5 & V6).

The 12-lead ECG, when printed, is laid out in a standard fashion as per the diagram. We will look at this again a little later on.



## Limb Leads

It is important to remember where the positive and negative electrode of each lead is placed in relation to the heart, so that you can identify which part of the heart the lead is looking at. If you were to place a camera at the positive electrode, facing the negative electrode, you would be taking a picture of the area of the heart that particular lead is looking at. The lead we are most familiar with is Lead II, which is one of the limb leads. Lead I, Lead II and Lead III combine to form a triangle around the perimeter of the heart. This triangle is frequently referred to as Einthoven's Triangle, named in the early 1900's after a pioneer in electrocardiography.

When acquiring a 12-lead, the limb leads are normally placed close to the ankles and wrists, but it is acceptable to use the upper arm/thigh. The right arm electrode is always negative and the left leg electrode is always positive. This combination, with the camera sitting at the positive electrode looking at the negative electrode, gives us Lead II and a view of the inferior wall of the left ventricle.

The left arm electrode can be switched between positive and negative depending on which lead is being viewed. Picture the camera sitting on the left arm when it is positive looking towards the negative (right arm) electrode. This is Lead I and gives us a view of the high lateral wall of the left ventricle. When the left arm electrode is negative and the view is from the positive left leg electrode, we are again looking up at the inferior wall of the left ventricle with just a slightly different angle.



## Augmented Leads

The augmented leads use the same lead locations as the limb leads. What gives us the difference in the view of the heart is the fact that all of the electrodes on the limbs are positive and they look towards the neutral center of the heart. Fortunately, changing the polarity of the electrodes is controlled by and completed rapidly by the monitor so we don't have to worry about how it's done, just what it's looking at.

When the positive electrode is at the right shoulder, this is referred to as augmented voltage right (aVR). The view we receive is of the upper right area of the heart and great vessels. This view is normally the least used view in 12-lead ECG interpretation.

When the positive electrode is at the left shoulder, this is referred to as augmented voltage left (aVL). The view we receive is of the high lateral wall of the left ventricle.

The final view, positive electrode on the left foot, is aVF or augmented voltage left foot. This lead gives us a view of the inferior wall of the left ventricle.

## Precordial Leads

The precordial leads, like the augmented leads, are all positive and all use the neutral center of the heart as their "focus" point. We will go into the actual physical identification for locating these leads in another module, for now it will be simplest to use the following chart to identify each electrode location and the section of the heart that the lead is viewing.

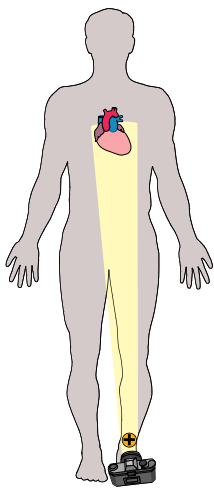
Lead	Location	View
V1	▪ 4 <sup>th</sup> intercostal space, right sternal border	▪ Ventricular septum
V2	▪ 4 <sup>th</sup> intercostal space, left sternal border	▪ Ventricular septum
V3	▪ Between V2 and V4	▪ Anterior wall of left ventricle
V4	▪ 5 <sup>th</sup> intercostal space, midclavicular line	▪ Anterior wall of left ventricle
V5	▪ Lateral to V4 at the anterior axillary line	▪ Lateral wall of left ventricle
V6	▪ Lateral to V5 at midaxillary line	▪ Lateral wall of left ventricle

You may have noticed that in a 12-lead ECG, the left ventricle is the target or viewpoint. Remember that the left ventricle is the largest, most muscled portion of the heart and, therefore, is an area that is first to "complain" of the pain associated with a decrease in tissue perfusion (for example, angina). As well, tissue damage in the left ventricle can result in a potentially more lethal arrhythmia (atrial fibrillation compared to ventricular fibrillation). Something else you may have noticed is leads that look at the same portion of the left ventricle. These are considered "**Anatomically Contiguous**" leads. This particular grouping of leads is a very important aspect of 12-lead ECG interpretation.

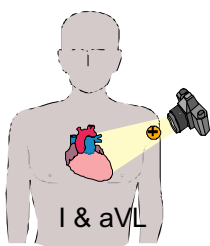
Anatomically contiguous leads are two or more leads that look at adjoining areas of tissue. Determining which leads are contiguous may be confusing, but the easiest explanation is this; if the leads have the same name (for example, inferior) they are contiguous. With the chest leads, if they are consecutively numbered they are also contiguous. For example, V2 is called a septal lead and V3 an anterior lead, not the same name but they are both chest leads and numerically consecutive so, therefore, they are contiguous.

## REVIEW

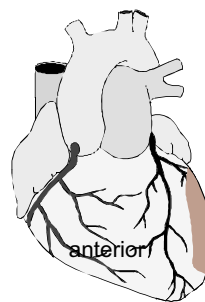
The following illustrations may make the previous section a little clearer. Understanding what the leads are viewing and if they are contiguous is as important in interpreting a 12-lead ECG as the changes that you will be looking for.



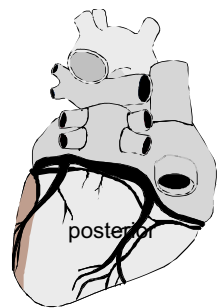
Leads II, III and aVF are leads that have their positive electrode located at the left foot. They are contiguous leads that all look at the inferior wall of the left ventricle.

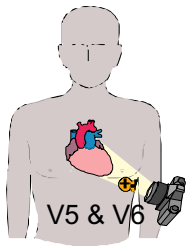


Leads I and aVL are leads that have their positive electrode located on the left arm. These leads view the high lateral wall of the left ventricle.



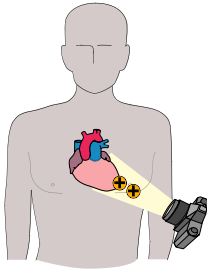
Lateral Wall



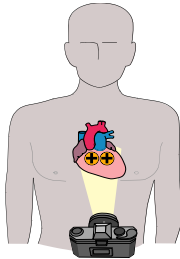


Leads V5 and V6 are positioned on the left lateral chest and view the lower lateral wall of the left ventricle.

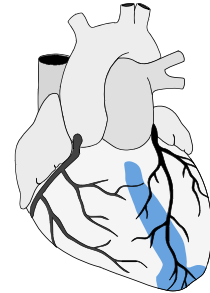
Since Leads 1, aVL, V5 and V6 all view the lateral wall of the left ventricle they are considered contiguous.



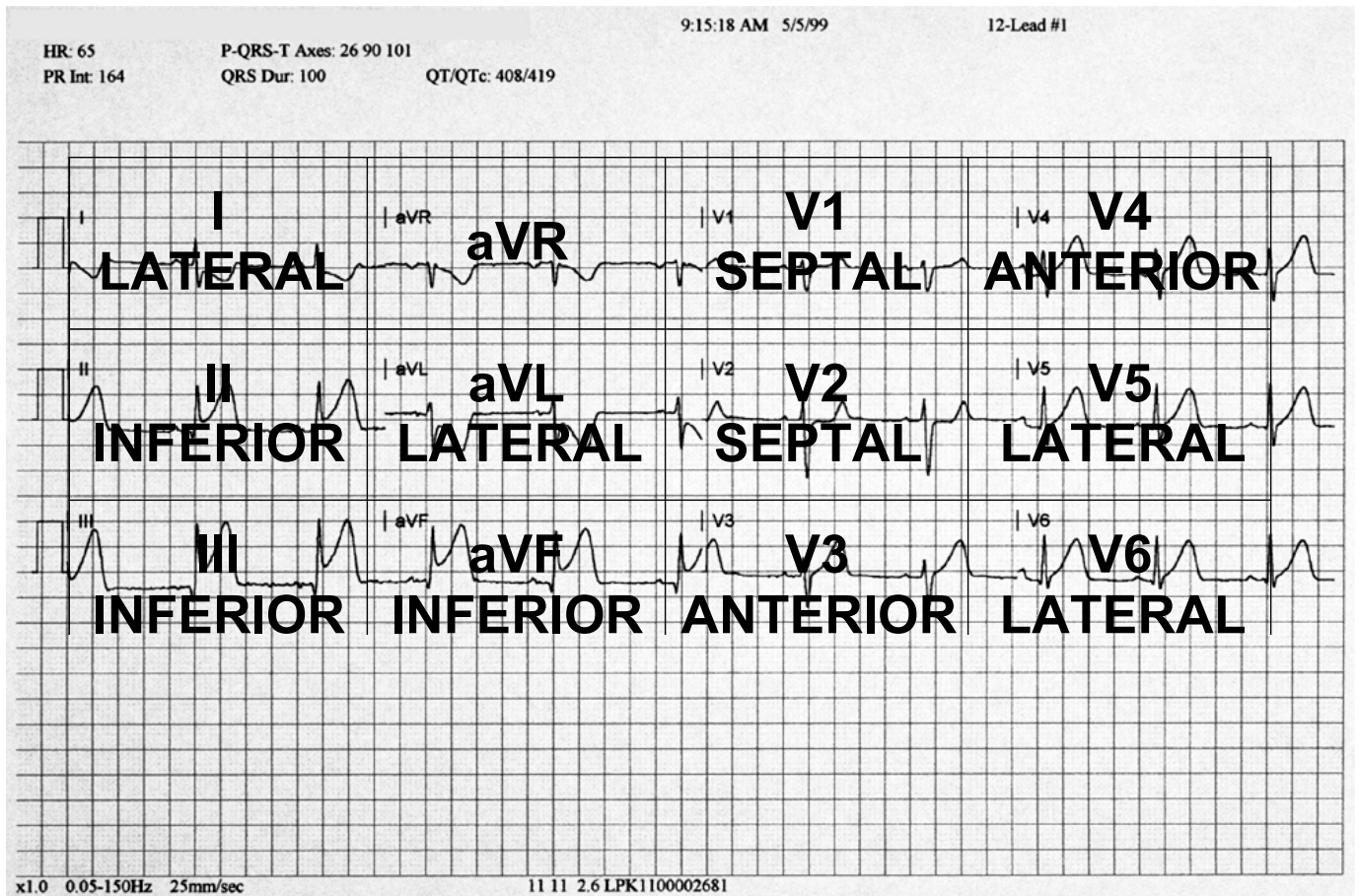
Leads V3 and V4 are on the anterior wall of the left chest which correlates with the viewing the anterior wall of the left ventricle.



Leads V1 and V2 are positioned on each side of the sternum and from that placement they “look through” the right ventricle and see the septal wall.



Going back to the earlier diagram of the 12-lead ECG and putting everything together on an overlaid diagram may look confusing at first but will become an excellent reference as you learn to interpret a 12-lead ECG.



## RECOGNIZING AN ACUTE MYOCARDIAL INFARCTION

Let's do a brief recap. We have looked at the components of an ECG tracing including identification of the QRS complex, and the ST segments. We have looked at what area individual leads are looking at or viewing. If I was to tell you there is only one more item required and a few rules to follow, would you believe you are ready to interpret 12-lead ECGs for the purpose of recognizing an acute myocardial infarction (AMI)?

It's true. For AMI recognition there are two things to know: what to look for and where to look. It will take some time to feel comfortable with interpreting the information of the 12-lead ECG but like most things it will come with time.

### What to Look For

When reviewing the 12-lead ECG there are two aspects to look at and consider. First look at the ST segments. Elevation of the ST segment equal to or greater than 1 mm

(1 small box) is the first indicator. The ST segment elevation is measured from the J-point. Secondly, look at the different leads. Is there ST segment elevation in two anatomically contiguous leads?

If you review a 12-lead ECG and you discover ST segment elevation greater than or equal to 1 mm in two contiguous leads, combined with the appropriate clinical presentation (found during your patient assessment), you have what is termed “presumptive evidence of an AMI”. This is generally a strong indication for acute reperfusion therapy usually in the form of a thrombolytic drug or coronary angioplasty.

## **SUMMARY**

This report has focused on some of the basics of 12-lead ECG interpretation.

Remember the goal of prehospital 12-lead ECG interpretation is to help to lessen the “door to needle” time for patients experiencing an AMI. We now have a prime opportunity for paramedics to impact on the phrase “time is muscle”.

Our impact can be identified in two ways. The first is by obtaining a pre-medication 12-lead ECG for comparison with a post-medication 12-lead ECG done in the hospital. Remember to always treat your patient first. If your patient is in severe distress, do not withhold treatment to do a 12-lead ECG. Changes can occur rapidly and the comparison of the 12-lead ECGs may indicate an increase in an infarcting area or may indicate that our prehospital treatment of oxygen, nitroglycerin and ASA had an immediate impact. The second is by rapid identification of patients who are candidates for reperfusion therapy. The patient benefits from both ways.

Many of you may be thinking that the time wasted taking a 12-lead ECG in the field could be better spent transporting the patient to the hospital. This is one of the hardest assumptions to deal with. Several studies have shown that obtaining a 12-lead ECG in the field takes minimal extra time. You will see that with practice, you will become more comfortable with land marking for the location of electrode placement. Your speed will pick up and this will be where a strong teamwork approach will have to take place to minimize the time spent with the patient.

## BIBLIOGRAPHY

Campbell MD, John Emory, Basic Prehospital Trauma Care, New Jersey: Brady Books, 1988.

Davis RCT, Dale, Differential Diagnosis of Arrhythmias, Philadelphia: W.B. Saunders Co., 1997.

Eishner MD, Gilber M.; Dox, Ida; Melloni, Biagio John; Melloni's Illustrated Medical Dictionary, Baltimore: The Williams & Wilkens Company, 1979.

Hazinski RN MSN, Mary Fran, Handbook of Emergency Cardiovascular Care for Healthcare Providers, Texas: American Heart Association, 2000.

Hole, John, Human Anatomy And Physiology, Iowa: Wm. C. Brown Company Publishers, 1978.

Justice, Bryan, ACLS Essentials, Mississauga: Canadian Health Educators, 1998.

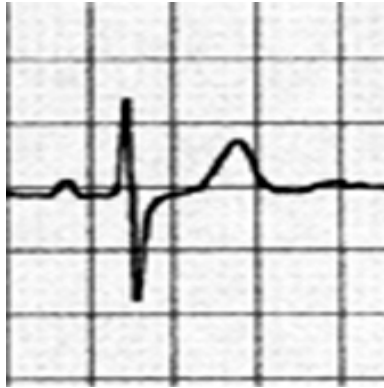
Phalen, Tim, 12-Lead ECG in the Acute Coronary Syndromes, Redmond: Acute Coronary Syndromes, Inc. / Medtronic Physio-Control Corp., 2000

Sanders. Mick J., Mosby's Paramedic Textbook St. Louis: Mosby Lifeline Books, 1995

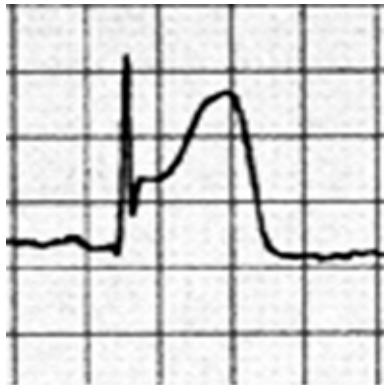
## PRACTICE – PART 1

Indicate on each of the following tracings the P wave, QRS complex, T wave, J point and ST section.

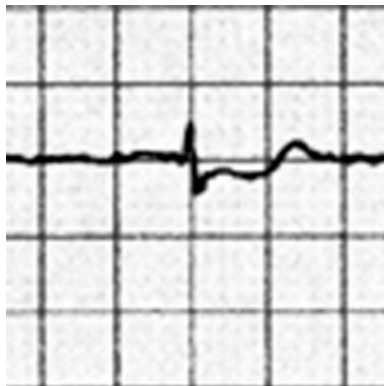
1.



2.



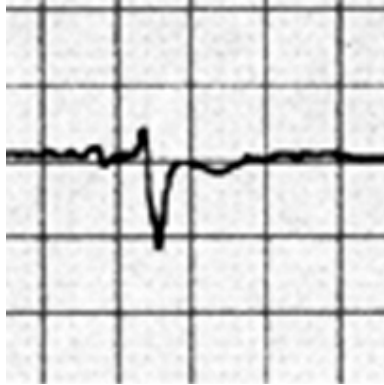
3.



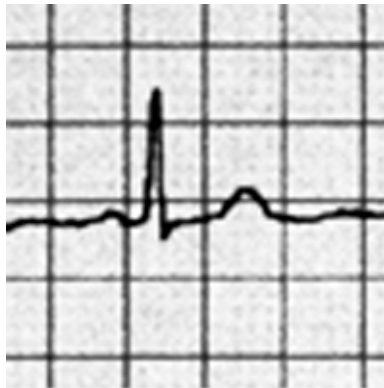
Name: \_\_\_\_\_

OASIS: \_\_\_\_\_

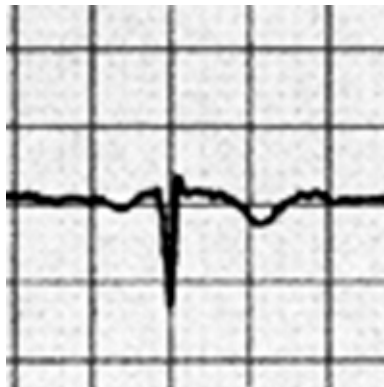
4.



5.



6.

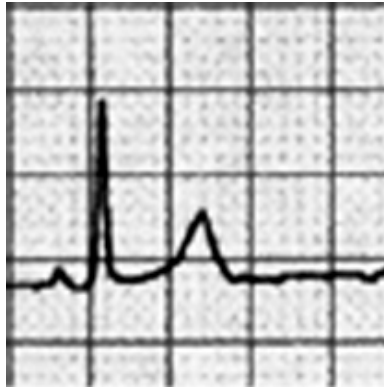

Name: \_\_\_\_\_

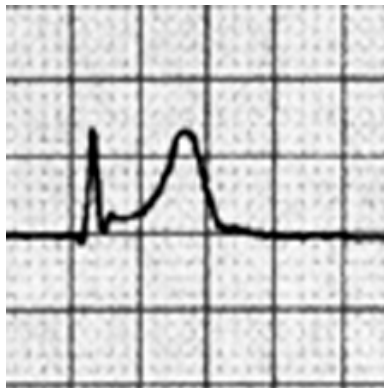
OASIS: \_\_\_\_\_



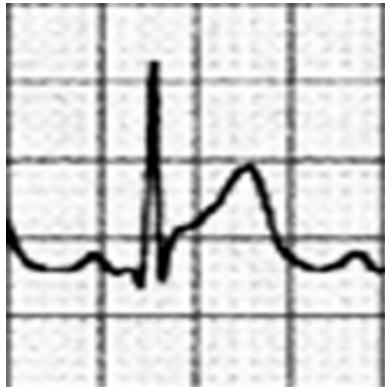
7. On the following tracings find the J-point and indicate if the ST segment is elevated > then 1 mm above the TP segment.



8.



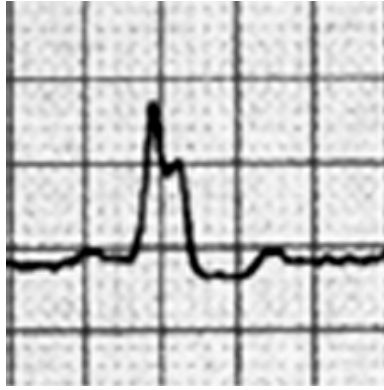9.



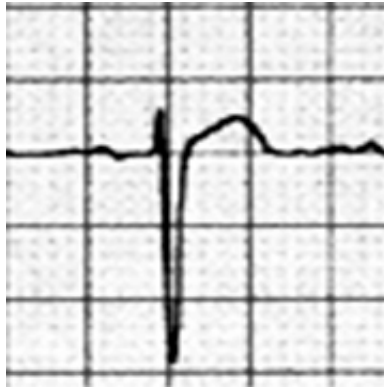
Name: \_\_\_\_\_

OASIS: \_\_\_\_\_

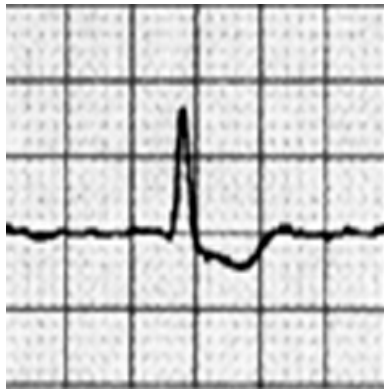10.



11.



12.



Name: \_\_\_\_\_

OASIS: \_\_\_\_\_

If you found this report useful, EMS Solutions recommends the following for further EKG study.

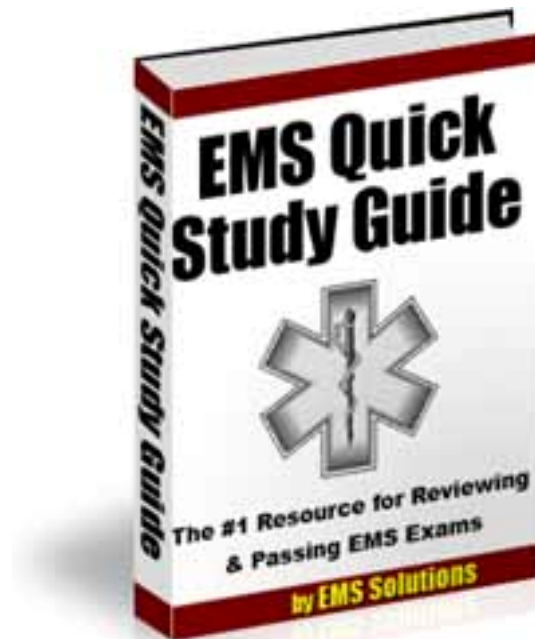
Download the Practice Resource pages from **Rapid Interpretation of EKG's** for Free.

Visit - <http://ems-safety.com/rapidekg.htm>

Don't forget that you can also get the absolute meat and potatoes of EMS study by using EMS Solutions **"Quick Study Guide"**

Now available in paperback.

Visit - [http://ems-safety.com/ems\\_quick\\_study.htm](http://ems-safety.com/ems_quick_study.htm)



Sign up for our newsletter for more free downloads and unique products from EMS Solutions.

Send a blank email to [emssafe@aweber.com](mailto:emssafe@aweber.com)