

“Scalp Block” During Craniotomy: A Classic Technique Revisited

Irene Osborn, MD and Joseph Sebeo, PhD

Abstract: Local anesthesia of the nerves of the scalp is referred to as “scalp block.” This technique was originally introduced more than a century ago, but has undergone a modern rebirth in intraoperative and postoperative anesthetic management. Here, we review the use of “scalp block” during craniotomy with its anatomic basis, historical evolution, current technique, potential advantages, and pitfalls. We also address its current and potential future applications.

Key Words: scalp block, local anesthesia, infiltration, craniotomy, technique

(*J Neurosurg Anesthesiol* 2010;22:187–194)

Anesthetic management of patients undergoing craniotomy can often be challenging, given the nature of surgery, the underlying central nervous system pathology, and the desire for punctual postoperative assessment. There is no consensus on the best anesthetic agents for use in neurosurgery. However, the idea of combining a regional anesthetic with a general anesthetic may offer advantages for most patients. Blocking noxious input to the abundant sensory nerve supply of the scalp would prevent the hemodynamic response to head pin application and the pain of incision. Local anesthetic infiltration before craniotomy incision is an accepted practice by many neurosurgeons, but this local anesthetic effect is short lived. A “scalp block” involves regional anesthesia to the nerves that innervate the scalp, providing analgesia for a considerable period of time with the potential for postoperative effect.

Combining regional and general anesthesia has the potential for decreasing intraoperative general anesthetic requirements and attenuating anticipated hemodynamic responses in many patients. This idea has been explored in the past when the effects of general anesthetics were deleterious in certain patients with brain injury. As neuroanesthesia got safer and more refined, the “scalp block” was abandoned or minimized. The current age of minimally invasive surgery and awake craniotomy has

brought renewed interest in this technique and its advantages for patients. This review presents the anatomy, history, clinical development, and technique for the “scalp block.”

ANATOMY FOR “SCALP BLOCK”

Sensory innervation of the scalp and forehead is provided by both the trigeminal and spinal nerves.

Innervation of the Anterior Scalp and Forehead

The trigeminal nerve is the largest cranial nerve and is the principal source of sensory innervation of the head and face. The trigeminal nerve has an ophthalmic, maxillary, and mandibular division, all of which contribute branches that innervate part of the forehead and scalp. To approximate the sensory distribution of these 3 divisions, imagine that there are 2 lines splitting the eyelids and the lips. Figure 1 displays innervation of the scalp and forehead.

The first and smallest division of the trigeminal nerve is the ophthalmic division (V1). It is a pure sensory nerve, carrying sensation from the ipsilateral side from upper eyelids, the cornea, ciliary body, iris, skin of the forehead, eyebrows, and the skin of the nose. The largest branch of the ophthalmic division is the frontal nerve, which enters the orbit through the superior orbital fissure, before dividing (midway between the apex and base of the orbit) into 2 branches, the supraorbital and supratrochlear nerves.¹

These 2 branches supply sensory innervation to the forehead and anterior scalp.¹ Emerging from the supraorbital foramen or notch, the supraorbital nerve trunk divides into deep and superficial branches. The deep branches course superiorly and laterally, running in the areolar tissue between the galea and pericranium, with terminal branches supplying scalp sensation by piercing the galea near the coronal suture. The superficial branches divide into multiple smaller branches, which pierce the frontalis muscle, and also supply sensation to the anterior scalp.

The supratrochlear nerve courses through the supraorbital foramen, giving off palpebral filaments to the upper eyelid. It further ascends on the forehead and splits into medial and lateral branches. Located beneath the frontalis muscles, the medial and lateral branches respectively perforate the frontalis and galea aponeurotica.

Received for publication August 28, 2009; accepted January 14, 2010.
From the Department of Anesthesiology, Mount Sinai School of Medicine, New York, NY.

Reprints: Irene Osborn, MD, Department of Anesthesiology, The Mount Sinai School of Medicine, One Gustave L. Levy Place, New York, NY 10029 (e-mail: irene.osborn@mounsinai.org).
Copyright © 2010 by Lippincott Williams & Wilkins

The maxillary major division of the trigeminal nerve (V2) is a purely sensory nerve and it is relevant to “scalp block,” as it carries sensation from face up to the zygomatic cheek prominence through its cutaneous branches (infraorbital, zygomaticofacial, and zygomaticotemporal nerves).

The third and the last major branch of the trigeminal nerve is the mandibular division (V3), which carries sensation from the lower lip and the lower part of the face (mental and buccal branches), and the auricle and the scalp in front of and above the auricle through its auriculotemporal cutaneous branches.¹

Innervation of the Posterior Scalp

The greater occipital nerve arises from the posterior ramus of the second cervical nerve (C2) root, and innervates the major portion of the posterior scalp. It originates in the posterior neck, lateral to the atlantoaxial joint and deep into the oblique inferior muscle.^{2,3} It then ascends in the posterior neck over the dorsal surface of the rectus capitis posterior major muscle, before it becomes subcutaneous slightly inferior to the superior nuchal line, passing above an aponeurotic sling. At this point, the greater occipital nerve is immediately medial to the occipital artery. However, after piercing the posterior cervical aponeurosis, the nerve crosses medial to the occipital artery to the lateral portion of the posterior portion of the occiput.^{2,3} The lesser occipital nerve is derived from the ventral rami of the C2 and C3 spinal

nerves, and courses upward to carry sensation from the skin of the scalp that lies just behind the auricle.²

In summary, innervation to the forehead and anterior scalp is supplied by the supraorbital and supratrochlear nerves, with temple sensory innervation provided by the auriculotemporal and zygomaticotemporal nerves. The posterior scalp principally gets nerve supply from the greater occipital nerve whereas the lesser occipital nerve supplies the scalp skin behind the ear (Fig. 1).

“SCALP BLOCK”: EVOLUTION THROUGH THE AGES

Local Anesthetics: Early Beginnings

Local anesthetic techniques were pioneered by Halstead⁴ and Hall who performed nerve blocks using cocaine in the 1880s. Corning⁵ also promoted this early use of local anesthesia with cocaine. The term “regional anesthesia” was first introduced by American surgeon, Harvey Cushing⁶ at the turn of the 19th century, when describing pain relief after the use of nerve block. Early in the 1900s, Harvey Cushing pursued his experimentations with local anesthetics and along with George Crile, started to combine local or regional anesthetics with general anesthetics or with local infiltration anesthesia in craniotomies.

Scalp skin incision during craniotomy is accompanied with tachycardia and arterial hypertension. Increases

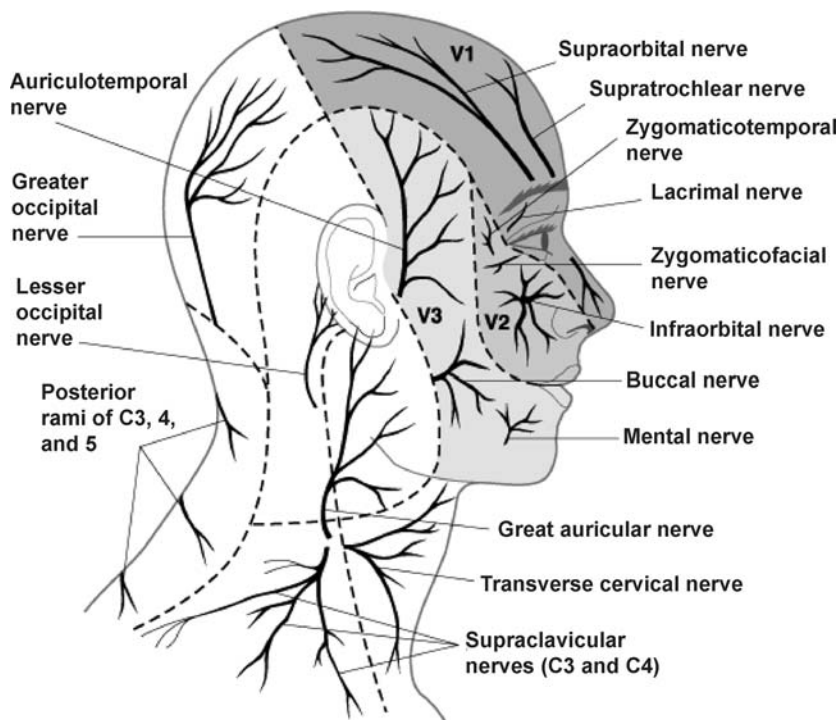


FIGURE 1. Innervation of the scalp and face. Source: Lalwani AK: Current Diagnosis & Treatment in Otolaryngology – Head and Neck Surgery, 2nd edition: <http://www.accessmedicine.com>. Authorization obtained from McGraw-Hill companies to use this copyrighted material.

in hypertension may also be accompanied with increases in intracranial pressure associated with potential increase in morbidity.⁷ This can be controlled by anti-hypertensive medications or increase in anesthesia depth, which can possibly result in hypotension. Another approach is to inject local anesthetics before surgery to prevent these hemodynamic changes. Subcutaneous infiltration of local anesthetics containing vasopressor agents has been used since the early 1900s to provide hemostasis during skin incision for craniotomy, with the first description by Braun in 1910.⁸ Mixtures of local anesthetics and vasoconstrictors continued to be injected before scalp incision to promote hemostasis for the following decades, including uses by Penfield and Christensen et al^{9,10}

It was not until the middle of 1980s that Hillman et al¹¹ performed the first double-blind randomized study to compare the effects of 0.5% bupivacaine with normal saline injection in patients undergoing craniotomies; an increased cardiovascular hemodynamic stability was found in the bupivacaine group. By injecting local anesthetics into the incision line and the line of scalp flap reflection, these agents block afferent neural pathways.¹¹ Four years later, Hartley et al¹² demonstrated similar results in children undergoing supratentorial craniotomy. In this study, responses of mean arterial pressure and heart rate to scalp incision and reflection were attenuated by infiltrating the scalp subcutaneously along the proposed incision line with bupivacaine coupled with epinephrine. Bupivacaine became the local anesthetic of choice for scalp infiltration due to its long duration of action and was reported to be safe when used in the vascular tissues of the scalp.¹³ However, although widely used, these techniques still represented local infiltration, and not “scalp block” with targeted injection of the nerves.

From Scalp Infiltration to Scalp Nerve Block

Recent studies have confirmed that local anesthetic infiltration of the scalp before craniotomy is effective in reducing tachycardia and hypertension, which could result in increased cerebral blood flow and intracranial pressure.¹⁴ This is especially true for patients with impaired cerebral autoregulation, in whom a small increase in blood pressure could result in large changes in cerebral blood flow and volume, further precipitating intracranial hypertension.¹⁵ This concept was also demonstrated by Bithal et al¹⁶ who showed that after skull pinning, bispectral index monitoring values were increased along with hemodynamic parameters, and that these changes can be prevented by prepinning infiltration with local anesthetics. Local anesthetic infiltration can also prevent the need for increased analgesic requirements early in the surgical procedure.¹⁴

A major step in local anesthesia of the scalp occurred with the transition from scalp infiltration to blocking the nerves of the scalp. One major advantage of performing “scalp block” is that most of the nerves supplying the scalp are superficial terminal sensory branches and hence the risk for nerve damage is lower than for deeper

motor nerves. Although Girvin¹⁷ originally described the “scalp block” technique in 1986 for use during awake craniotomy, the technique did not gain its due popularity for several more years. The first clues that blocking of the nerve supplying the scalp may be beneficial in achieving hemodynamic stability during craniotomy came in 1992. In this study, Rubial et al¹⁸ divided 34 patients with intracranial masses undergoing craniotomy into 3 groups: group I received fentanyl before implantation of a head fixation device, group II was treated with subcutaneous infiltration of mepivacaine at head fixation sites, and group III underwent blockade of frontal and occipital nerves. They found that mean arterial blood pressure after head fixation was significantly higher in group I than in groups II and III. This suggests that the direct blockade of frontal and occipital nerves is a useful method for maintaining hemodynamic stability during skull pin placement for neurosurgery.¹⁸ However, one pitfall is that this study did not have a control group receiving saline injections for comparison.

Four years later, Pinosky et al¹⁹ addressed this issue. The authors performed a prospective randomized double-blind study comparing the effects of “skull block” with normal saline to 0.5% bupivacaine on the autonomic response and the anesthetic requirement associated with head pinning. Twenty-one patients undergoing elective craniotomy for tumor requiring the use of head pinning were thus randomly allocated to a control group and a bupivacaine group. Five minutes before pinning, a “scalp block” was performed consisting of local anesthetic injection into the supraorbital and supratrochlear nerves, postauricular branches of the great auricular nerves, auriculotemporal nerves, and greater and lesser occipital nerves.¹⁹ The authors found a significant increase in mean arterial pressures, heart rate, and requirement for volatile anesthetic at pinning in the control group but not in the bupivacaine group. The control group had substantially higher values of baseline-adjusted hemodynamic variables during “scalp block,” head pinning, and after head pinning, compared with the bupivacaine group.¹⁹ These findings were corroborated by more recent studies, in particular, the double-blind randomized study by Lee et al,²⁰ which showed that 0.25% bupivacaine “scalp block” provides effective hemodynamic control (when compared with an injection of 0.9% saline) during the early stages of a frontotemporal craniotomy.

An increase in catecholamine plasma levels can be an index of increased sympathetic activity in cases of consistent catecholamine reuptake and clearance rates, and has recently been associated with postoperative hypertension in patients undergoing craniotomy.²¹ Hypertension in these patients is also associated with increased activation of the renin-angiotensin-aldosterone system. However, despite demonstrating lower values of mean arterial pressure and heart rate during craniotomy in patients receiving bupivacaine “scalp block,” Lee et al failed to demonstrate a significant difference in plasma catecholamine metabolites when compared with the control group. It is possible that the relatively small

number of patients (16) was insufficient to detect these changes, and future studies with larger sample sizes could address this issue.

“Scalp block” has also recently reemerged for use during awake craniotomy. Originally described by Girvin¹⁷ in the mid 1980s, the technique has seen a recent resurgence with blockade of the auriculotemporal, zygomaticotemporal, supraorbital, supratrochlear, lesser occipital, and greater occipital nerves.^{22,23} Future efforts should explore the benefits of these blocks for more subtypes of awake craniotomies, such as deep brain stimulation and stereotactic radiosurgery.

The Modern “Scalp Block”: Technical Description

Six nerves can be blocked during “scalp block.” Here is a summary of the modern technique for performing each block.^{17,19,20,23,24}

Supraorbital Nerve

The supraorbital nerve can be blocked as it emerges from the orbit. The supraorbital notch is palpated by the finger, and the needle is inserted along the upper orbital margin, perpendicular to the skin, approximately 1 cm medial to the supraorbital foramen.

Supratrochlear Nerve

Emerging from the superiomedial angle of the orbit, and running up on the forehead parallel to the supraorbital nerve a finger’s breadth medial to it, the supratrochlear nerve can either be blocked as it emerges above the eyebrow or can be involved by a medial extension of the supraorbital block.

Auriculotemporal Nerve

The auriculotemporal nerve can be blocked by infiltration over zygomatic process, with an injection 1 to 1.5 cm anterior to the ear at the level of the tragus. The superficial temporal artery is anterior to the auriculotemporal nerve at the level of the tragus, and should always be palpated and its course identified before blockade.

Zygomaticotemporal Nerve

The zygomaticotemporal nerve is blocked by infiltration from the supraorbital margin to the posterior part of the zygomatic arch. Arising midway between auriculotemporal and supraorbital nerves where it emerges above the zygoma, the zygomaticotemporal nerve ramifies as it pierces temporalis fascia. Both deep and superficial injection plains are thus recommended.

Greater Occipital Nerve

The greater occipital nerve can be blocked by infiltration approximately halfway between the occipital protuberance and the mastoid process, 2.5 cm lateral to the nuchal median line. The best landmark is to palpate

the occipital artery, and inject medially after careful aspiration. This should avoid potential intra-arterial injection.

Lesser Occipital Nerve

The lesser occipital nerve can be blocked by infiltration along the superior nuchal line, 2.5 cm lateral to the greater occipital nerve block.

The volume of local anesthesia administered at each site can vary from 2 to 5 mL of 0.25% to 0.5% bupivacaine^{17,19,20,23,24}; Schematics and photographs of local anesthetic injections for 3 of the 6 major nerves blocked for craniotomies (supraorbital, greater occipital, and lesser occipital nerves) can be found in Figures 2 and 3. Table 1 summarizes the 6 nerves used for “scalp block” together with their origins, and separates the nerves to be blocked for anterior or posterior craniotomies. Of note, the “scalp block” has been reported to include an additional nerve, the great auricular nerve. The great auricular nerve is the largest of the ascending branches of the cervical plexus. It arises from the C2 and C3, and its posterior branches supply the skin of the mastoid process and part of the back of the auricula.¹ The postauricular branches of the great auricular nerves may be blocked with an injection between the skin and bone, 1.5 cm posterior to the ear at the level of the tragus.¹⁹

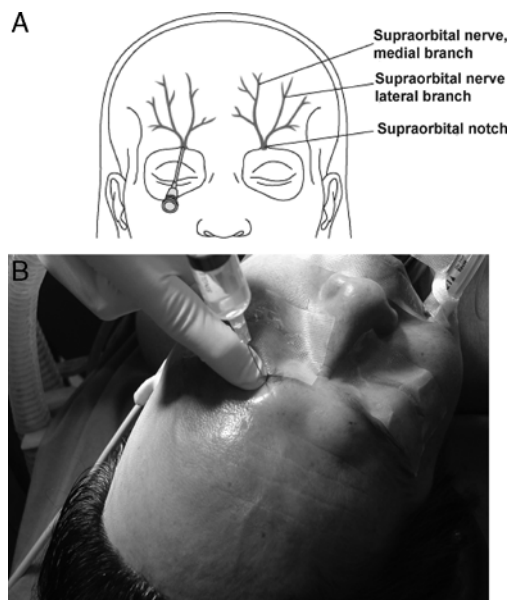


FIGURE 2. Supraorbital nerve block. A, Diagram of supraorbital nerve block. Source: Morgan GE, Mikhail MS, Murray MJ: *Clinical Anesthesiology*, 4th edition: <http://accessmedicine.com>. Authorization obtained from McGraw-Hill companies to use this copyrighted material. B, Photograph of supraorbital nerve block performed on a patient undergoing craniotomy.

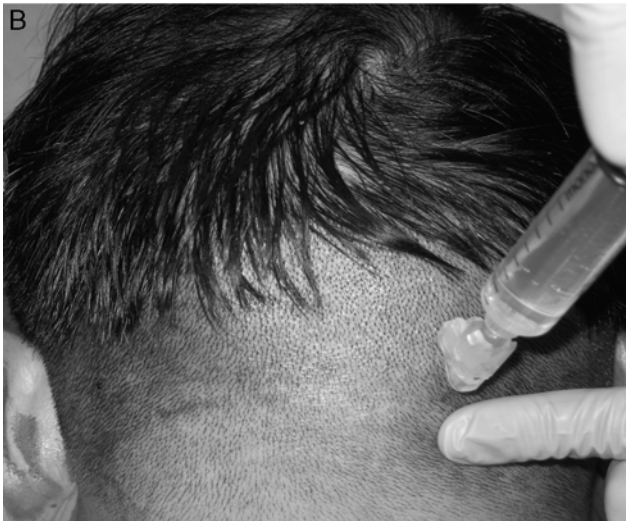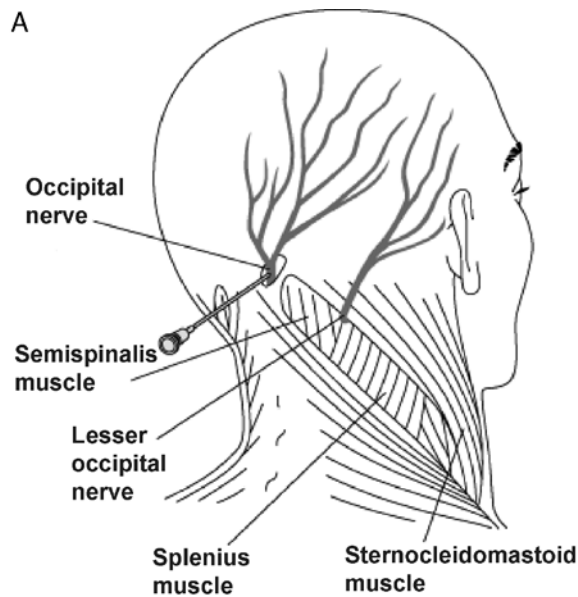


FIGURE 3. Occipital nerves block. A, This diagram illustrates greater occipital nerve (termed “occipital nerve”) block, and also displays landmarks for lesser occipital nerve block. Source: Morgan GE, Mikhail MS, Murray MJ: *Clinical Anesthesiology*, 4th edition: <http://accessmedicine.com>. Authorization obtained from McGraw-Hill companies to use this copyrighted material. B, Photograph of greater occipital nerve block performed on a patient undergoing craniotomy.

Complications/Contraindications

Although uncommon, complications have been reported with blocks performed on the scalp. When bupivacaine is mixed with a vasoconstrictor, inadvertent intravascular injection or systemic absorption could cause hypertension.⁹ Extra caution should be taken when adding epinephrine to the local anesthetic injection, but when used appropriately, the combination of bupivacaine with epinephrine for scalp infiltration is not associated

with significant changes in mean arterial pressure or heart rate. Local anesthetic injection has been associated with acute rises in anesthetic plasma concentration, which may predispose to local anesthetic toxicity.²⁵ The use of epinephrine may thus especially be recommended in well-vascularized areas such as the scalp to maximize block duration and minimize acute rises in anesthetic plasma concentration.

Clinical vigilance should be followed during the first 15 minutes after injection of local anesthetics for awake craniotomies, with rapid rises in anesthetic concentrations, although these rises are similar to the ones observed with other local blocks.^{26–28} Studies have suggested that some anesthetics are safer than the others. Indeed depression of cardiac conductivity and contractility appeared at lower dosage and plasma concentrations in healthy patients injected with bupivacaine when compared with ropivacaine-injected patients.²⁵ Recent studies have shown ropivacaine and levobupivacaine to have less cardiac and neurotoxicity than bupivacaine in rats.²⁹ This has led to some groups recommending the preferential use of ropivacaine and levobupivacaine over bupivacaine for awake craniotomies.²² However, bupivacaine remains the most widely used local anesthetic in practice, and Archer et al³⁰ remain the only authors to report clinical cases related to local anesthetic toxicity during awake craniotomy. In this study, the conclusions of toxicity are questionable: 2 patients undergoing craniotomy for intractable seizures suffered convulsions temporally related to local anesthetic infiltrations.³⁰ Hypotensive episodes after scalp infiltration have been reported and caution must be employed with close blood pressure monitoring.³¹

Okuda et al³² reported inadvertent injection of mepivacaine into the subarachnoid space during an occipital nerve block. A right lesser occipital nerve block with mepivacaine (without epinephrine) was performed to alleviate symptoms of occipital headaches in a 63-year-old man. During this block, the patient suddenly complained of generalized discomfort and nausea, losing consciousness, and having a shallow respiration. Oxygen saturation remained about 97% despite hypoventilation, and the patient’s blood pressure and heart rate remained steady. The patient was closely observed for 2 hours, after which he was fully awake without neurologic sequelae. After recovery, the patient stated that he had undergone a retromastoid craniotomy for microvascular decompression years earlier, leaving an occipital bone defect in his right retromastoid area.³² Occipital nerve blocks are carefully performed after palpation of the skull and relatively contraindicated when a bone defect is present or suspected.

Complications reported in other head and neck nerve blocks, such as inadvertent intra-arterial injection with retrograde flow into the internal carotid artery and cerebral circulation with subsequent respiratory arrest,³³ or brainstem anesthesia causing apnea and loss of consciousness,³⁴ have not been reported with “scalp blocks.” The proximity of the facial nerve to nerves

TABLE 1. Nerves to be Blocked for Craniotomy

Nerves to be Blocked	Branch	Anterior Craniotomy	Posterior Craniotomy
Supraorbital	Ophthalmic branch of TG n	Yes	No
Supratrochlear	Ophthalmic branch of TG n	Yes	No
Auriculotemporal	Mandibular branch of TG n	Yes	No
Zygomatocotemporal	Maxillary branch of TG n	Yes	Yes
Greater occipital	Posterior ramus of C2	No	Yes
Lesser occipital	Ventral rami of C2, C3	No	Yes

The table displays the 6 nerves blocked for craniotomy, their origins, and whether they should be blocked for anterior or posterior craniotomies.

C indicates cervical nerve; n, nerve; TG, trigeminal.

injected during “scalp block” makes facial nerve paralysis a potential complication, although no cases have been reported in the literature. A careful identification of the discussed anatomic landmarks will help prevent injection into this nerve. Infections should be a concern with any procedure, but none have yet been reported after scalp nerve block. Of note, a relative contraindication to performing “scalp block” involves patients with known bleeding disorders, with potential hematoma as an issue. Any coagulopathy should be corrected by the neurosurgical team before surgery. “Scalp block” thus appears as a safe technique with rare complications reported in the literature.

NEW APPLICATIONS AND FUTURE PROSPECTS

“Scalp Block” for Postoperative Pain

For decades, although postoperative pain was known to be a significant problem in craniotomy patients, rigorously designed studies were lacking.³⁵ More recent prospective studies have shown that after craniotomy, the majority of patients experience pain. Quiney et al³⁶ have reported severe or moderate pain (poorly controlled with codeine alone) in the first 24 hours after craniotomy in the majority of 53 patients studied. Similarly, De Benedittis et al³⁷ studied 37 patients after neurosurgery, and found that two-third of the patients experienced moderate-to-severe pain in the first 48 hours after surgery. In their study, the pain was predominantly superficial in 86% of patients, suggesting somatic rather than visceral origin, with possible involvement of pericranial muscles and soft tissues.

Scalp infiltration with local anesthetic has been studied as a way of decreasing postoperative pain. In a randomized double-blind study, Bloomfield et al³⁸ infiltrated the scalp with 0.25% bupivacaine or saline coupled with epinephrine both before incision and after scalp closure. Although their study was limited to 1 hour in the immediate postoperative period, it showed that wound infiltration with local anesthetics decreases pain scores on admission to the postanesthesia care unit for up to 1 hour.³⁸ A few years later, a prospective double-blind randomized and placebo-controlled trial showed that 0.25% bupivacaine preincision scalp infiltration did not have any significant effect on postcraniotomy pain

and analgesic requirement, although it did delay the requirement of the first analgesic dose.³⁹

The effects of “scalp block” on postoperative pain have also recently been explored. Nguyen et al⁴⁰ performed a prospective double-blinded randomized study in 30 patients receiving a block with 0.75% ropivacaine or saline. The “scalp block” involved blockade of the supraorbital, supratrochlear, auriculotemporal, great auricular, and greater and lesser occipital nerves as described by Pinosky et al¹⁹ after skin closure and before awakening. Pain was assessed starting at 4 and up to 48 hours postoperatively. The average pain scores in the ropivacaine group was significantly lower when compared with the saline group for up to 24 hours, and the analgesic effect seemed to persist for at least 48 hours postoperatively.

A later double-blind randomized study assessed the efficacy of “scalp block” using 0.5% bupivacaine with epinephrine for postoperative pain relief in 40 patients after craniotomy. “Scalp block” was performed as described by Pinosky et al,¹⁹ postoperatively after skin closure. Pain was assessed between 30 minutes and 12 hours postoperatively. Bala et al⁴¹ found that bupivacaine injection with epinephrine was effective in decreasing postoperative pain. They reported that 60% of patients receiving saline injection experienced moderate to severe pain some time during the first 12 postoperative hours in comparison to 25% patients who received bupivacaine “scalp block”. In addition, the median pain scores were significantly lower up to 6 hours postoperatively in patients who had received bupivacaine nerve blockade. The duration of pain relief in this study corresponded with the expected duration of action of bupivacaine with epinephrine. A recent prospective randomized controlled double-blinded study has suggested that the postoperative analgesia offered by morphine and scalp blocks are equivalent, although the incidence of nausea and vomiting was slightly more frequent in the morphine group.⁴² Thus, even though “scalp block” seems to reduce postoperative pain in patients after craniotomy, more large studies are needed before the technique is generally accepted and used.

“Scalp Block” in Pediatric Patients

Data to corroborate the greater use of regional anesthesia techniques for most pediatric surgical procedures

is lacking. However, “scalp blocks” have successfully been reported for use in children for several years. As demonstrated for adults, pain has been shown to increase morbidity in the postoperative period in neonates and children,^{43,44} and pain management in children has been an ongoing effort.⁴⁵ Recently, great auricular nerve blocks with 0.25% bupivacaine with epinephrine has successfully been used in children undergoing tympanomastoid surgery with advantages including avoidance of the adverse side effects of opioids, and targeting the pain relief to the area of the lesion.^{46,47} Two recent reviews have also explored the anatomy and innervation necessary to identify the appropriate nerves in children to perform scalp nerve blockade, including the supra-orbital and supratrochlear nerves.^{48,49} This could lead to future applications of “scalp block” in children, such as pediatric patients undergoing craniostomy repair or awake procedures for deep brain stimulations for dystonia.⁵⁰

“Scalp Block” and Chronic Pain Management

Recent investigations have also focused on the role of local anesthetics in the long-term management of pain after neurosurgery. Batoz et al⁵¹ studied the effect of postsurgical ropivacaine scalp infiltration on acute and persistent postoperative pain in a prospective single-blinded study. Patients undergoing intracranial tumor resection were randomly included in Group I (infiltration of ropivacaine) or C (control, no infiltration). Although postoperative analgesia with nalbuphine was similar between the 2 groups during the first 24 postoperative hours, pain scores were significantly higher in Group C than in Group I during this time period. Two months after the surgery, persistent pain was significantly lower in Group I (8%) than Group C (56%).⁵¹ Perioperative local anesthetic infiltration may thus not only provide relief for acute pain but also potentially decrease persistent postoperative pain. Although encouraging, these results should be followed by larger double-blind randomized controlled studies investigating the effects of local anesthetic infiltration and “scalp block” on long-term postoperative pain.

New ways of providing longer postoperative pain control are also under investigation in animal models. A new formulation of bupivacaine loaded in an injectable fatty acid-based biodegradable polymer has thus been studied for producing motor and sensory block when injected near the sciatic nerve of mice.⁵² Seventy percent of the incorporated drug was released during 1 week in vitro, whereas single injection of 10% bupivacaine in the polymer caused motor and sensory blocks that lasted 30 hours in vivo in mice.⁵² Microscopic examination of the injection sites revealed only mild infiltration in 3 of the 8 examined tissues with no pathologic findings for internal organs: the polymer thus seemed as a safe carrier for prolonged activity of bupivacaine.⁵² Newer type of polymers have recently been reported to provide slow release of effective doses of the incorporated locally injected bupivacaine with prolonged motor and sensory

blocks of mice sciatic nerves for up to 48 hours.⁵³ Future investigations looking at the use of these long-lasting polymer-loaded anesthetics in patients could lead to new advances in approach to postoperative pain. Combining these techniques with the use of neurolytics^{54,55} or the more invasive peripheral nerve stimulation of implantable devices⁵⁶ based on the patient’s pain-control requirements could allow for optimal pain management. “Scalp block” has also been used for pain management outside of surgery. This is particularly true for occipital nerve block, which is an effective treatment for cluster headaches, cervicogenic headaches, and occipital neuralgia, and although a double-blinded randomized placebo-controlled clinical trial is lacking, multiple studies have reported favorable results for migraines.⁵⁷

CONCLUSIONS

The classic scalp infiltration techniques introduced a century ago has evolved into a modern precise scalp nerve blockade. The “scalp block” technique is safe and reproducibly successful in maintaining hemodynamic stability. Its use is being extended to children and appears to be of great use in postoperative pain management. The technique has a steep learning curve and its practice will undoubtedly help the anesthesiologist in the perioperative management of patients undergoing craniotomy. Further improvements and applications of “scalp blocks” are growing areas of research, and the next decade will likely see a wider use of this technique.

ACKNOWLEDGMENT

The authors would like to thank Dr. Dung Q. Tran of Georgetown University for his dedication to the teaching of the “scalp block” technique.

REFERENCES

1. Gray H. *Anatomy of the Human Body*. Philadelphia: Lea & Febiger; 1918.
2. Anderson JE. *Grant’s Atlas of Anatomy*. Baltimore: Williams and Wilkins Co; 1978.
3. Ward JB. Greater occipital nerve block. *Semin Neurol*. 2003;23:59–62.
4. Halsted WS. Practical comments on the use and abuse of cocaine. *New York Med J*. 1885;42:294–295.
5. Corning JL. On the prolongation of the anaesthetic effects of the hydrochlorate of cocaine when subcutaneously injected. An experimental study. *New York Med J*. 1885;42:317–319.
6. Cushing H. I. On the avoidance of shock in major amputations by cocainization of large nerve-trunks preliminary to their division. with observations on blood-pressure changes in surgical cases. *Ann Surg*. 1902;36:321–345.
7. Lassen NA, Christensen MS. Physiology of cerebral blood flow. *Br J Anaesth*. 1976;48:719–734.
8. Braun H. Über die anwendung der suprareninamie bei operationen am schädel und der wirbelsäule. *Zentralblatt für Chirurgie*. 1910;107:561–569.
9. Christensen KN, Jensen JK, Sogaard I. Blood pressure response to administration of local anaesthetics with noradrenaline in craniotomies. *Acta Neurochir (Wien)*. 1980;51:157–160.
10. Penfield W. Combined regional and general anesthesia for craniotomy and cortical exploration. Part I. neurosurgical considerations. *Int Anesthesiol Clin*. 1986;24:1–11.

11. Hillman DR, Rung GW, Thompson WR, et al. The effect of bupivacaine scalp infiltration on the hemodynamic response to craniotomy under general anesthesia. *Anesthesiology*. 1987;67:1001–1003.
12. Hartley EJ, Bissonnette B, St-Louis P, et al. Scalp infiltration with bupivacaine in pediatric brain surgery. *Anesth Analg*. 1991;73:29–32.
13. Colley PS, Heavner JE. Blood levels of bupivacaine after injection into the scalp with and without epinephrine. *Anesthesiology*. 1981;54:81–84.
14. Shiao JM, Chen TY, Tseng CC, et al. Combination of bupivacaine scalp circuit infiltration with general anesthesia to control the hemodynamic response in craniotomy patients. *Acta Anaesthesiol Sin*. 1998;36:215–220.
15. Agarwal A, Sinha PK, Pandey CM, et al. Effect of a subanesthetic dose of intravenous ketamine and/or local anesthetic infiltration on hemodynamic responses to skull-pin placement: a prospective, placebo-controlled, randomized, double-blind study. *J Neurosurg Anesthesiol*. 2001;13:189–194.
16. Bithal PK, Pandia MP, Chouhan RS, et al. Hemodynamic and bispectral index changes following skull pin attachment with and without local anesthetic infiltration of the scalp. *J Anesth*. 2007;21:442–444.
17. Girvin JP. Neurosurgical considerations and general methods for craniotomy under local anesthesia. *Int Anesthesiol Clin*. 1986;24:89–114.
18. Rubial M, Castells MV, Gargallo MC, et al. Regional blockage for arterial blood pressure control during placement of head holder in neurosurgery. *Rev Esp Anesthesiol Reanim*. 1992;39:282–284.
19. Pinosky ML, Fishman RL, Reeves ST, et al. The effect of bupivacaine skull block on the hemodynamic response to craniotomy. *Anesth Analg*. 1996;83:1256–1261.
20. Lee EJ, Lee MY, Shyr MH, et al. Adjuvant bupivacaine scalp block facilitates stabilization of hemodynamics in patients undergoing craniotomy with general anesthesia: a preliminary report. *J Clin Anesth*. 2006;18:490–494.
21. Olsen KS, Pedersen CB, Madsen JB, et al. Vasoactive modulators during and after craniotomy: relation to postoperative hypertension. *J Neurosurg Anesthesiol*. 2002;14:171–179.
22. Costello TG, Cormack JR. Anaesthesia for awake craniotomy: a modern approach. *J Clin Neurosci*. 2004;11:16–19.
23. Piccioni F, Fanzio M. Management of anesthesia in awake craniotomy. *Minerva Anesthesiol*. 2008;74:393–408.
24. Mehio AK, Shah SK. Alleviating head and neck pain. *Otolaryngol Clin North Am*. 2009;42:143–159.
25. Scott DB, Lee A, Fagan D, et al. Acute toxicity of ropivacaine compared with that of bupivacaine. *Anesth Analg*. 1989;69:563–569.
26. Audu PB, Wilkerson C, Bartkowski R, et al. Plasma ropivacaine levels during awake intracranial surgery. *J Neurosurg Anesthesiol*. 2005;17:153–155.
27. Costello TG, Cormack JR, Hoy C, et al. Plasma ropivacaine levels following scalp block for awake craniotomy. *J Neurosurg Anesthesiol*. 2004;16:147–150.
28. Costello TG, Cormack JR, Mather LE, et al. Plasma levobupivacaine concentrations following scalp block in patients undergoing awake craniotomy. *Br J Anaesth*. 2005;94:848–851.
29. Ohmura S, Kawada M, Ohta T, et al. Systemic toxicity and resuscitation in bupivacaine-, levobupivacaine-, or ropivacaine-infused rats. *Anesth Analg*. 2001;93:743–748.
30. Archer DP, McKenna JM, Morin L, et al. Conscious-sedation analgesia during craniotomy for intractable epilepsy: a review of 354 consecutive cases. *Can J Anaesth*. 1988;35:338–344.
31. Yang JJ, Liu J, Duan ML, et al. Lighter general anesthesia causes less decrease in arterial pressure induced by epinephrine scalp infiltration during neurosurgery. *J Neurosurg Anesthesiol*. 2007;19:263–267.
32. Okuda Y, Matsumoto T, Shinohara M, et al. Sudden unconsciousness during a lesser occipital nerve block in a patient with the occipital bone defect. *Eur J Anaesthesiol*. 2001;18:829–832.
33. Beltranena HP, Vega MJ, Garcia JJ, et al. Complications of retrobulbar marcaine injection. *J Clin Neuroophthalmol*. 1982;2:159–161.
34. Brookshire GL, Gleitsmann KY, Schenk EC. Life-threatening complication of retrobulbar block. a hypothesis. *Ophthalmology*. 1986;93:1476–1478.
35. Atkinson RS, Rushmann GB, Davies NJH, eds. *Surgical Operations and Choice of Anesthetic, Lee's Synopsis of Anesthesia*. 11th ed. Oxford: Butterworth-Heinemann Publishers; 1993:444–602.
36. Quiney N, Cooper R, Stoneham M, et al. Pain after craniotomy. A time for reappraisal? *Br J Neurosurg*. 1996;10:295–299.
37. De Benedittis G, Lorenzetti A, Migliore M, et al. Postoperative pain in neurosurgery: a pilot study in brain surgery. *Neurosurgery*. 1996;38:466–469; discussion 469–470.
38. Bloomfield EL, Schubert A, Secic M, et al. The influence of scalp infiltration with bupivacaine on hemodynamics and postoperative pain in adult patients undergoing craniotomy. *Anesth Analg*. 1998;87:579–582.
39. Biswas BK, Bithal PK. Preincision 0.25% bupivacaine scalp infiltration and postcraniotomy pain: a randomized double-blind, placebo-controlled study. *J Neurosurg Anesthesiol*. 2003;15:234–239.
40. Nguyen A, Girard F, Boudreault D, et al. Scalp nerve blocks decrease the severity of pain after craniotomy. *Anesth Analg*. 2001;93:1272–1276.
41. Bala I, Gupta B, Bhardwaj N, et al. Effect of scalp block on postoperative pain relief in craniotomy patients. *Anaesth Intensive Care*. 2006;34:224–227.
42. Ayoub C, Girard F, Boudreault D, et al. A comparison between scalp nerve block and morphine for transitional analgesia after remifentanyl-based anesthesia in neurosurgery. *Anesth Analg*. 2006;103:1237–1240.
43. Anand KJ. The stress response to surgical trauma: from physiological basis to therapeutic implications. *Prog Food Nutr Sci*. 1986;10:67–132.
44. Anand KJ, Hickey PR. Pain and its effects in the human neonate and fetus. *N Engl J Med*. 1987;317:1321–1329.
45. McGrath PJ, Beyer J, Cleeland C, et al. American academy of pediatrics report of the subcommittee on assessment and methodologic issues in the management of pain in childhood cancer. *Pediatrics*. 1990;86:814–817.
46. Suresh S, Barcelona SL, Young NM, et al. Does a preemptive block of the great auricular nerve improve postoperative analgesia in children undergoing tympanomastoid surgery? *Anesth Analg*. 2004;98:330–333.
47. Suresh S, Barcelona SL, Young NM, et al. Postoperative pain relief in children undergoing tympanomastoid surgery: is a regional block better than opioids? *Anesth Analg*. 2002;94: 859–862.
48. Suresh S, Wagner AM. Scalp excisions: getting “ahead” of pain. *Pediatr Dermatol*. 2001;18:74–76.
49. Suresh S, Voronov P. Head and neck blocks in children: an anatomical and procedural review. *Paediatr Anaesth*. 2006;16: 910–918.
50. Adam OR, Jankovic J. Treatment of dystonia. *Parkinsonism Relat Disord* 2007;13(suppl 3): S362–S368.
51. Batoz H, Verdonck O, Pellerin C, et al. The analgesic properties of scalp infiltrations with ropivacaine after intracranial tumoral resection. *Anesth Analg*. 2009;109:240–244.
52. Shikanov A, Domb AJ, Weiniger CF. Long acting local anesthetic-polymer formulation to prolong the effect of analgesia. *J Control Release*. 2007;117:97–103.
53. Sokolsky-Papkov M, Golovanevski L, Domb AJ, et al. Prolonged local anesthetic action through slow release from poly (lactic acid co castor oil). *Pharm Res*. 2009;26:32–39.
54. Abram SE. Neural blockade for neuropathic pain. *Clin J Pain*. 2000;16:S56–S61.
55. Wilkinson HA. Trigeminal nerve peripheral branch phenol/glycerol injections for tic douloureux. *J Neurosurg*. 1999;90:828–832.
56. Slavin KV. Peripheral nerve stimulation for neuropathic pain. *Neurotherapeutics*. 2008;5:100–106.
57. Tobin J, Flitman S. Occipital nerve blocks: when and what to inject? *Headache*. 2009.