

Necrotizing fasciitis of lower limb: Is it ischemia or *E. coli* infection?

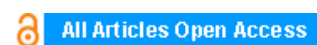
Takahiro Matsuo, Hiroki Mochizuki, Atsushi Mizuno, Keiichi Furukawa, Yutaro Nishi, Koichiro Niwa

ABSTRACT

Introduction: Necrotizing fasciitis is a life-threatening soft-tissue infection characterized by a fulminant course and high mortality. Diagnosis of necrotizing fasciitis is often difficult, because nascent NF often appears deceptively benign and lack specific diagnostic clues. In addition, the manifestations of NF are similar to those of acute limb ischemia. Here, we introduce the case of necrotizing fasciitis accompanied with acute limb ischemia on left lower leg.

Case Report: A 71-year-old male with a history of stomach cancer complained of vomiting and dyspnea one day before admission to our hospital. Two days after admission, his left lower extremity whitened and became edematous. Contrast-enhanced computed tomography revealed severe stenosis of the left common iliac artery. We were unable to rule out acute limb ischemia and performed endovascular revascularization. However, the leg did not improve and major amputation was performed. The leg pathology was suggestive of necrotizing fasciitis.

Conclusion: We should not forget the possibility that any systemic infection can result in necrotizing fasciitis even if the patients have high risk of acute limb ischemia.



International Journal of Case Reports and Images (IJCRI)



International Journal of Case Reports and Images (IJCRI) is an international, peer reviewed, monthly, open access, online journal, publishing high-quality, articles in all areas of basic medical sciences and clinical specialties.

Aim of IJCRI is to encourage the publication of new information by providing a platform for reporting of unique, unusual and rare cases which enhance understanding of disease process, its diagnosis, management and clinico-pathologic correlations.

IJCRI publishes Review Articles, Case Series, Case Reports, Case in Images, Clinical Images and Letters to Editor.

Website: www.ijcasereportsandimages.com

Necrotizing fasciitis of lower limb: Is it ischemia or *E. coli* infection?

Takahiro Matsuo, Hiroki Mochizuki, Atsushi Mizuno, Keiichi Furukawa, Yutaro Nishi, Koichiro Niwa

ABSTRACT

Introduction: Necrotizing fasciitis (NF) is a life-threatening soft-tissue infection characterized by a fulminant course and high mortality. Diagnosis of necrotizing fasciitis is often difficult, because nascent necrotizing fasciitis often appears deceptively benign and lack specific diagnostic clues. In addition, the manifestations of NF are similar to those of acute limb ischemia. Here, we introduce the case of necrotizing fasciitis accompanied with acute limb ischemia on left lower leg. **Case Report:** A 71-year-old male with a history of stomach cancer complained of vomiting and dyspnea one day before admission to our hospital. Two days after admission, his left lower extremity whitened and became edematous. Contrast-enhanced computed tomography revealed severe stenosis of the left common iliac artery. We were unable to rule out acute limb ischemia and performed endovascular revascularization. However, the leg did not improve and major amputation was performed. The leg pathology was suggestive of necrotizing fasciitis. **Conclusion:** We should not forget the possibility that any systemic infection can result

in necrotizing fasciitis even if the patients have high risk of acute limb ischemia.

Keywords: Acute limb ischemia, *E. coli*, *Escherichia coli*, Necrotizing fasciitis, Pneumonia

How to cite this article

Matsuo T, Mochizuki H, Mizuno A, Furukawa K, Nishi Y, Niwa K. Necrotizing fasciitis of lower limb: Is it ischemia or *E. coli* infection? Int J Case Rep Images 2016;7(11):701–705.

Article ID: Z01201611CR10709SS

doi:10.5348/ijcri-2016121-CR-10709

INTRODUCTION

Necrotizing fasciitis (NF) is infrequent but highly lethal infection and is associated with systemic toxicity and a mortality rate of 30–60% [1, 2]. It affects the superficial fascia and subcutaneous tissue. Establishing the diagnosis of NF is difficult because nascent NF often appears deceptively benign and lack specific diagnostic clues [3]. Delay of diagnosis leads to delayed surgical debridement, which leads to higher mortality [1]. The manifestations of NF are similar to those of acute limb ischemia. Here, we introduce the case of necrotizing fasciitis accompanied with acute limb ischemia on left lower leg.

CASE REPORT

A 71-year-old male with a history of hypertension and stomach cancer complained of vomiting and dyspnea

Takahiro Matsuo², Hiroki Mochizuki¹, Atsushi Mizuno, Keiichi Furukawa², Yutaro Nishi¹, Koichiro Niwa¹

Affiliations: ¹Department of Cardiology, St. Luke's International Hospital, Tokyo, Japan; ²Department of Infectious Diseases, St. Luke's International Hospital, Tokyo, Japan.

Corresponding Author: Takahiro Matsuo, MD, Department of Infectious Diseases, St. Luke's International Hospital, Tokyo, Japan; 9-1, Akashi-cho, Chuo-ku, Tokyo, Japan, 104-8560; E-mail: tmatsuo@luke.ac.jp

Received: 30 May 2016

Accepted: 22 July 2016

Published: 01 November 2016

one day before admission to hospital. On admission, he was unconscious, with a Glasgow coma score of 3. Clinical examination revealed that the patient's state was critical, with a temperature of 39.3°C, blood pressure 61/39, heart rate 144/min, respiratory rate 43/min, and oxygen saturation 94% on a non-rebreather mask at 15 L/min oxygen. The patient's left-sided respiratory sounds were decreased, with coarse crackles. The bowel sounds were normal and the abdomen was soft and non-tender. We intubated him in the emergency room because the patient was in shock with impaired consciousness. Laboratory findings revealed an elevated white blood cell (WBC) count of 1200/ μ L, C-reactive protein 27.1 mg/dL, creatinine kinase (CK) 2405 U/L, and creatinine 1.62 mg/dL. Arterial blood gas analysis revealed significant lactic acidosis (Table 1). Computed tomography (CT) scan revealed consolidation in the superior lobe of the left lung. Immunochromatographic membrane tests using urine sample for rapid detection of *Streptococcus pneumoniae* antigen and *Legionella* antigen (BinaxNOW *S. pneumoniae* and BinaxNOW *Legionella*; Inverness Medical Innovations), were performed but gave negative results. Gram staining of the sputum revealed Gram-negative rods with neutrophils. The patient was diagnosed with pulmonary insufficiency associated with pneumonia and septic shock and admitted to the intensive care unit (Figure 1). We initiated therapy with vasopressors and broad-spectrum antibiotics (piperacillin/tazobactam and ciprofloxacin). On the same day, the patient's blood culture became positive for bacteremia with a Gram-negative rod. Therefore, direct hemoperfusion with a polymyxin B-immobilized fiber column was initiated.

On day-4, the skin of the left lower leg abruptly turned white and purpura developed. Doppler ultrasound was unable to detect blood flow in the left dorsalis pedis

artery, and a CT scan showed severe stenosis of the left common iliac and femoral arteries. The patient's CK level had risen to 60,000 IU/L. The clinical manifestations, laboratory findings, and results of radiological imaging were suggestive of acute limb ischemia. We performed angiography, which revealed significant stenosis of the left common iliac artery (Figure 2); this finding was compatible with acute limb ischemia. We discussed whether or not we should perform revascularization because we did not know the precise time of onset of the limb ischemia. We reached the decision to insert a self-expanding stent into left common iliac artery and to perform a counter-incision (Figure 3) because the intracompartmental pressure of the left lower extremity was 70 mmHg. The patient's scrotum had also become swollen and erythematous on day-4, and its color had changed to purple on day-5 (Figure 4). We suspected Fournier gangrene and consulted urologists accordingly. Puncture of the scrotum revealed a serous, yellow, clear fluid, which was compatible with hydrocele testis, not Fournier gangrene. Despite the counter-incision, eight days after the patient's admission the color of his left lower extremity had not improved and the CK had risen rapidly further to 1,500,000 U/L. We considered other differential diagnosis including purpura fulminans caused by *Streptococcus pneumoniae*, *Streptococcus pyogenes*, *Vibrio vulnificus*, and *Neisseria meningitidis*. We therefore performed major amputation above the hip joint. The patient's general condition, including his vital signs, disseminated intravascular coagulation score, and oxygenation, improved temporarily after this intervention.

Unfortunately, two weeks later the patient developed candidemia as a complication of infection from his central venous catheter. Despite the administration of liposomal

Table 1: Laboratory Findings.

Complete blood count		Blood chemistry		Arterial blood gas	
White blood cells	1200 / μ L	BUN	37.1 g/dL	pH	7.285
	(Seg 45%, Stab 1.0 %)	Cre	1.62 g/dL	pCO ₂	33.0 mmHg
Hemoglobin	14.9 g/dL	eGFR	33.8 ml/min	pO ₂	85.1 mmHg
Hematocrit	43.20%	LDH	241 IU/L	HCO ₃ ⁻	15.2 mmol/L
Platelet	15.7×10 ⁴ / μ L	AST	57 IU/L	FiO ₂	0.6
		ALT	27 IU/L	Lac	5.0 mg/dL
		CK	2405 U/L		
		CK-MB	20 U/L		
		CRP	27.1 mg/dL		
		PCT	72.14 ng/ml		

Abbreviations: BUN Blood urea nitrogen, Cre creatinine, eGFR Estimated glomerular filtration rate, LDH Lactate dehydrogenase, AST Aspartate aminotransferase, ALT Alanine aminotransferase, CK Creatine kinase, CK-MB Creatine kinase muscle and brain, CRP C-reactive protein, PCT Procalcitonin, PaCO₂ Arterial carbon dioxide tensions, PaO₂ Arterial oxygen tensions, HCO₃⁻ Bicarbonate, FiO₂ Fraction of inspiratory oxygen, Lac Lactate

amphotericin-B to treat the candidemia, the patient died on hospitalization day-38 from multiple organ failure.

Pathology

Pathological examination of the amputated leg revealed muscle edema. Infiltration of WBCs

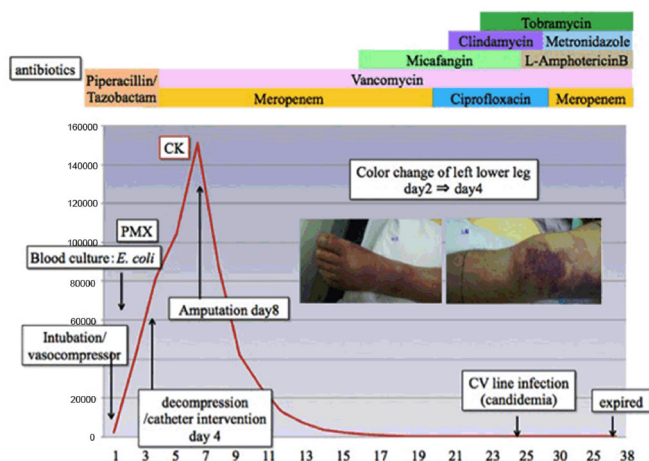


Figure 1: Treatment course of the patient. On day 4, we performed catheter intervention and decompression for suspected acute occlusion and compartment syndrome of the left thigh. On day-8, surgical debridement was done for necrotizing fasciitis. Despite intensive care for the treatment of complications followed by NF, the patient died on day 38 from multiple organ failure.

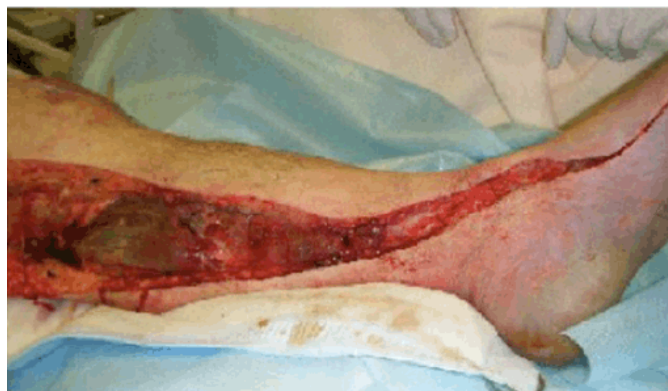

Figure 3: We reached a decision to insert a self-expanding stent into the left common iliac artery and to perform a counter-incision Because the intracompartmental pressure of the left lower extremity was 70 mmHg.

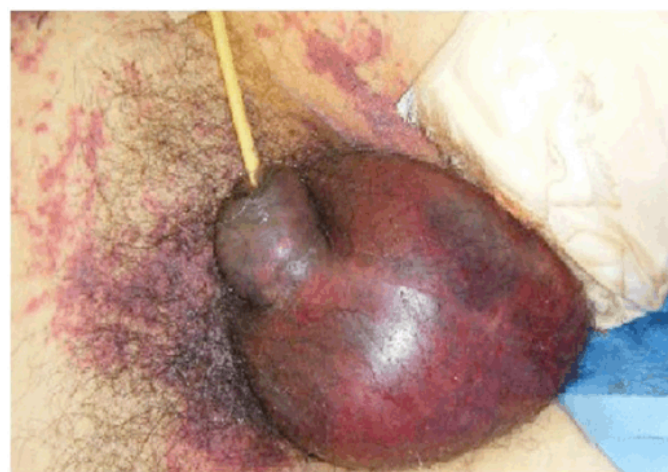

Figure 4: On day-4, the patient's scrotum was swollen and erythematous. By day- 5 it had become purple.

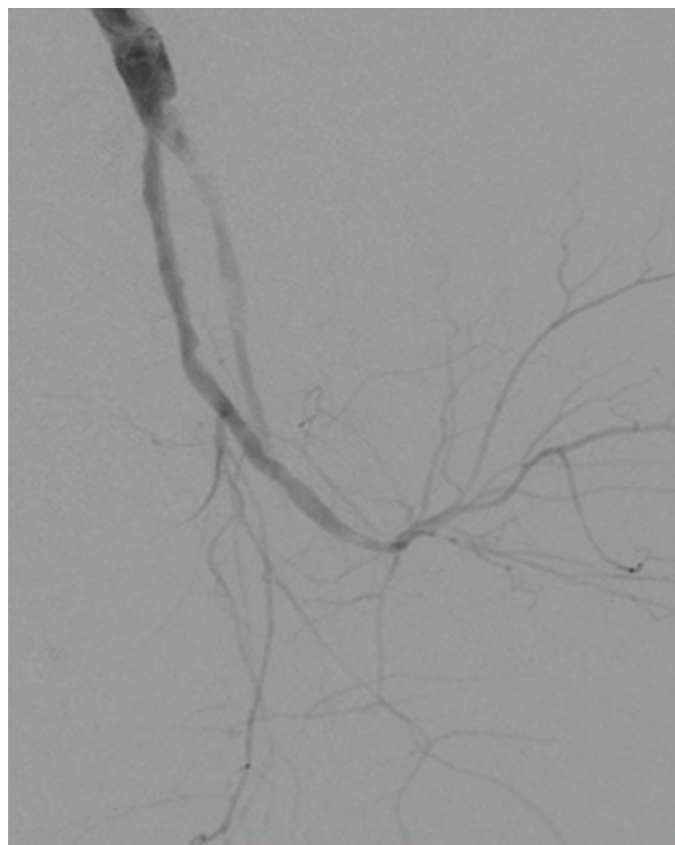


Figure 2: Angiography revealed marked stenosis of the left common iliac artery.

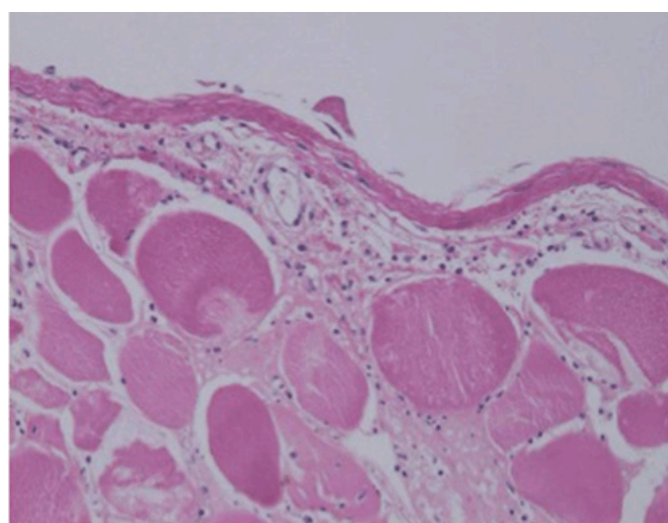


Figure 5: Histopathological examination revealed muscle edema and infiltration of white blood cells around the fascia and fatty tissue. The muscle fibers had degenerated and were necrotic.

(neutrophils, lymphocytes, histiocytes) was found around the fascia and fatty tissue. The striated muscle of the lower limb was not stained and showed eosinophilic changes in the sarcoplasmic reticulum. The muscle fibers were defiberized each other and were necrotic (Figure 5). This necrosis was compatible with acute compartment syndrome. The presence of inflammatory cell infiltrates around the fascia was indicative of necrotizing fasciitis (NF).

DISCUSSION

This patient developed lower extremity NF accompanied by severe sepsis and acute pneumonia caused by *E. coli*. Diagnosis of NF was difficult in this case, because the leg manifestations were similar to those of acute limb ischemia. Pathological examination of the leg finally helped us to differentiate NF from mere limb ischemia.

Diagnosing necrotizing fasciitis

Necrotizing fasciitis was first described by Jones in 1981. Although it is rare, mortality rates are very high at 30–60% [2]. Although it is reported that optimal surgical intervention is needed to treat NF, the condition is still challenging to diagnose NF. The literature reports that the use of three tools—macroscopic/microscopic tools, imaging studies, and laboratory findings—can help with the diagnosis [3].

Although macroscopic findings such as skin discoloration, blisters or bullae, crepitus upon palpation, skin necrosis, and subcutaneous gas [3, 4] are considered typical signs of NF, these findings are similar to those in acute limb ischemia [5]. Microscopic findings such as the presence of WBCs around the fascia and fatty tissue are helpful in establishing a diagnosis of NF, but it takes several days to get the results of such examinations. Indeed, in our case, it took several days to confirm NF in the specimen obtained during surgery. Imaging modalities such as ultrasonography, CT, and magnetic resonance imaging are also considered useful. These imaging studies have revealed that increasing thickness of the fascial layer with or without enhancement is a typical sign but is not specific to the diagnosis of NF, especially when a differential diagnosis of acute limb ischemia is being considered [6]. Among laboratory findings, the laboratory risk indicator for necrotizing fasciitis (LRINEC) score, which includes C-reactive protein, WBC count, hemoglobin level, sodium level, and glucose level, has been developed to distinguish NF from non-necrotizing soft tissue infections, but this scoring system is not helpful in differentiating NF from acute limb ischemia [7]. There are three categories of LRINEC score (points, probability of NF): low (<5, <50%), intermediate (6–7, 50–75%), and high (>8, >75%). Although this score is not helpful in differentiating acute limb ischemia, it might have been useful as a reminder

of the potential diagnosis of NF early on in this case. It is important not to miss the diagnosis of NF in every high-risk patient, even if acute limb ischemia is suspected, because the macroscopic findings are similar.

Necrotizing fasciitis associated with *E. coli* pneumonia and *E. coli* bacteremia

The most common microorganisms in necrotizing fasciitis are *Streptococcus* and *Streptococcus* spp [2]. *Escherichia coli* is also a major cause of NF and accounts for about 12% of all primary and secondary causative organisms [8]. Usually *E. coli* is seen in the normal intestinal flora and can be associated with gastroenteritis, hepatobiliary infection, or urogenital infection. Our patient had symptoms similar to those of enteritis but not of urinary tract infection or hepatobiliary infection. We could not definitively establish direct relationships among the NF, pneumonia, and bacteremia, likely because pneumonia rarely causes bacteremia (only in 5–14% of cases) [9]. We suspected that, in our patient, the enteritis could have caused bacterial translocation (with spread to the left lower extremity causing NF) and the vomiting might have induced aspiration pneumonia. However, we could not rule out the possibility that the *E. coli* in the sputum might have been a different strain from that in the blood culture [8]. *Escherichia coli* can cause pneumonia, especially in immunosuppressed patients: Gram-negative rods, including *E. coli*, colonize the throats of 50% of immunosuppressed patients [10].

In this case, the unusual, undetermined origin of the *E. coli* bacteremia associated with the patient's shock status, together with the pneumonia revealed by the CT imaging, misled us in such a way that we did not diagnose NF early. Early diagnosis and surgical intervention are needed to treat NF patients. We should not forget the possibility that any systemic infection can result in NF, and we should use caution in our clinical approach to skin color changes similar to those found in acute limb ischemia.

CONCLUSION

Although the diagnosis of necrotizing fasciitis (NF) is often difficult, the use of three tools—macroscopic/microscopic tools, imaging studies, and laboratory findings—can help with the diagnosis. It is important not to miss the diagnosis of NF in every high-risk patient, even if acute limb ischemia is suspected. In addition, considering systemic infection is also important when sputum culture grew *E. coli*.

Author Contributions

Takahiro Matsuo – Substantial contributions to conception and design, Acquisition of data, Analysis and interpretation of data, Drafting the article, Revising

it critically for important intellectual content, Final approval of the version to be published

Hiroki Mochizuki – Analysis and interpretation of data, Revising it critically for important intellectual content, Final approval of the version to be published

Atsushi Mizuno – Analysis and interpretation of data, Revising it critically for important intellectual content, Final approval of the version to be published

Keiichi Furukawa – Analysis and interpretation of data, Revising it critically for important intellectual content, Final approval of the version to be published

Yutaro Nishi – Analysis and interpretation of data, Revising it critically for important intellectual content, Final approval of the version to be published

Koichiro Niwa – Analysis and interpretation of data, Revising it critically for important intellectual content, Final approval of the version to be published

Guarantor

The corresponding author is the guarantor of submission.

Conflict of Interest

Authors declare no conflict of interest.

Copyright

© 2016 Takahiro Matsuo et al. This article is distributed under the terms of Creative Commons Attribution License which permits unrestricted use, distribution and reproduction in any medium provided the original author(s) and original publisher are properly credited. Please see the copyright policy on the journal website for more information.

REFERENCES

1. Brook I, Frazier EH. Clinical and microbiological features of necrotizing fasciitis. *J Clin Microbiol* 1995 Sep;33(9):2382–7.

2. Anaya DA, Dellinger EP. Necrotizing soft-tissue infection: diagnosis and management. *Clin Infect Dis* 2007 Mar 1;44(5):705–10.
3. Wang YS, Wong CH, Tay YK. Staging of necrotizing fasciitis based on the evolving cutaneous features. *Int J Dermatol* 2007 Oct;46(10):1036–41.
4. Creager MA, Kaufman JA, Conte MS. Clinical practice. Acute limb ischemia. *N Engl J Med* 2012 Jun 7;366(23):2198–206.
5. Struk DW, Munk PL, Lee MJ, Ho SG, Worsley DF. Imaging of soft tissue infections. *Radiol Clin North Am* 2001 Mar;39(2):277–303.
6. Wong CH, Khin LW, Heng KS, Tan KC, Low CO. The LRINEC (Laboratory Risk Indicator for Necrotizing Fasciitis) score: a tool for distinguishing necrotizing fasciitis from other soft tissue infections. *Crit Care Med* 2004 Jul;32(7):1535–41.
7. McHenry CR, Piotrowski JJ, Petrinic D, Malangoni MA. Determinants of mortality for necrotizing soft-tissue infections. *Ann Surg* 1995 May;221(5):558–63; discussion 563–5.
8. Clermont O, Glodt J, Burdet C. Complexity of *Escherichia coli* bacteremia pathophysiology evidenced by comparison of isolates from blood and portal of entry within single patients. *Int J Med Microbiol* 2013 Dec;303(8):529–32.
9. Campbell SG, Mairie TJ, Anstey R, Dickinson G, Ackroyd-Stolarz S. The contribution of blood cultures to the clinical management of adult patients admitted to the hospital with community-acquired pneumonia: a prospective observational study. *Chest* 2003 Apr;123(4):1142–50.
10. Jonas M, Cunha BA. Bacteremic *Escherichia coli* pneumonia. *Arch Intern Med* 1982 Nov;142(12):2157–9.

Access full text article on
other devices



Access PDF of article on
other devices



Edorium Journals: An introduction

Edorium Journals Team

About Edorium Journals

Edorium Journals is a publisher of high-quality, open access, international scholarly journals covering subjects in basic sciences and clinical specialties and subspecialties.

Invitation for article submission

We sincerely invite you to submit your valuable research for publication to Edorium Journals.

But why should you publish with Edorium Journals?

In less than 10 words - we give you what no one does.

Vision of being the best

We have the vision of making our journals the best and the most authoritative journals in their respective specialties. We are working towards this goal every day of every week of every month of every year.

Exceptional services

We care for you, your work and your time. Our efficient, personalized and courteous services are a testimony to this.

Editorial Review

All manuscripts submitted to Edorium Journals undergo pre-processing review, first editorial review, peer review, second editorial review and finally third editorial review.

Peer Review

All manuscripts submitted to Edorium Journals undergo anonymous, double-blind, external peer review.

Early View version

Early View version of your manuscript will be published in the journal within 72 hours of final acceptance.

Manuscript status

From submission to publication of your article you will get regular updates (minimum six times) about status of your manuscripts directly in your email.

Our Commitment

Six weeks

You will get first decision on your manuscript within six weeks (42 days) of submission. If we fail to honor this by even one day, we will publish your manuscript free of charge.*

Four weeks

After we receive page proofs, your manuscript will be published in the journal within four weeks (31 days). If we fail to honor this by even one day, we will publish your manuscript free of charge and refund you the full article publication charges you paid for your manuscript.*

Favored Author program

One email is all it takes to become our favored author. You will not only get fee waivers but also get information and insights about scholarly publishing.

Institutional Membership program

Join our Institutional Memberships program and help scholars from your institute make their research accessible to all and save thousands of dollars in fees make their research accessible to all.

Our presence

We have some of the best designed publication formats. Our websites are very user friendly and enable you to do your work very easily with no hassle.

Something more...

We request you to have a look at our website to know more about us and our services.

* Terms and condition apply. Please see Edorium Journals website for more information.

We welcome you to interact with us, share with us, join us and of course publish with us.



Edorium Journals: On Web



Browse Journals

CONNECT WITH US

