

Special extra article

Difference of preliminary impression takings between conventional mandibular complete denture and the mandibular complete denture intended with effective suction

– Recommended impression system, Frame Cut Back Tray



Dr. Jiro Abe, 1-12-43-2F Sengawa, Chofu, Tokyo, Japan
e-mail : Jiroabe @ra2.so-net.ne.jp

Representative of Japan Denture Association,
Homepage <http://denture.jugem.jp/>

▪ Introduction

Attaining of effective suction in a mandibular complete denture is one of hard clinical techniques that no one has ever achieved so far and this issue has received much attention in recent years^{1~3)}. If any denture adhesive commercially available is applied to a maxillary complete denture, the denture becomes less mobile and better chewing for a patient. Likewise a mandibular complete denture that is effectively suctioned on the residual ridge will become less mobile and will create a secured sense of chewing⁴⁾.

At this present time, it is yet unknown exactly whether or not a mandibular complete denture with effective suction really chews well. Or it is yet unknown either whether it can really control progressive resorption in the alveolar ridge. We are not so far able to get a correct answer. But a clinical verification report⁵⁾ has that, by providing the suction effective mandibular complete denture, significant improvement is made of chewing as well as a reported fact from clinics that the relining frequency has decreased postoperatively. They suggest the possibility that residual ridge morphology will be maintained over long periods through suctioning the denture on the residual ridge.

Meanwhile, the followings are true; once a dentist can make a mandibular denture with effective suction successfully, he or she never willingly returns to making a denture using with conventional type of impression compound. It may be because not only a patient but also an operator may become strongly confident that “Far better denture has been made and inserted this time than a previous one”. What is most important for attaining a mandibular complete denture with effective suction is to understand completely the suction mechanism of a mandibular complete denture. And if one can master skills of clinical procedures based on this mechanism, a mandibular complete denture will be retained successfully on the alveolar ridge^{6,7)}.

Now this article will be referred at first to an initial step of this practice, that is, preliminary impression taking using Frame Cut Back Tray that is beneficial to a mandibular complete denture with effective suction and then will be referred to the outline setup of custom tray⁸⁾. It would be highly appreciated if the readers could find in what way the differences are from conventional impression methods and furthermore could understand differences from conventional type of custom tray outline.

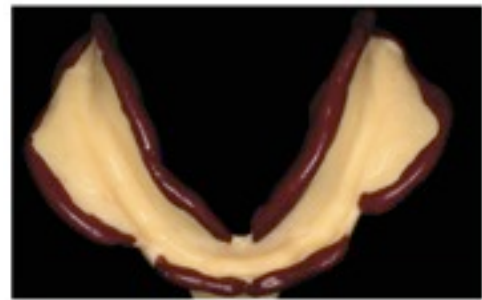
Fig. 1 Alveolar residual ridges (front view).

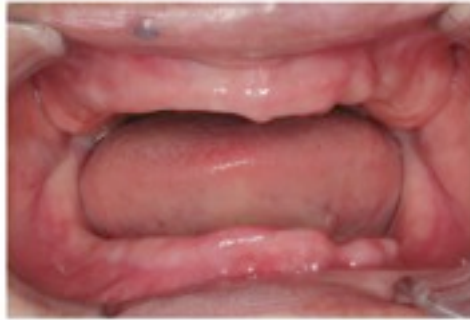

Fig. 2 Alveolar residual ridge in the mandible.

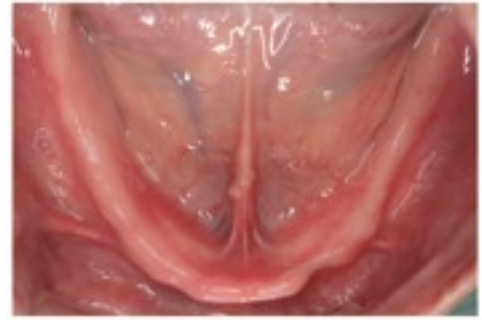

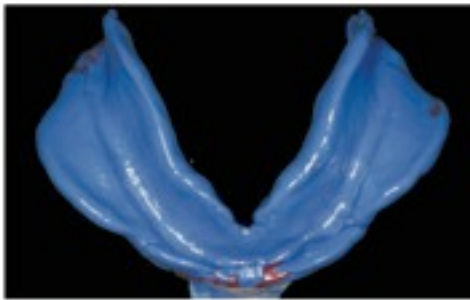Fig.3,4 Conventional denture is in pursuit of extension of load bearing surface based on muscle attachments.



▪ Defining of conventional type of impression taking

Conventional type of impression taking is an impression method that employs a custom impression tray and impression compound as proposed by Dr. Boucher and others⁹⁾ and introduced in modern dental school education throughout Japan. Today in replacement of impression compound, the marginal border molding is processed increasingly with silicone impression material of border molding type. It is an impression method that is clearly understandable and educationally excellent as an impression body is built up while learning individual parts of muscle attachments and oral tissues through the phases of impression taking. Moreover, the first major goal of this method is to take an impression of denture bearing alveolar residual ridge spaciouly (Fig.1,2) in order to gain as extensive load bearing surface as possible so that masticatory efficiency can be better enhanced^{10,11)} (Fig.3,4). It is muscle attachments that the concept of denture design and construction is based on. As it is also based on the idea of extended range of impression surface as long as this range is free from interfering muscle movements, its preliminary impression should be essentially intended to be taken with clear understanding of muscle attachment areas (anatomical landmarks)(Fig.5,6).

And this denture of extensive surface area is called as "Retention & Stabilization" type of denture because it can be stabilized under loaded occlusal force and can be retained with buccal mucous membrane and lips. Its preliminary impression that is clearly defined with muscle attachments not only can visualize and help setting up the outline of custom impression tray more easily than in the oral cavity, but also can be verified of shapes of residual ridges, state of attached different frena and retromolar pads from outside of oral cavity.

In this article, Accu-Dent Impression system (Fig.7) developed by Ivoclar Vivadent AG. will be illustrated for representing the idea based on Myostatic Outline (Setting up idea of custom tray outline based on static muscle attachment). Comparatively stronger pressure is provided to take a preliminary impression using a combined method of two kinds of materials: higher flow behavior of alginate impression material (Accu-Syringe Gel) and lower flow behavior of alginate material but with higher density (Accu-Tray Gel). Consequently a preliminary impression becomes available with clearly defined muscle attachment¹²⁾.

Clarified muscle attachment areas and anatomical landmarks necessary for a denture.

Deep impression of the retromylohyoid fossa that clarifies mylohyoid muscle line in the muscle attachment of mylohyoid muscles.

Impression of the retromolar pads are clearly taken.

Impression of buccal shelves are extensively taken.

Bony external oblique line is clearly defined in the buccal muscle attachment.

Lingual frenum

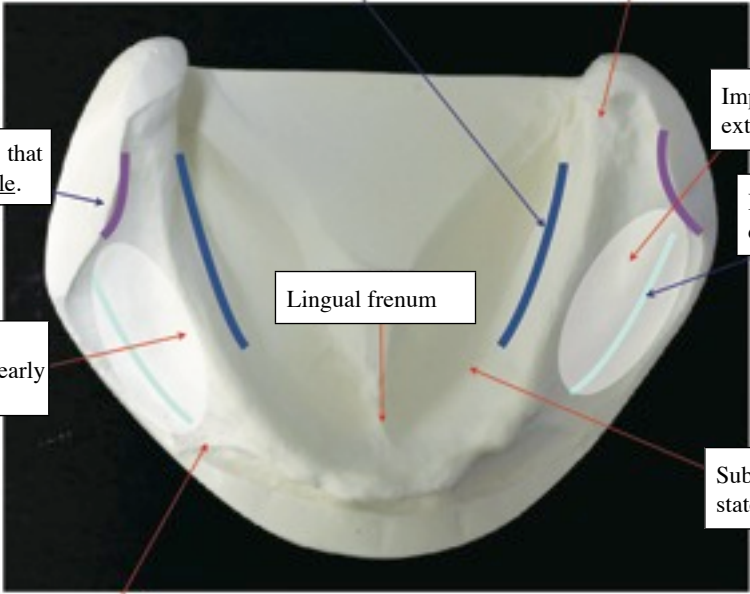
Sublingual fold flange is taken in an extensive state clearly.

Clarified masseter muscle line that demonstrates contracted masseter muscle.

Residual ridge shapes are clearly taken.

Clearly defined buccal frenum.

Fig.5



Clarified muscle attachment areas from the anterior teeth to the premolars and anatomical landmarks necessary for a denture.

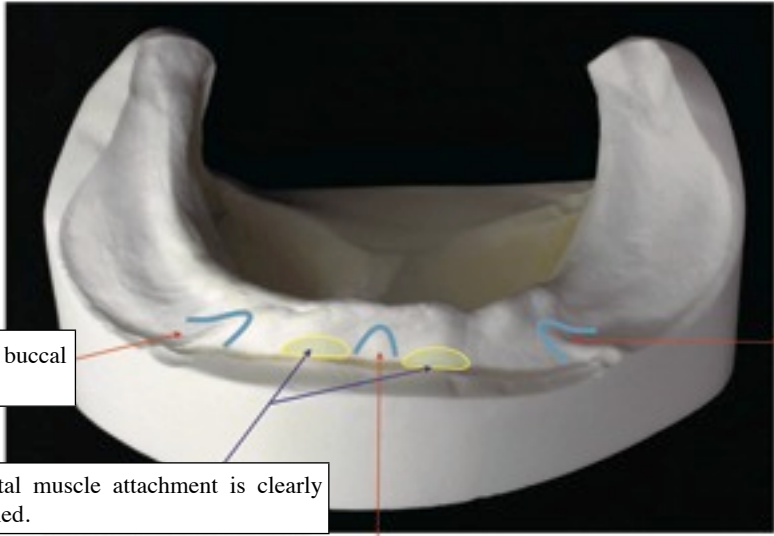
Clearly defined buccal frenum.

Clearly defined buccal frenum.

Mental muscle attachment is clearly defined.

Median inferior labial frenum is clearly defined

Fig.6



Preliminary impression by Accu-Dent System from Ivoclar Vivadent AG. – Impression method to take necessary anatomical landmarks focusing on muscles in majority for denture construction.

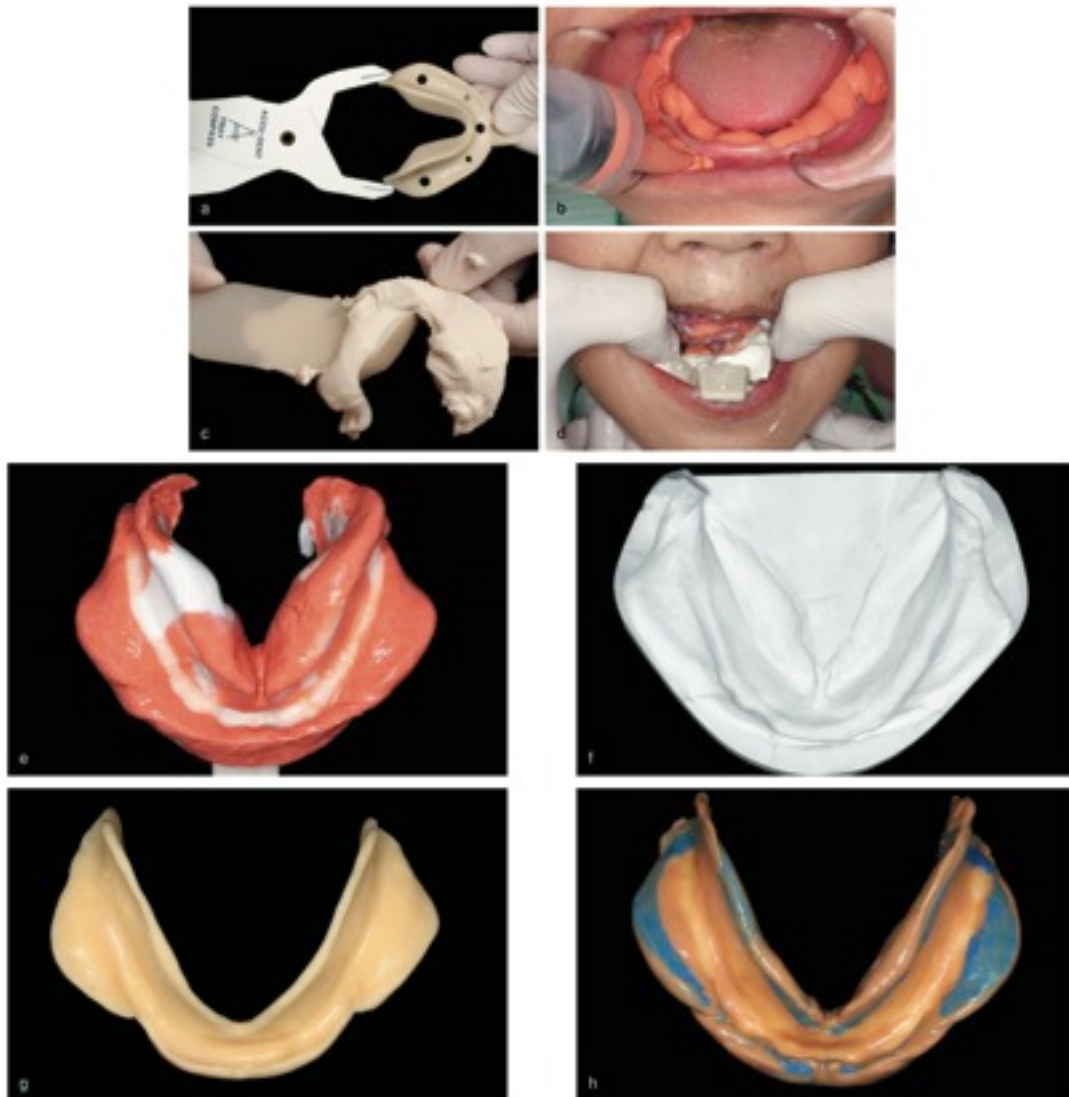


Fig.7 Preliminary impression by Accu-Dent System. (a) Selection of tray that is identical to adapt with a residual ridge. (b) Injection of high flow syringe impression material (Accu-Syringe Gel) into the oral cavity with the special syringe in the kit. (c) Mounting of low flow tray impression material (Accu-Tray Gel) high in the rear part of the tray. (d) Insert the mounted tray into the mouth and press the tray with good pressure. (e) Impression clearly defined with necessary anatomical landmarks for designing a denture primarily based on muscle attachments. (f) Cast stone model taken from preliminary impression with broadly extended surface in the residual ridge. (g) Custom impression tray made up from references of muscle attachments and other anatomical landmarks. Product material: Ivoren (Ivoclar Vivadent AG) (h) Final precision impression with broadly extended denture bearing surface. Product material: Virtual (Ivoclar Vivadent AG)

▪ Impression method in pursuit of mandibular complete denture with effective suction

Meanwhile, an impression method in pursuit of a mandibular complete denture with effective suction has been developed by the author in order to meet the complaints; “Mandibular denture dislodges easily while speaking” or “Mandibular denture wobbles while eating”.

The objective is to attain effective suction with a mandibular complete denture by closing the denture peripheral border entirely with oral mucous membrane. Clinically speaking, the state that one can feel negative pressure of adhesion when trying to remove a denture is called “suction”, and it is distinctively differentiated from “the state of adhesion” that is weakly retained with saliva. The suction what we are discussing is based on the idea how to accomplish the closure of entire border of denture base with buccal mucous membrane, lower lip, sublingual fold mucous membrane as well as the mucous membrane in the retromylohyoid fossa. For this purpose, a preliminary impression is an impression taken under static state of oral cavity, which is to say, an impression of oral mucous membrane that lies on top of each other of connective tissues, fatty tissues, and salivary glands above the muscles. In short, by taking an impression of oral cavity as static as possible, it is vital that such an impression should never interfere with the oral mucous membranes that cover a denture (Fig.8).

There is no doubt that the readers themselves might have already experienced the fact that suction effect could be difficult to accomplish using conventional impression method with impression compound. In other words, the entire closure of denture peripheral border cannot be attained in many cases but only limited to a partial closure, when special attention is made on extending the load bearing area based on the musculatures as described above.

And an especially difficult case of closure is an area surrounding the retromolar pad. Many varieties of muscles are attached to the surrounding area, but there is no muscle that attaches directly with the retromolar pad. So it deforms very easily under impression pressure.

Closure of area surrounding the retromolar pad consists of two different kinds of closure: ① intimate closing contact between denture impression surface and mucous membrane surface of the retromolar pad (Fig.9) and ② external surface closure with buccal mucous membrane and tongue on the denture polishing surface where the retromolar pad is covered (Fig.10).

What is most vital in order to attain intimate closing between denture impression surface and mucosal surface at the retromolar pad is how a preliminary impression should be taken with alginate impression material without deforming the retromolar pad. Primary cause of exerting a strong impression pressure on the retromolar pad is the impression tray frame, and secondary cause is a pressurized impression taking with a low flow and high density material or compound (Fig.11–13).

Fig.8 Mandibular denture with suction. Based on the concept of closure in the entire denture peripheral border. Nothing but artificial teeth can be seen even when the mouth opened. Effective suction can be accomplished by making a denture contained with oral mucous membrane.

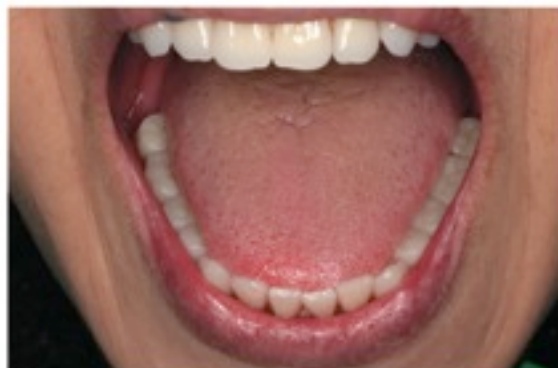

Fig.9 Intimate inner closure of denture mucosal surface in the retromolar pad area.

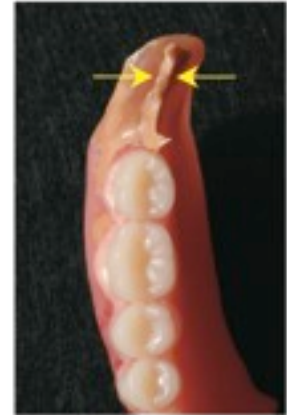
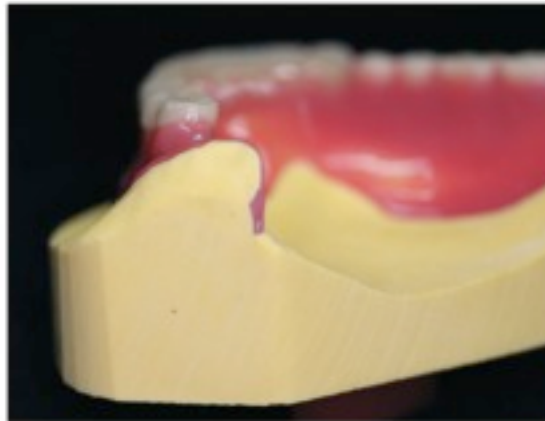


Fig.10 Closure of the external denture surface in the retromolar pad area (BTC confirmed in the retromolar pad area of the denture. B: Buccal mucosa, T: Tongue side wall, C: Contact point)

Comparison of three different impressions as to buccal mucosal extension

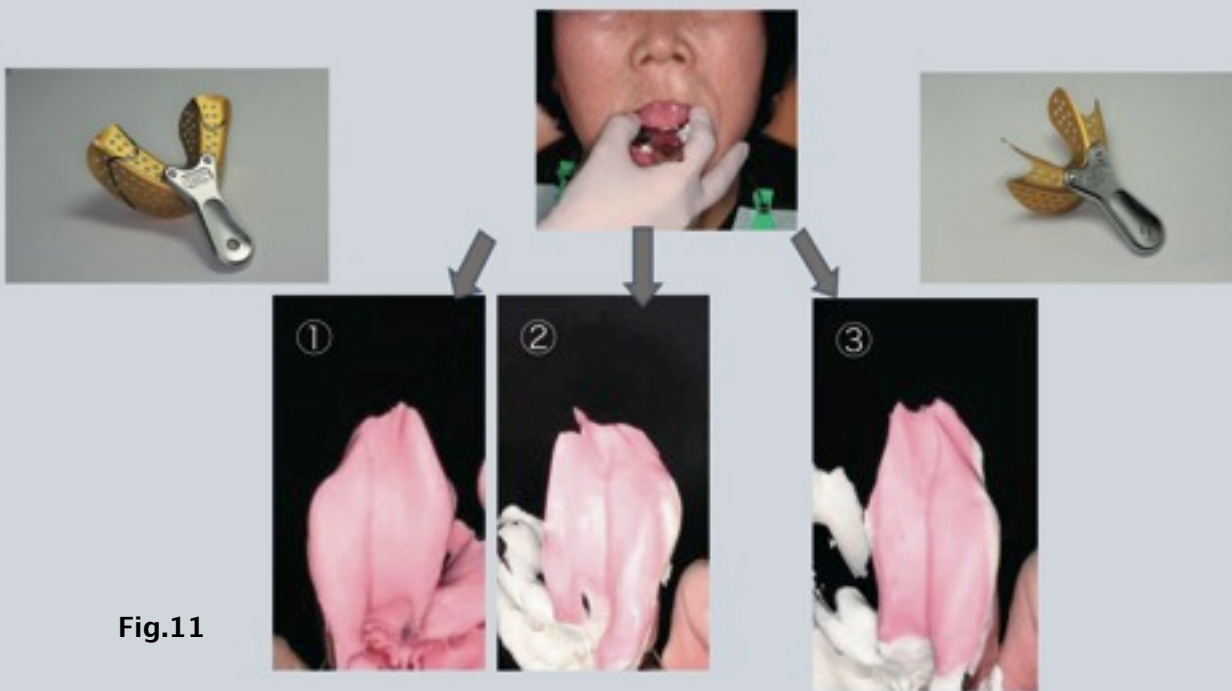


Fig.11

<p>① Mandibular dentate tray: Alflex Dust Free</p>	<p>② Mandibular dentate tray: Alflex Dust Denture, Alflex Dust Free</p>	<p>③ Tray with reduced upper part of the retromolar pad and buccal shelf: Alflex Dust Denture, Alflex Dust Free</p>
--	---	---

Fig.11 The study is conducted by analyzing cast stone models made from these three impressions to determine whether the causes of extended impression are on the grounds from the presence of tray frame or from the density of impression material. (Tohoku University Graduate School of Dentistry: Abe, J., Tanaka, Y., Hattori, Y., Sasaki K.)

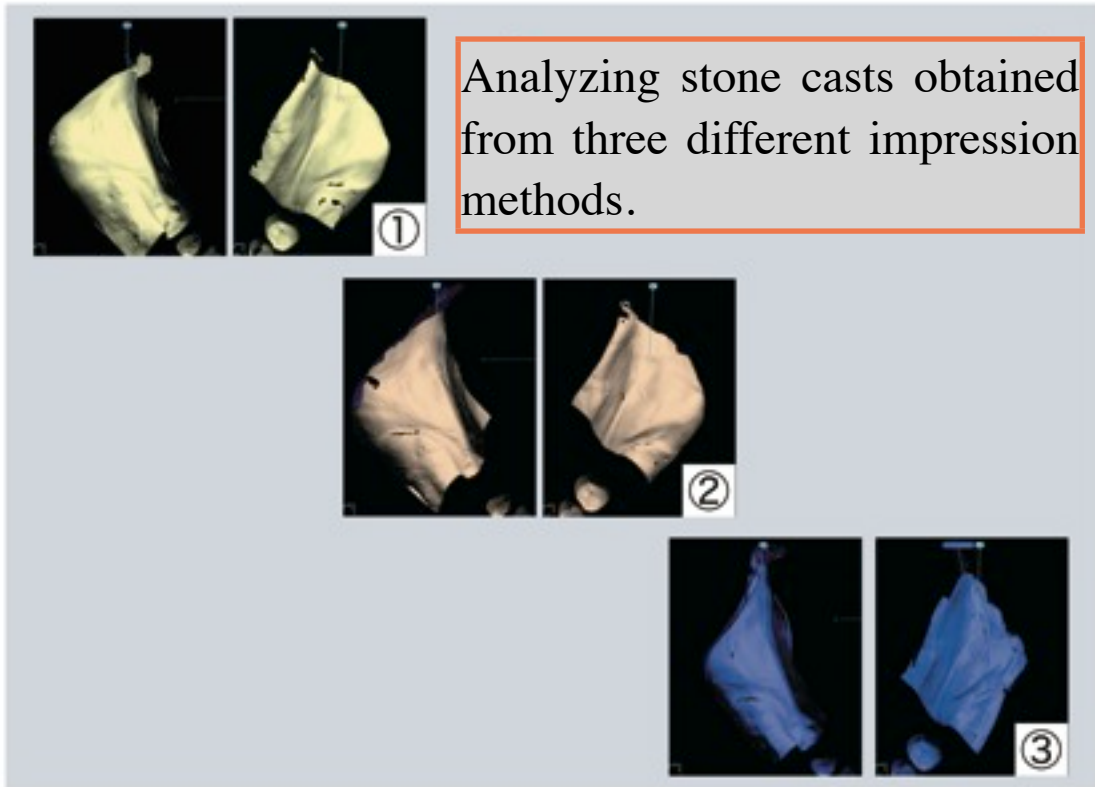


Fig.12
Non-contact type 3D digitizer (COMET V2: by Steinbichler GmbH is used.)

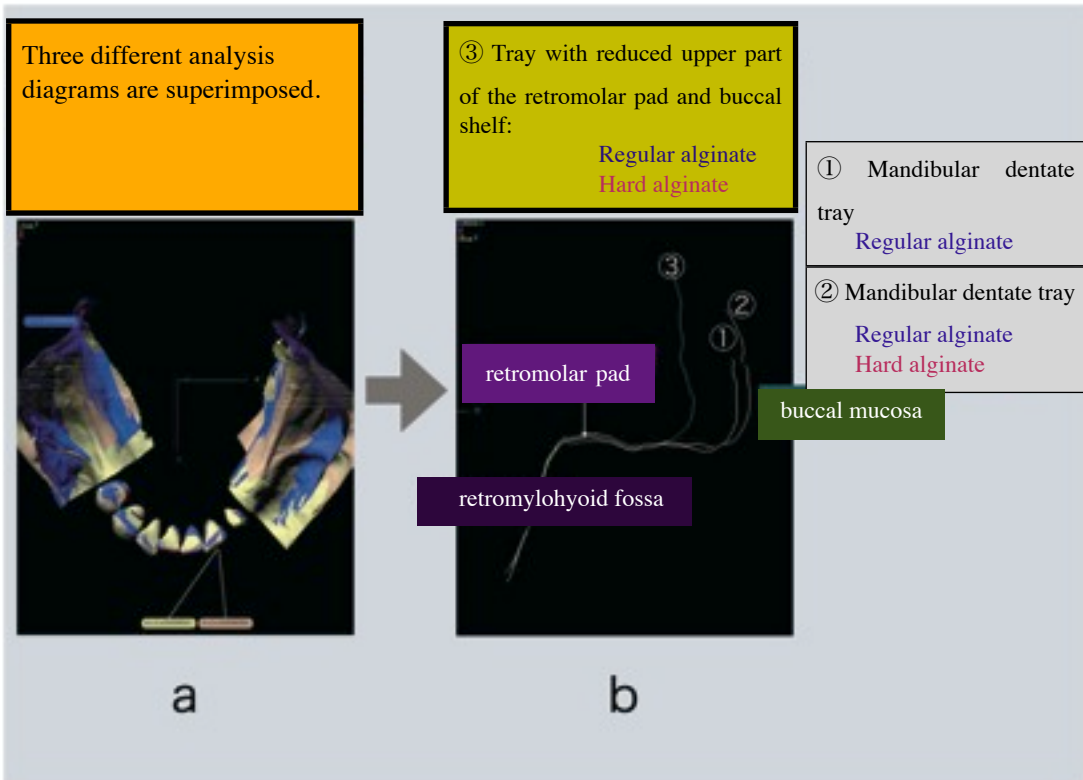


Fig.13 It is cleared that the impression taken through the doubled impression taking with reduced frame of the retromolar pad in ③ has shown to extend the buccal mucosa most externally. Accordingly the major cause of taking an extensive impression is the presence of tray frame.

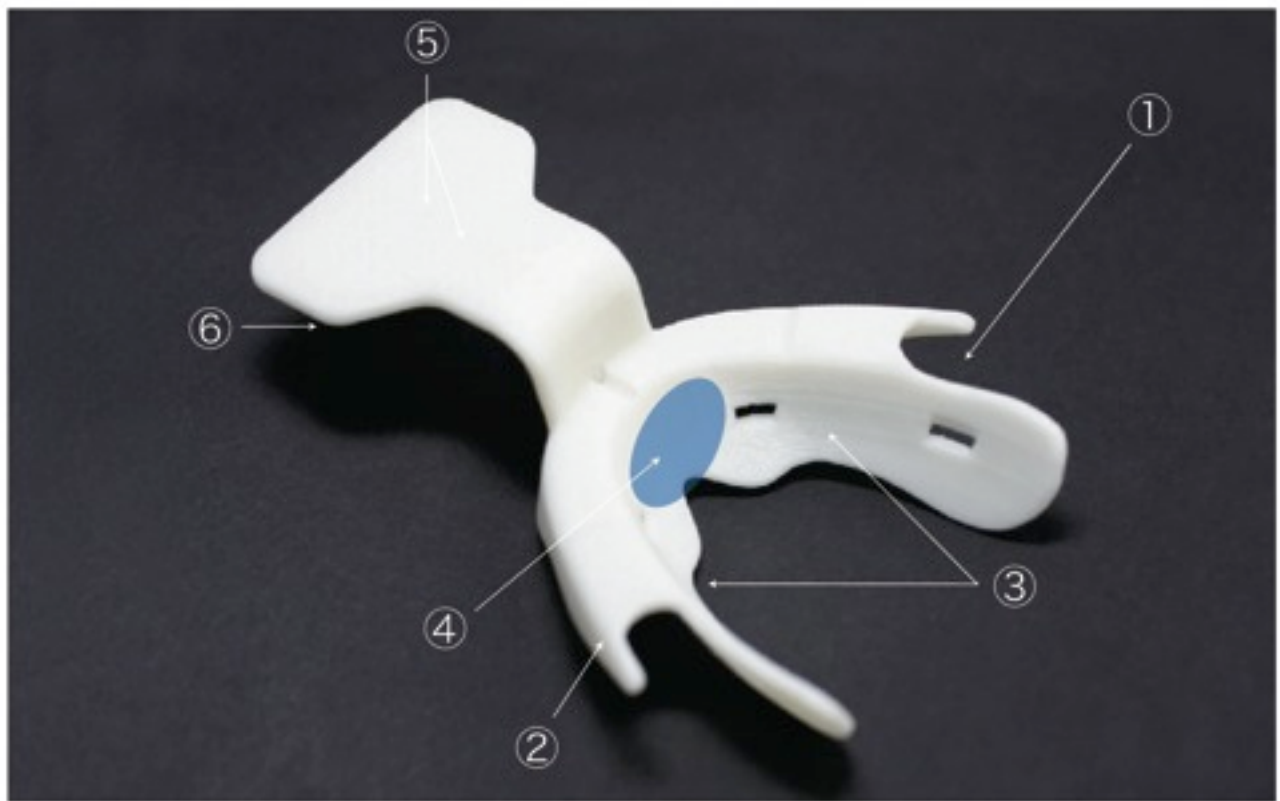

Fig.14 Features of FCB Tray (distributed by Morita Corp.) ① Frame reduction in the retromolar pad, ② Buccal frame reduction, ③ Extensive tongue space, ④ Recess that tongue tip touches, ⑤ Line indent to indicate locating tray when seated, ⑥ Tray handle that is easy to bite

In order to solve these two causes, the author has developed Frame Cut Back Tray (hereafter called FCB Tray) or as commonly called “a frame-less tray” (Fig.14). Two major features are; it is designed to reduce the frame of Tray around above the retromolar pad and to prevent from deforming the pad by relieving impression pressure applied to the pad toward externally from the Tray. And next feature has another reduction of about two thirds of frame size around the buccal shelf area in order to prevent from overextension into the buccal side. If overextension of mucous membrane made buccally in the external direction, it tends to lose closure of denture base on and around the retromolar pad. This issue will be explained further by referring to the author’s experiment of the endoscope.

A copy of a mandibular complete denture is made with good effective suction and is modified to accept the endoscope for viewing around the retromolar pad (Fig.15~18). As shown in Fig.18, closure is confirmed complete, when mouth closed, exhibiting close contact of buccal mucous membrane and tongue on the denture base around the retromolar pad.

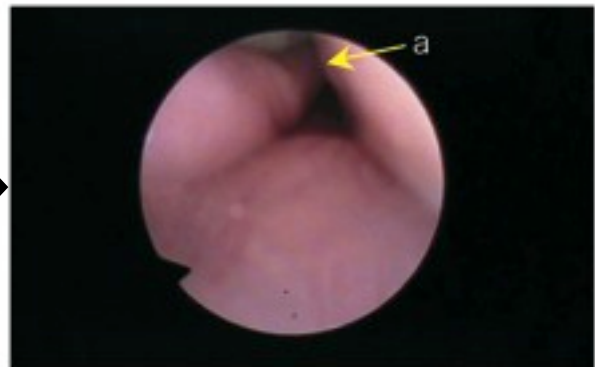
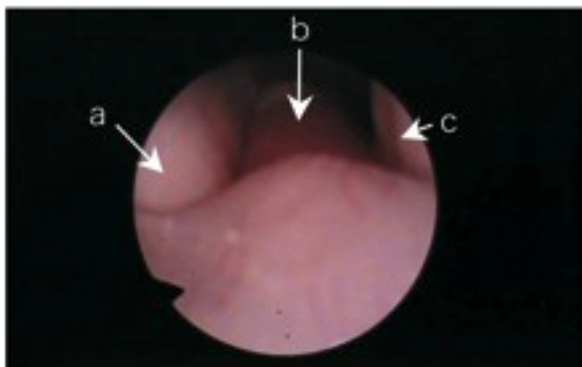
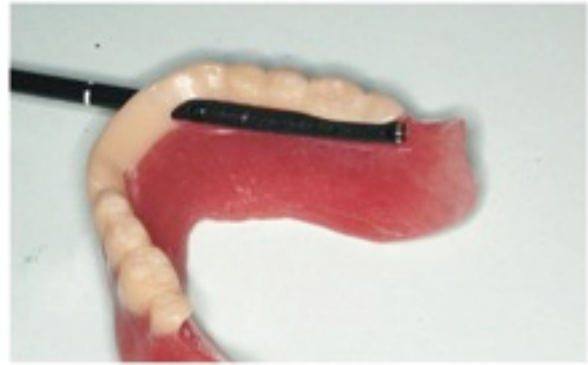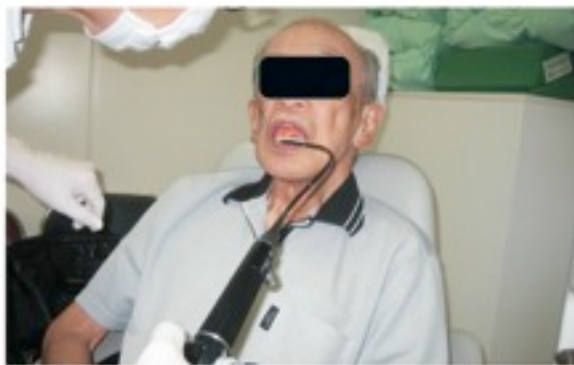Fig.15 ~ 18 Copy denture made from a mandibular complete denture with good suction is joined with the modified endoscope unit for observing the retromolar pad area. Fig.17. When mouth opened, a: buccal mucosa, b: the retromolar pad, c: tongue. Fig.18. BTC point in a. is confirmed when mouth closed.

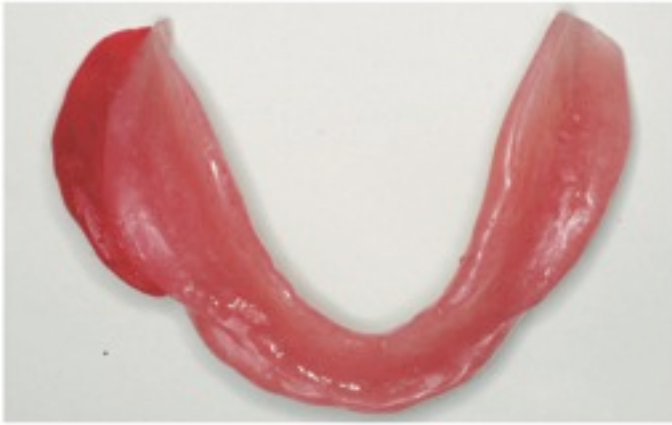

Fig.19 Wax is added to the denture peripheral border to overextend the buccal side.

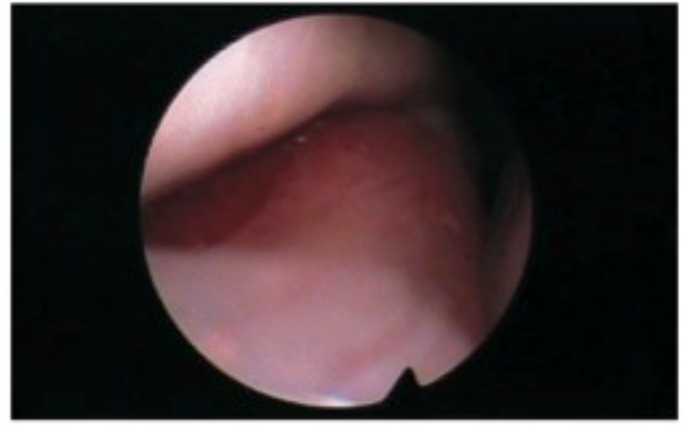

Fig.20 *ibid.* Endoscopic photo when mouth closed. BTC point is lost.

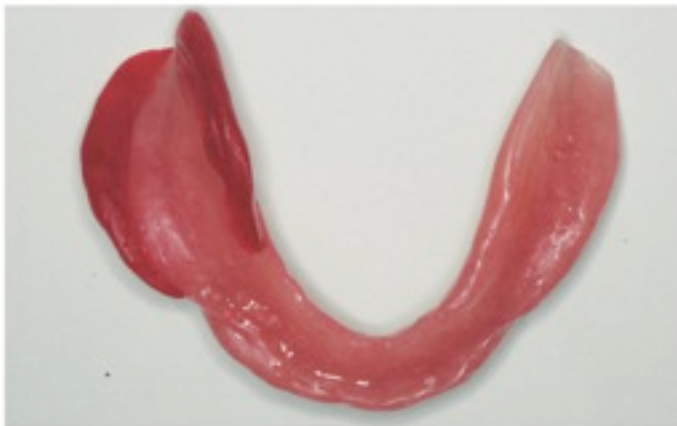

Fig.21 Another wax is added to the lingual side to overextend the retromylohyoid fossa.

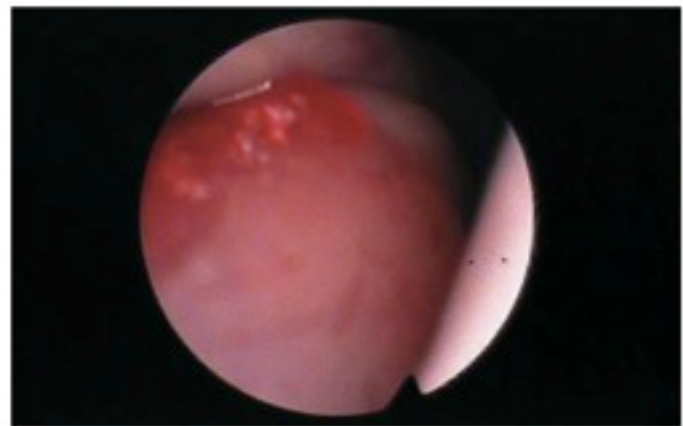

Fig.22 *ibid.* Endoscopic photo. BTC point is lost. It is known to inhibit the closure of posterior border with wax overextension.

The author has given this contact situation a name as BTC Point (Buccal mucosa, Tongue side wall and Contact)⁶.

And then the denture base is added with utility wax (red) in order to extend the buccal side intentionally while closing the mouth. The wax mass is shown to push the buccal mucous membrane and to inhibit creating BTC Point (Fig.19,20).

Furthermore another trial is made to extend the base intentionally into the retromylohyoid fossa. Added wax mass on the lingual side is shown to prevent the tongue from reaching onto the base surface around the retromolar pad and no BTC Point is observed (Fig.21,22). It is suggested from this experiment that any closure may be difficult to attain in the external surface of the base on the retromolar pad, if unreasonable impression taking is done for purpose of extending a denture surface.

FCB Tray is designed to prevent deformation of the retromolar pad caused by the presence of tray frame and dense behavior of impression material and, at the same time, it is designed to reduce the frame as much as possible in the posterior buccal region to prevent such a consequence. In short, real goal of FCB Tray is to take a neutral shape in the oral cavity prior to taking final precision impression without providing overextension of preliminary impression.

Next, preliminary impression taking method will be explained using with FCB Tray that has been developed for solution of these problems above (Fig.23). Also this method will make a large difference from conventional method in setting up the outline of custom tray.

Preliminary impression using FCB Tray
 – Impression method that takes natural shapes of oral cavity with as little deformation as possible.

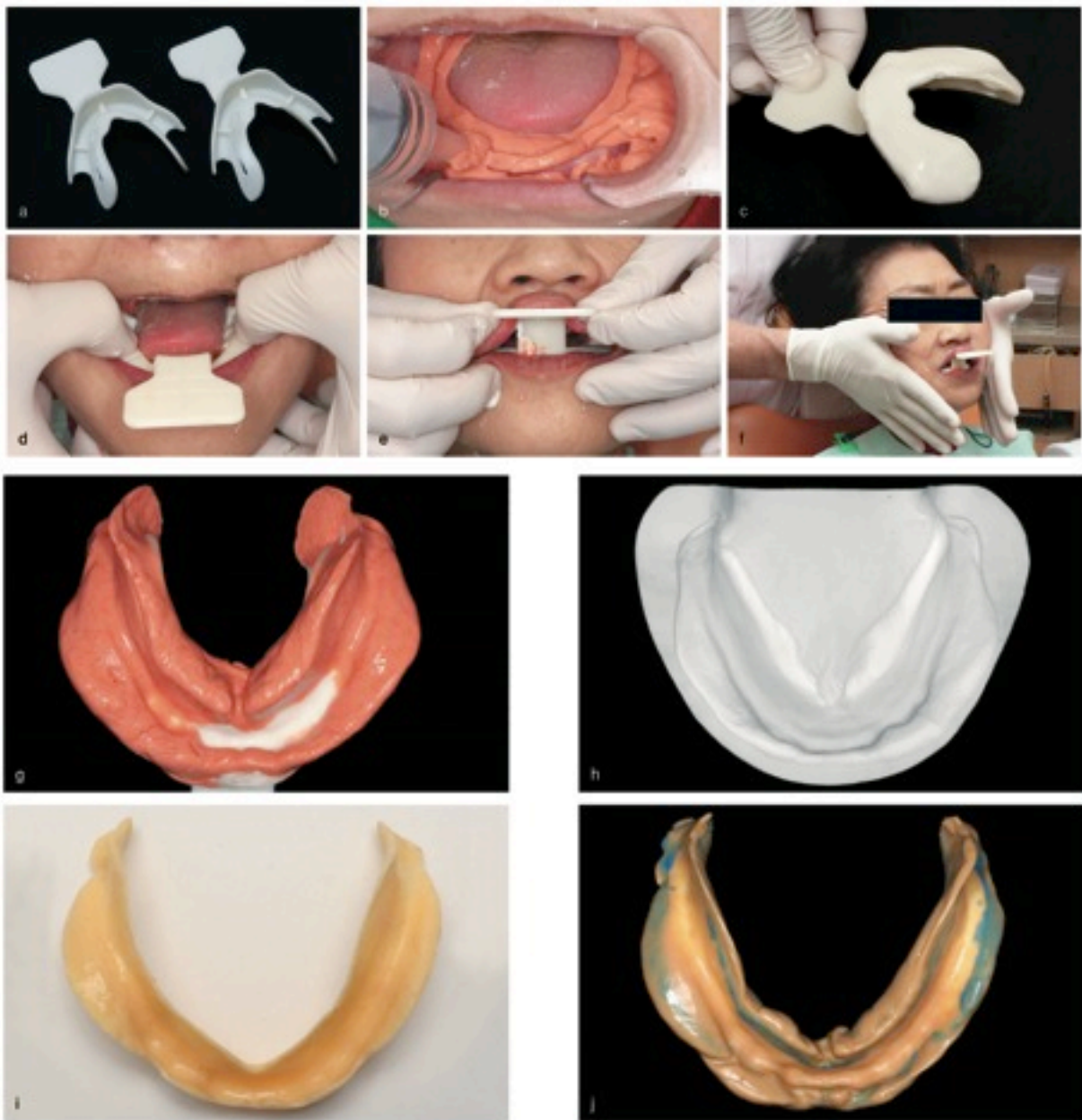

Fig.23 Preliminary impression taken with FCB Tray. (a) FCB Tray (distributed by Morita Corp., manufactured by YDM Corp.) Select proper tray size to match an edentulous ridge. Selection is made from size M and L and can be reduced as needed. (b) Injection of higher flow of impression material for syringe use (Accu-Syringe Gel) into the oral cavity using a syringe (Terumo 50ml, ss-50Cz or 30ml, ss-30Cz 20k). (c) Mount a lower flow of impression material for tray use (Accu-Tray Gel) lightly on the tray. (d), (e) Seat the tray in the mouth and press lightly and instruct to close the mouth. (f) Operator moves to stand behind and strokes the patient cheeks upward. (g) This is a natural impression made up only with density of impression material and no extensive impression is tried to specify muscle attachments. (h) Cast stone model obtained by the operator without extending intentionally. (i) Custom tray intended to obtain suction. (j) Final precision impression that is aimed at a suction effective mandibular complete denture.

▪ **What is the difference between these two impressions**

Comparison of different preliminary impressions from same patient will be presented here. One is made as a conventional method based on Accu-Dent System from Ivoclar Vivadent AG. combined with good flow of alginate material (Accu-Syringe Gel) and highly dense material (Accu-Tray Gel) by open mouthed pressurized impression. The other is made with same impression materials using FCB Tray by closed mouth static impression. Comparisons can be clarified as shown in impression sizes, shape differences of the retromolar pad, and differences of impression areas of buccal shelves (Fig.24~31).

▪ **Two major different outlines of custom trays**

Primary objective of denture construction in general is, as described in the introduction above, to extend denture bearing surface area by focusing on muscle attachments as for conventional type of preliminary impression. And, as for preliminary impression of good suction effect, it is to close the denture peripheral border entirely by focusing on movement of oral mucous membrane that works to contain a denture base. Naturally different objectives have different denture making techniques (Fig.32). Illustrations will be presented to show different outlines of custom trays taken from same patient by way of these two different preliminary impressions. The author sincerely hopes that understanding of these differences will help the readers to achieve for future successful practices (Fig.33~49).

Comparisons of two different preliminary impressions

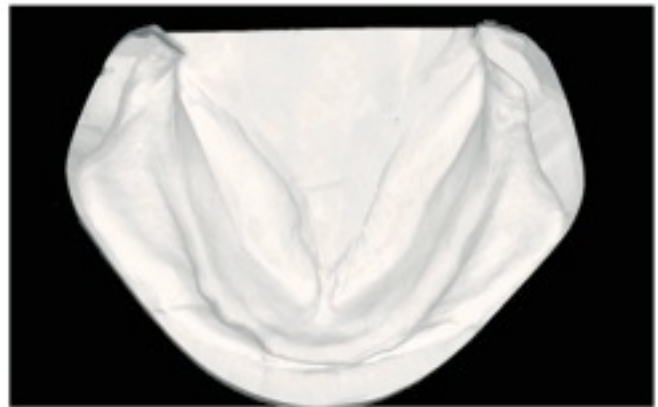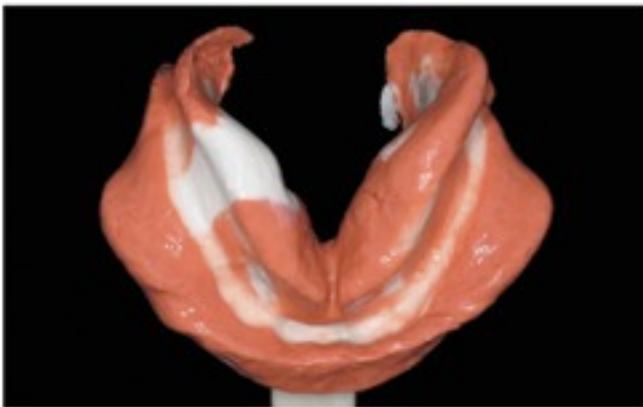


Fig.24,25 Preliminary impression by Accu-Dent System and its cast.

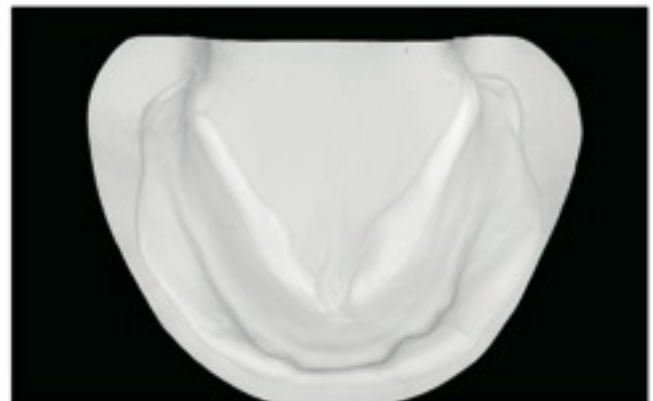
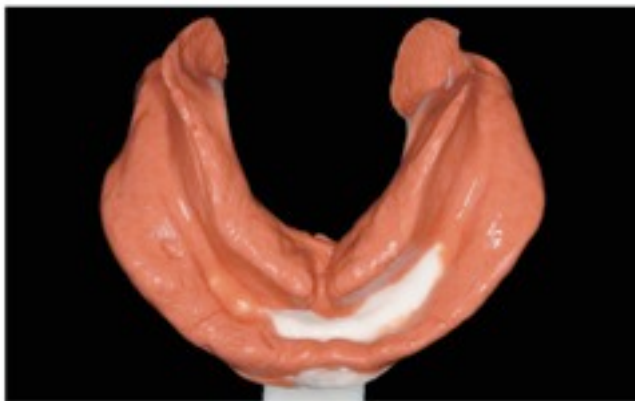
Fig.26,27 Preliminary impression by FCB Tray and its cast.

Comparisons of two different preliminary impressions, continued

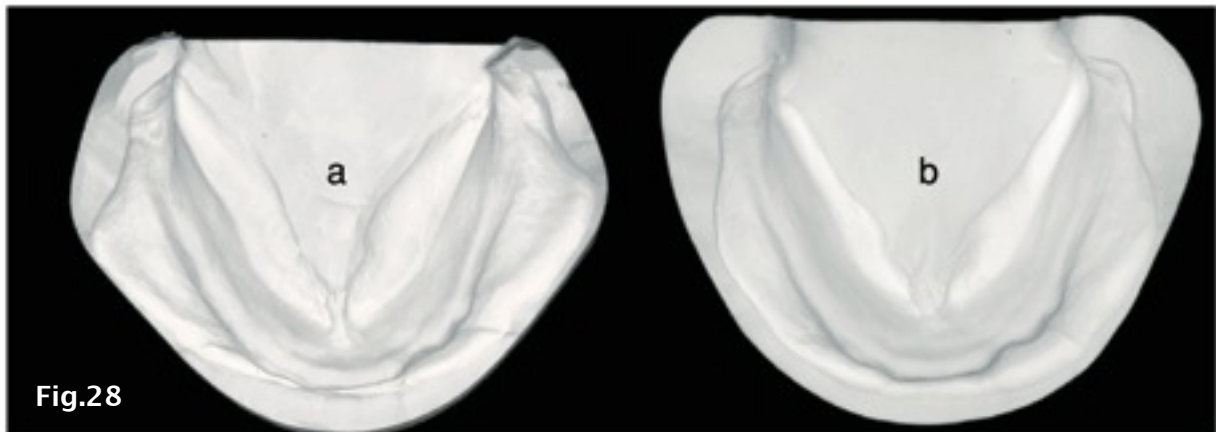


Fig.28

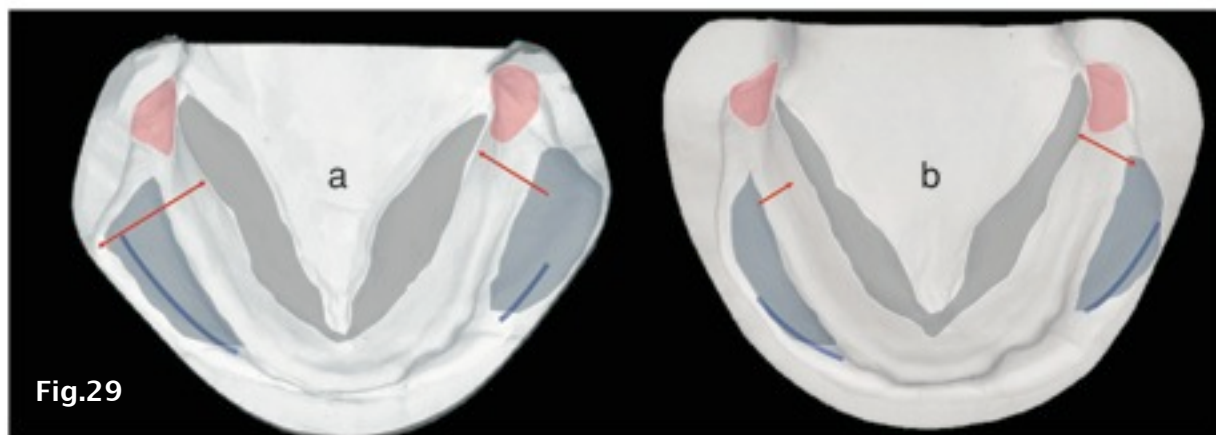


Fig.29

Fig.28,29 Differences of these two impressions

28: (a) Accu-Dent System, (b) FCB Tray System

29: (a) Accu-Dent System, (b) FCB Tray System

☐: Buccal flange region, ☐: Retromolar pad region, ☐: Lingual flange region,

—: Buccal shelf width, —: Bony external oblique line

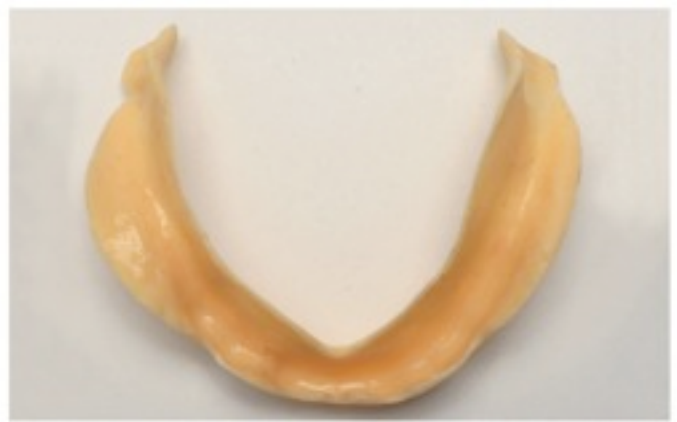
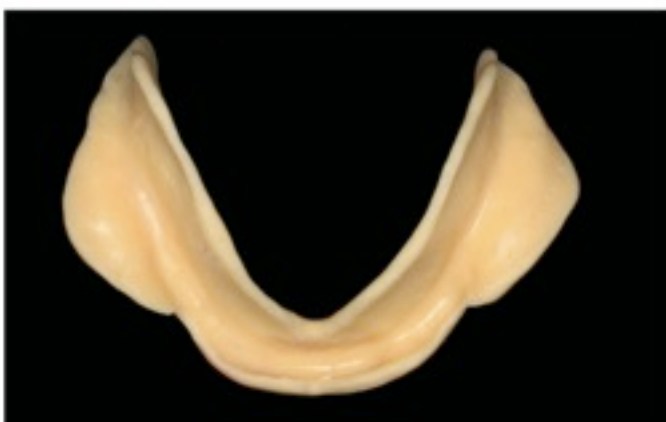
Fig.30,31 Denture size is finally determined by custom tray size. So outline of custom tray represents a concept of denture that is to be made. (30: Custom tray with a concept of muscles, 31: Custom tray with a concept of suction)

A change of denture making concept, and a change of final denture shape.

Load bearing surface oriented
conventional type denture

Entire border closure oriented
suction effective denture

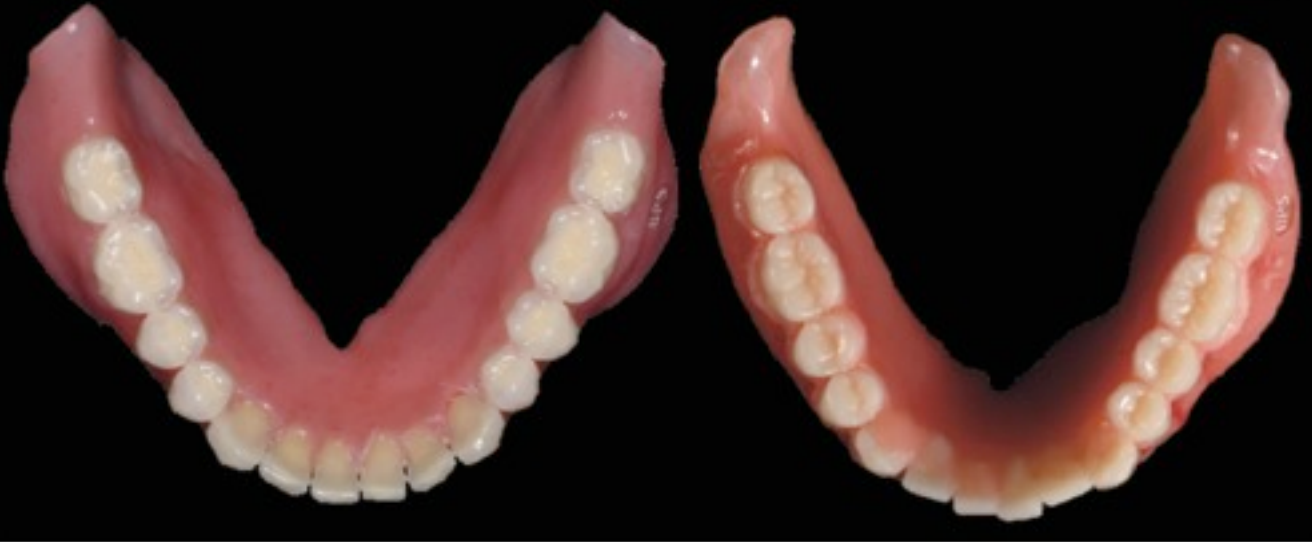

Fig.32 Conventional type denture (left: Orthosit denture teeth, Ivoclar Vivadent AG.) and suction effective denture (right: SR-Phonares denture teeth, Ivoclar Vivadent AG.)

Myostatic Outline of Accu-Dent System

Custom tray outline based on Myostatic Outline concept⁽¹³⁻¹⁸⁾

①: Cover the fibrous tissue rich 1/2 anterior to the retromolar pad. Effective for bearing the posterior part of denture and for preventing the denture sliding forward when occlusal chewing.

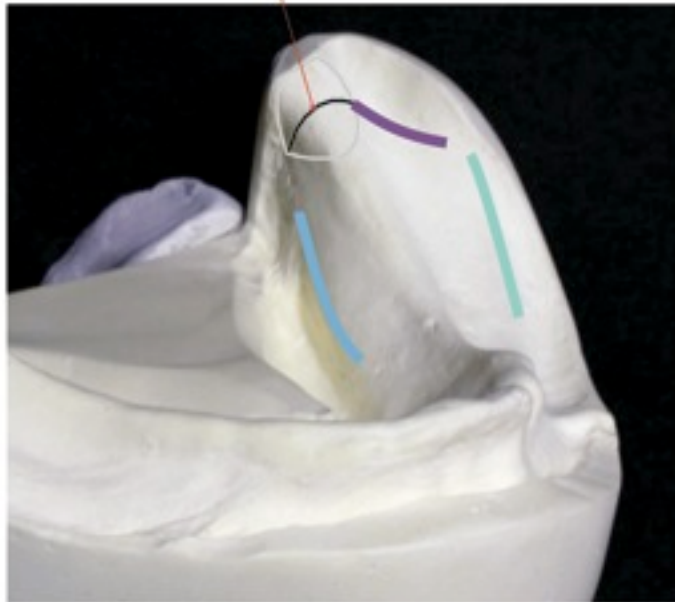


Fig.33

②: Avoid masseter muscle line. Masseter muscle will bulge strongly within when chewing. This masseter muscle will work toward denture dislodgement.

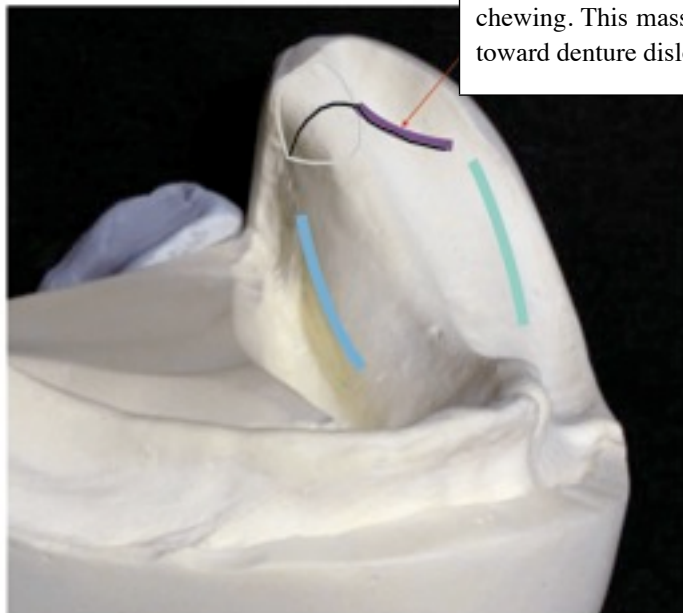
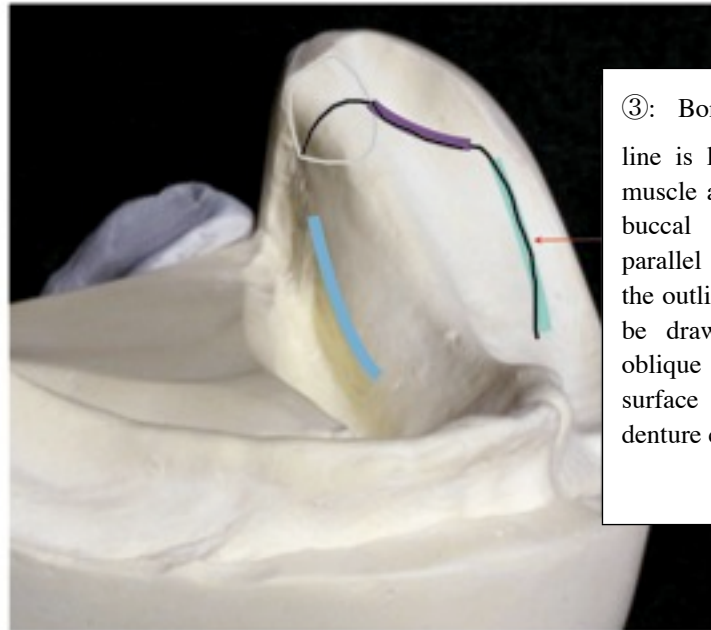


Fig.34

Myostatic Outline of Accu-Dent System, continued



③: Bony external oblique line is located at the buccal muscle attachment region. As buccal muscle fiber runs parallel to the alveolar ridge, the outline of custom tray can be drawn on or over this oblique line so that sufficient surface area of bearing denture can be obtained.

Fig.35

④: Mylohyoid line is where the mylohyoid muscle is attached. When the muscle is in tension, there is possibility of the underlying tissue movement of this line to work to dislodge a denture. And the space where a denture can be extended under the mylohyoid line (retromylohyoid fossa) is a natural space that has been present even before becoming edentulous. And so the denture extension to this area might influence adversely on movements of tongue and underlying tissues, and the custom tray outline should be set up on the mylohyoid

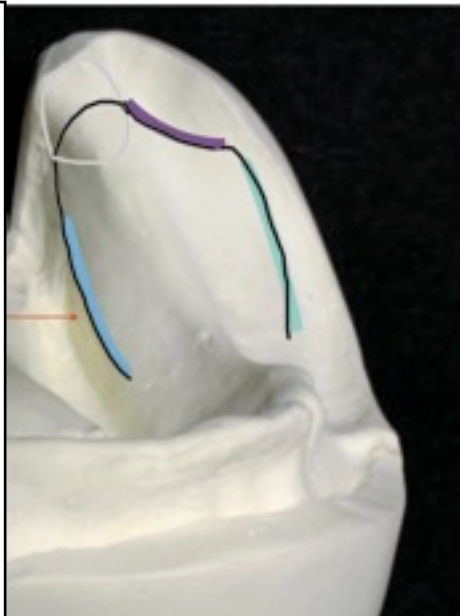
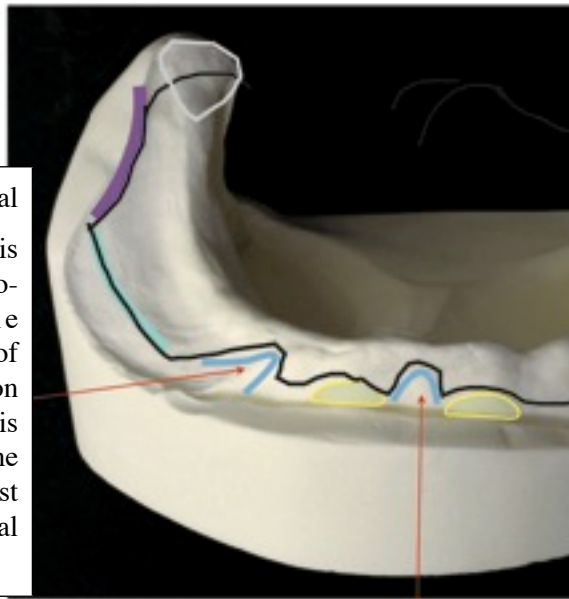


Fig.36

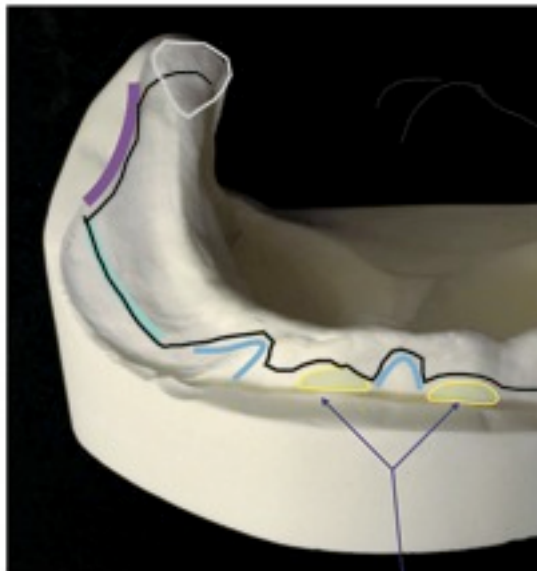
Myostatic Outline of Accu-Dent System, continued

⑤-1: Avoid buccal frenum. Buccal frenum is active toward postero-superiorly while working. Amount of activity depends on individuals, and so it is better to set up the outline to draw on a cast while observing the oral cavity.



⑤-2: Avoid median inferior labial frenum. This frenum is active up and down, and so it is better to set up the outline to draw on a cast while observing the oral cavity.

Fig.37



⑥: Avoid the mentalis muscle attachment. As the muscle is especially in tension while swallowing. And it is better to add the movement of swallowing while impression taking.

Fig.38

Myostatic Outline of Accu-Dent System, continued

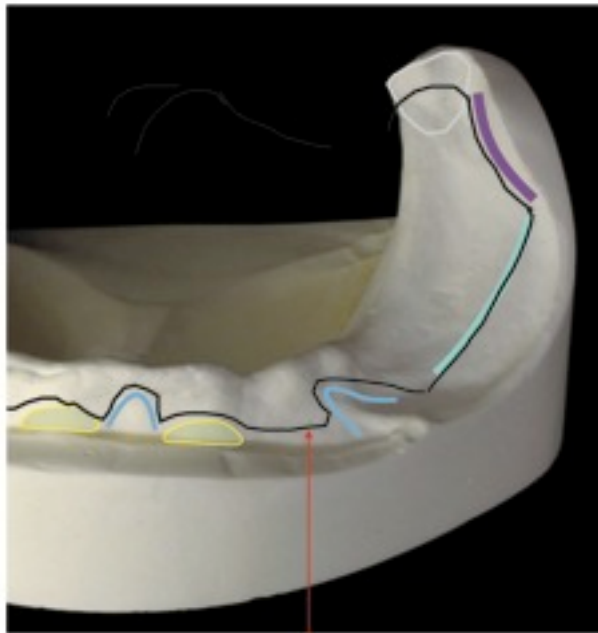


Fig.39

⑦: Assuming motions in the mucobuccal fold, set up the outline 2 mm beyond the mucobuccal fold.

⑧: Draw a line on the convexity and avoid the lingual frenum spaciouly.

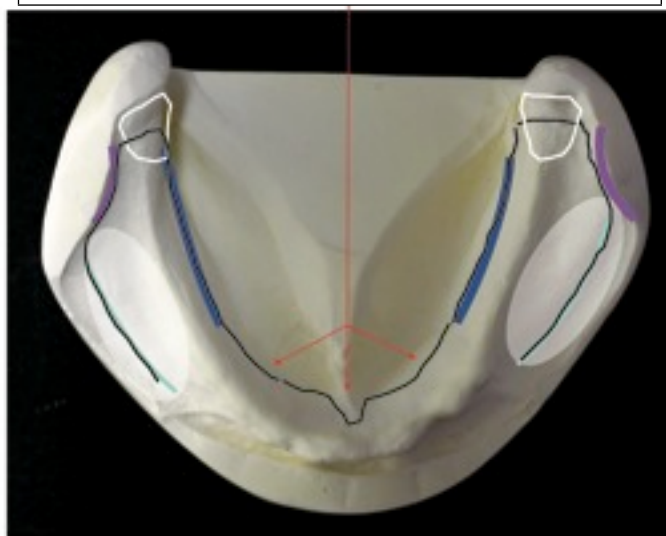
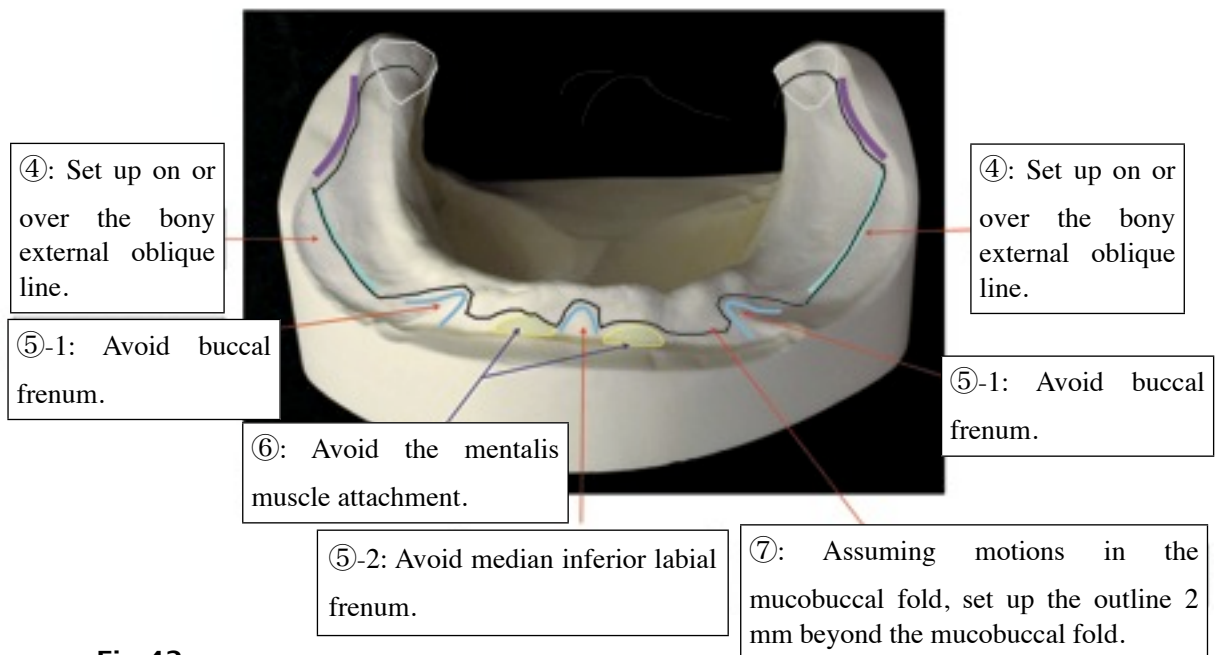
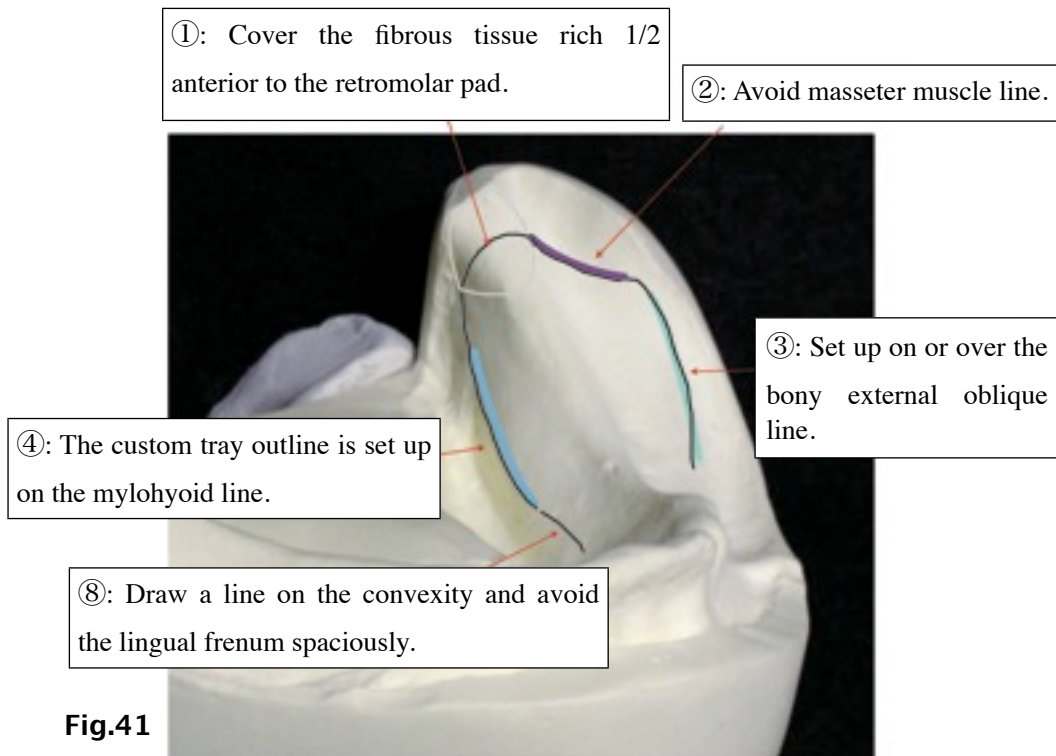


Fig.40

Myostatic Outline of Accu-Dent System, in summary



Myostatic Outline of Accu-Dent System, in summary

Custom tray outline set up with two combined ideas of covering the retromolar pad entirely and of extending into the retromylohyoid fossa through arranging the concept of Myostatic Outline.

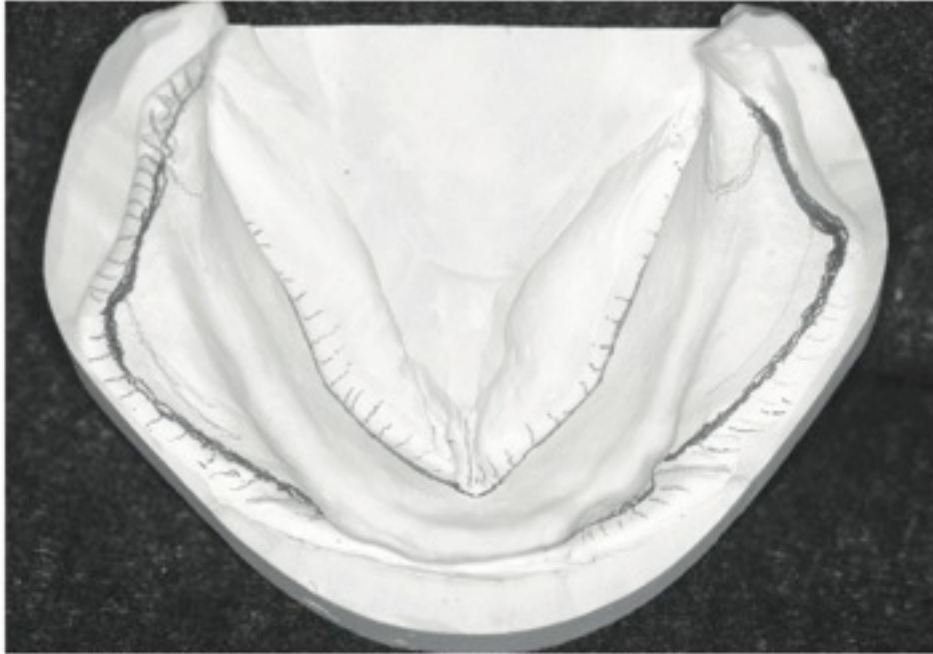

Fig.43 Outline drawn by Sato, K., Dental technician
(Sato Dental Laboratory, Nagoya, Japan)

Custom tray outline necessary for Suction denture based on FCB Tray System

Custom tray outline at the retromolar pad

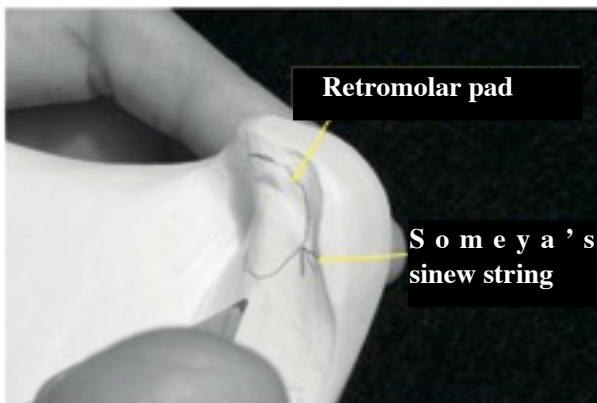


Fig.44 ① Draw identically to the shape of the retromolar pad. ② Avoid the Someya's sinew string¹⁹⁾ located at the base of retromolar pad.

Custom tray outline on the buccal side

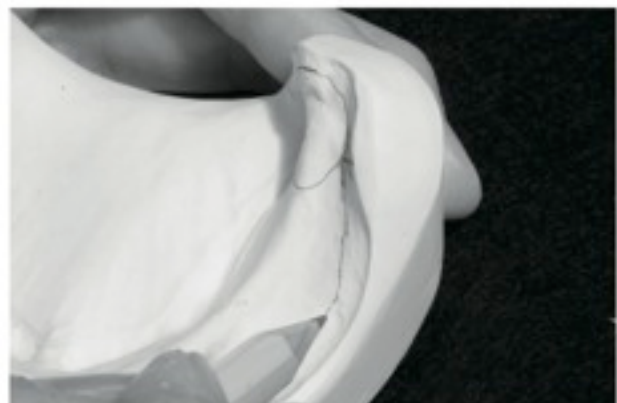


Fig.45 ③ Draw a line at the most inferior point of buccal shelf. In case the bony external oblique line is clearly defined in the impression by FCB Tray, the buccal border of custom tray is given in shape of peripheral roll.

Custom tray outline necessary for Suction denture based on FCB Tray System, continued

Custom tray outline setup in the retromylohyoid fossa and the sublingual fold

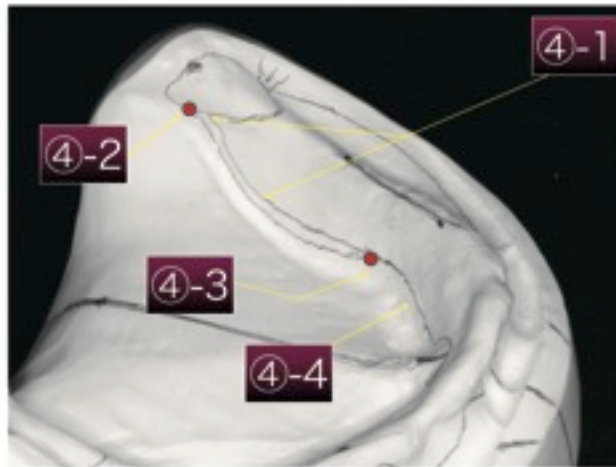
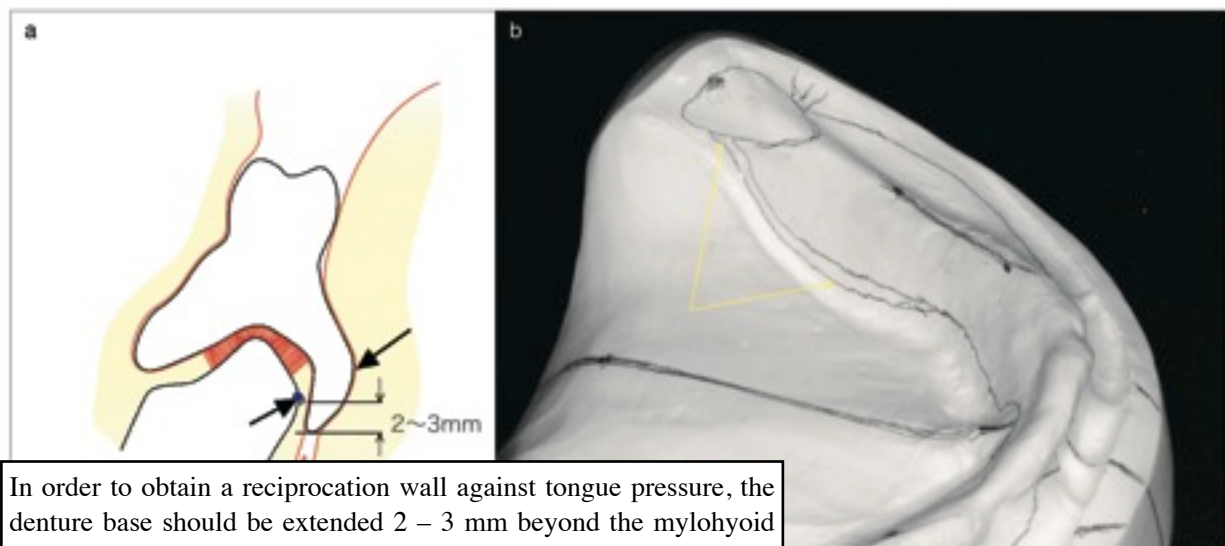


Fig.46

- ④-1: The mylohyoid line is in the direction about the center of lingual side of the retromolar pad.
- ④-2: Draw a line from about 2 mm posteriorly to the intersection of the mylohyoid line and the retromolar pad, and the line enters into the retromylohyoid fossa passing 2~3 mm beyond the mylohyoid line.
- ④-3: The line is then in the anterior direction to reach the inflection point of S curve.
- ④-4: Draw a line then anteriorly on the most convex surface to reach the lingual frenum.



In order to obtain a reciprocation wall against tongue pressure, the denture base should be extended 2 – 3 mm beyond the mylohyoid

Fig.47 Even if a preliminary impression takes a deep shape of the retromylohyoid fossa, it is still a static impression without any function of mylohyoid fossa. So in the phase of custom tray impression, all it needs is to attain a denture base closure with the tongue sidewall (compensatory closure). (a). Extension of minimum 2-3 mm is needed, and final length is determined by individual functional movements at the final precision impression (b).

Custom tray outline necessary for Suction denture based on FCB Tray System, continued

Custom tray outline setup in the labial side

⑤-2: Avoid median inferior labial frenum. This frenum is active up and down, and so it is better to set up the outline to draw on a cast while observing the oral cavity.

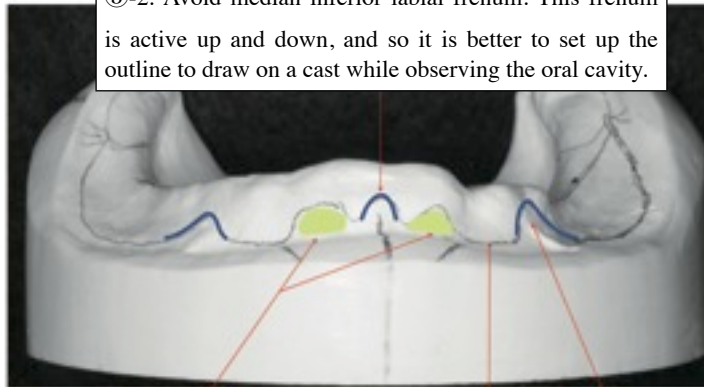


Fig.48

⑥: Avoid the mentalis muscle attachment. As the muscle is especially in tension while swallowing. And so it is better to include the swallowing movement while taking an impression.

⑦: Assuming motions in the mucobuccal fold, set up the outline 2 mm beyond the mucobuccal fold.

⑤-1: Avoid buccal frenum. Buccal frenum is active toward postero-superiorly while working. Amount of activity depends on individuals, and so it is better to set up the outline to draw on a cast while observing the oral cavity.

Custom tray outline setup in the preliminary impression with FCB Tray that has an advantage in effective suction of a mandibular complete denture

①: Draw identically to the shape of the retromolar pad.

④: Line enters into the retromylohyoid fossa passing 2~3 mm beyond the mylohyoid muscle line.

②: Avoid the Someya's sinew string.

⑧: Draw a line on the convexity and avoid the lingual frenum spaciouly.

③: Draw a line at the most inferior point of buccal shelf or inside the bony external oblique line.

⑤-1: Avoid buccal frenum.

⑥: Avoid the mentalis muscle attachment.

⑤-2: Avoid median inferior labial frenum.

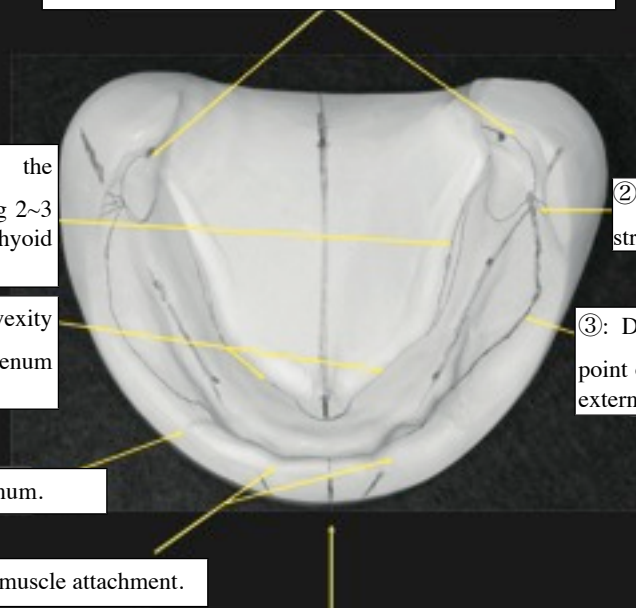


Fig.49

Reference

- 1) Abe J: Clinical practice of complete dentures - To attain the lower complete denture suction, J Nippon Dental Review 59(5):159-174, 59(6):125-139, 59(7): 141-157,1999 (Japanese)
- 2) Abe J: Lower Complete Denture Suction that Anyone Can Get, Hyoron Publ., Tokyo, 2004 (Japanese)
- 3) Abe J: Monthly Abe Jiro - A long way to lower complete denture suction, (J Dental Diamond, 2007) (Japanese)
- 4) Hasegawa,S., Sekita, T., Hayakawa,I.: Effect of denture adhesive on stability of complete dentures and the masticatory function, J.Med.Dent.Sci., 50(4): 239~247,2003
- 5) Sato, K.: Comparisons of masticatory movements while wearing complete mandibular dentures with and without suction in a totally edentulous subject, J the Japan Academy of Gnathology and Occlusion 28(4): 166-173, 2008 (Japanese)
- 6) Abe, J., Sato,K., Kokubo.K.: To become skilled at complete denture therapy teamwork - To achieve suction effect in mandibular complete denture, QDT, 33(1):13~42, 33 (2):48~57, 33(3):56~63, 33(4):44~55, 33(5):52~61, 33(6):36~46, 33(7):48~59, 33 (8):50~62,2008(Japanese)
- 7) Abe, J., Saito, Y., Sato, K., Nukazawa, S.: Symposium in a magazine - Challenges to attaining mandibular complete denture suction, J Nippon Dental Review 67 (10): 49~89,2007 (Japanese)
- 8) Abe, J., Saito, Y., Kokubo, K., Ohno, T.: Biteplate that reduces clinician's mistakes and impression custom tray that enables suction effect, G-C, 2007 (Japanese)
- 9) Carl, Boucher and Hickey., Judson, C., George, A.Zarb.: Prosthodontic treatment for edentulous patients, Mosby, 1970
- 10)Ohtomo, K.: Relationship between size of denture foundation and masticatory function in complete denture wearers, J. Japan Prosthodontic Society 40(6): 1194~1204, 1996 (Japanese)
- 11)Koshino,H., Hirai, T., Ishijima, T., Ohtomo, K.: Influence of mandibular residual ridge shape on masticatory efficiency in complete denture wearers, Int. J. Prosthodont., 15:295~298, 2002
- 12)Herbert, Frick., Abe, J.: BPS, Worldwide accepted complete denture construction system - Search for differences from complete denture therapy in Japan, J Dental Outlook 108(6):1101~1128, 2006 (Japanese)
- 13)Gray, H.: Anatomy of the human body, 28th ed. Lea & Febiger, 1966
- 14)Levin, B.: Impression for complete dentures, Quintessence, 1984
- 15)Nagao, M., Kobayashi, K., Suzuki, T.: Impression of edentulous patients, Ishiyaku Euro America, 1995
- 16)Mcminn, R.M.H., Hutchings, R.T., Logan, B.M.: color atlas of head and neck anatomy, 2nd ed. Mosby, 1994
- 17)Schreinemarkers, J.: La logique en prothèse complète, G.J. & D. Tholen NV, 1964
- 18)Sicher, H.: Oral anatomy, 4th ed. Mosby, 1965
- 19)Someya, S.: Report on sinews observed around distal region of lower second molar tooth and anterior border of the retromolar pad, J the Japan Academy of Gnathology and Occlusion 28(1/2): 14~20, 2008 (Japanese)

