

Guidelines for the use of L-PRF

Leucocytes and Platelet Rich Fibrin
in Different Intra-oral Applications
Applying the IntraSpin™ Concept

Flow Charts: Step by Step Approach

**Nelson R. Pinto¹, Andy Temmerman², Ana B. Castro²,
Simone Cortellini², Wim Teughels², & Marc Quirynen²**

*1: University of the Andes, Department of Periodontics and Implant
Dentistry, Faculty of Dentistry, Santiago, Chile*

*2: Catholic University of Leuven / University Hospitals Leuven, Department
of Oral Health Sciences, Periodontology, Leuven, Belgium*

Guidelines for the use of L-PRF

Leucocytes and Platelet Rich Fibrin
in Different Intra-oral Applications
Applying the IntraSpin™ Concept



Universidad de
los Andes

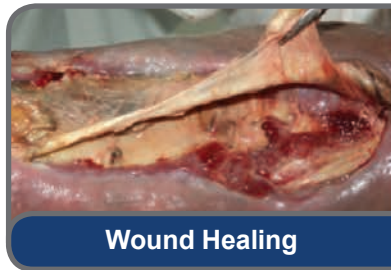KU LEUVEN

Flow Charts: Step by Step Approach

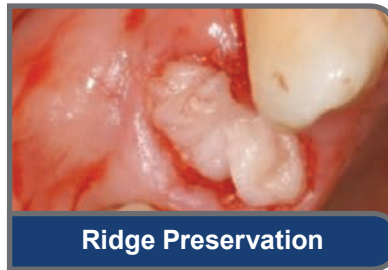Favorable wound healing has always been a major quest in dental surgery. It is a concern in healthy as well as compromised patients. In an effort to improve and accelerate healing of both hard and soft tissues, substitutes including growth factors and bio-materials have been traditionally employed. Membranes were also introduced to separate tissues.

Recent research clearly indicates that L-PRF (Leukocyte -Platelet Rich Fibrin, a second generation of platelet concentrates) significantly enhances wound healing in both soft and hard tissues. Evidence now supports the assertion that this has the potential to replace the above mentioned substitutes in many situations.

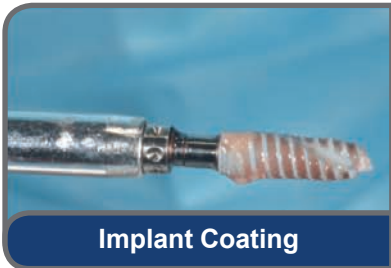Clinical procedures benefit from recent advancements with platelet concentrate protocols including, but not limited to: soft tissue healing, plastic periodontal surgery, gingiva enlargement, MRONJ, regeneration of infra-bony defects, ridge preservation, sinus augmentation, immediate implant placement and implant osseointegration itself. An added benefit is that these platelet concentrate protocols offer significantly lower cost treatment solutions to our patients, due to the fact of their ease of use and inexpensive preparation.



Wound Healing



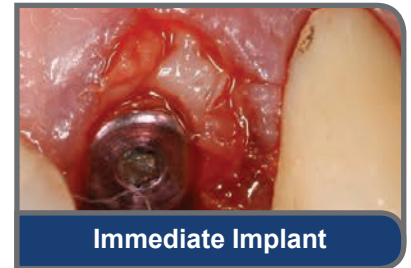
Ridge Preservation



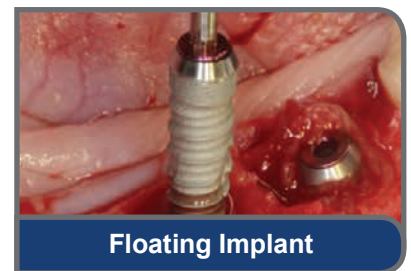
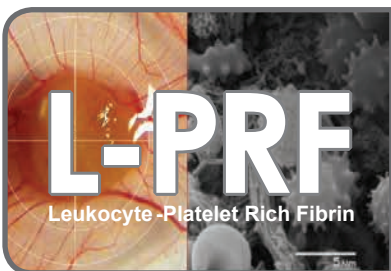Implant Coating

Our basic knowledge of the biologic mechanisms of both soft and hard tissue healing has increased exponentially in recent years. Advancements in autologous platelet concentrate protocols, profoundly impact the way we treat patients today.

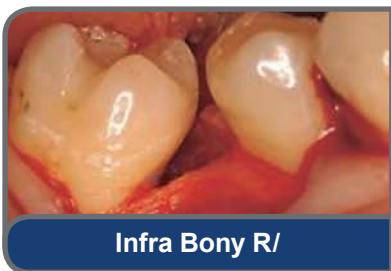Thanks to these advancements we can now introduce a new level of treatment options to our daily practice...from periodontal procedures to regeneration of bone defects and even implant osseointegration itself.



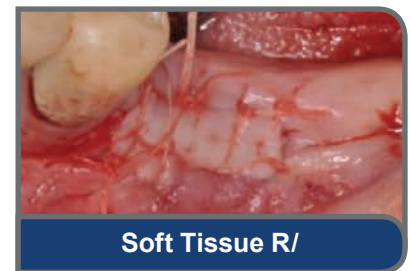
Immediate Implant



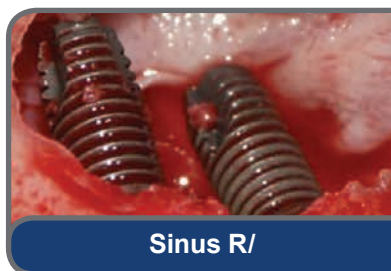Floating Implant



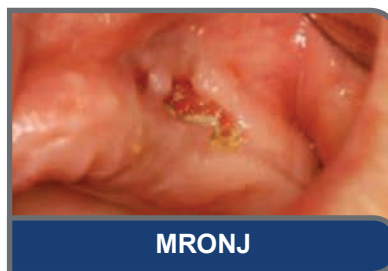Infra Bony R/



Soft Tissue R/



Sinus R/



MRONJ

Figure 1: Major indications for use of L-PRF.

Flow Chart One

Step by step approach for the preparation of L-PRF (simple chair-side procedure)

Protocol for preparation of L-PRF clots:


- Venipuncture: With a 21G butterfly needle collect up to 8 9ml red cap tubes of blood.
- After the first two tubes of blood are collected, immediately place them into the IntraSpin™ centrifuge, opposite to each other to ensure the centrifuge is properly balanced. Close the cover and set the timer to “1” minute. Press START and allow the centrifuge to run for one minute, after one minute the centrifuge will come to a full stop and the cover will pop open. While it is spinning for 1 minute collect the third and fourth tubes of blood from patient, and repeat procedure for the other tubes.
- Centrifugation should be at 408g (2700 rpm using the IntraSpin™ centrifuge, for at least 12 minutes (start timing after loading the centrifuge with last 2 tubes).
- After ≥ 12 minutes centrifugation (for patient taking anti-coagulant medication up to 18 minutes are recommended) L-PRF clots are ready.
- Take the fibrin clots out of the tubes and separate them from the red blood cells.

Protocol for preparation of L-PRF membranes:

- Place fibrin clots in Xpression™ box for gentle compression by gravity (e.g. with light metal plate, Figure 2).
- 5 minutes later the L-PRF membranes are ready for use.
- 2.5 to 3 hours is the viability for expressed membranes, as long as they are re-hydrated with exudate.

Protocol for preparation of L-PRF plugs:

- Place fibrin clots in the small white cylinder of the Xpression™ box.
- Use the piston to carefully compress the clot, until holder is level to cylinder.
- 2.5 to 3 hours is the viability for expressed plugs, as long as they are re-hydrated with exudate.



Flow Chart One

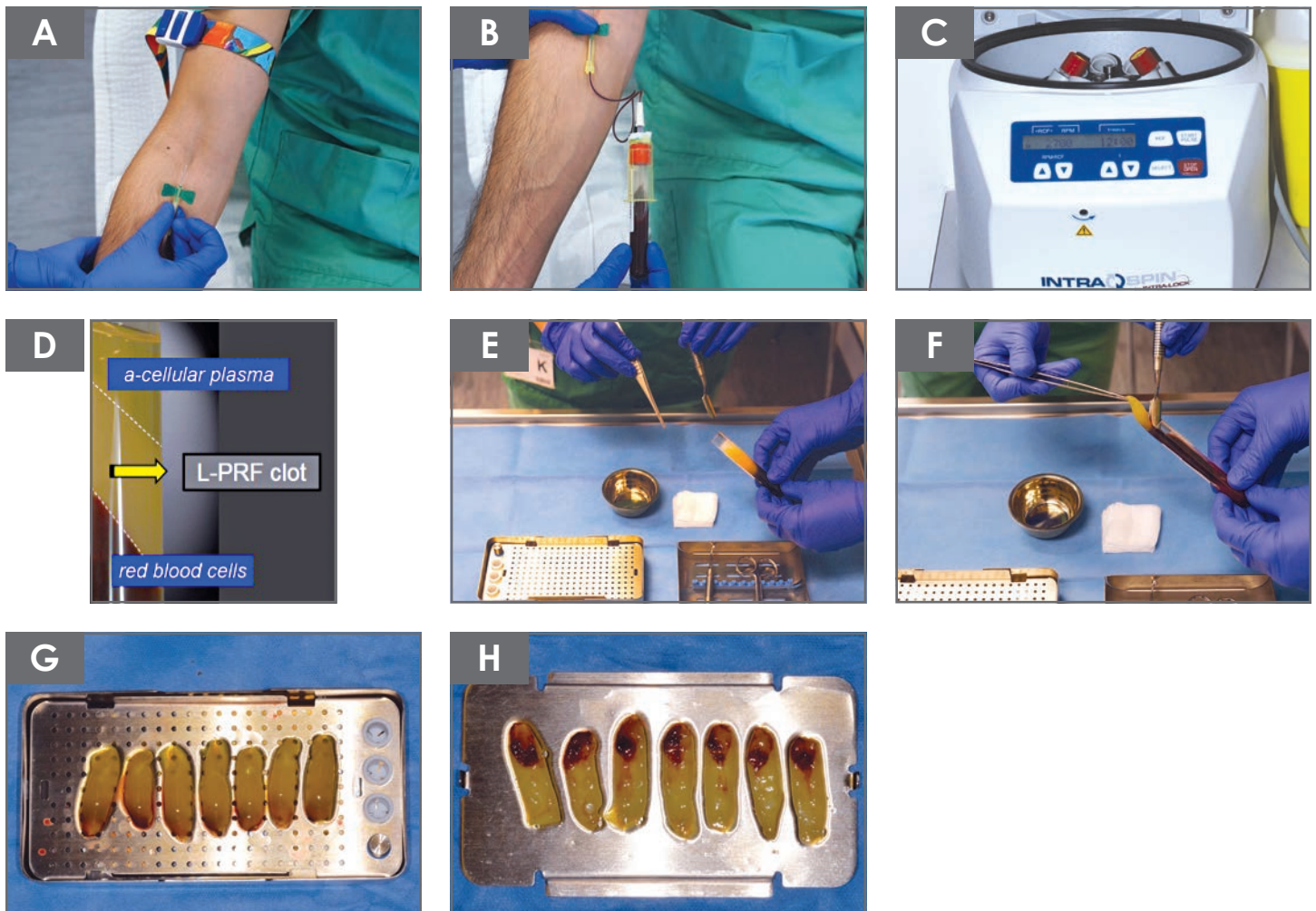


Figure 3:

Process of preparing L-PRF clots and membranes.

A&B: Venipuncture and blood collection using 21G butterfly needle and 9 ml red cap tubes.

C: Centrifugation at 408g RCF, (2700 rpm) with IntraSpin™ centrifuge.

D: L-PRF clot in tube; clear separation: red blood corpuscles (RBCs) at the bottom, PPP (platelet poor plasma) on the top, and L-PRF fibrin clot in the middle.

E&F: Remove clot from tube and separate clot from red blood cells.

G: Specially designed kit (Xpression™ box) to compress L-PRF clots into L-PRF membranes with a consistent thickness of 1 mm. A piston and cylinder assembly (right site) can be used for the creation of L-PRF plugs, suitable for filling extraction sockets.

H: L-PRF membranes after gentle compression; the red area of the membrane represents the face side, where most leucocytes, platelets and stem cells are concentrated.

Flow Chart **Two**

Step by step approach for the use of L-PRF during open flap debridement.

Protocol for L-PRF as sole biomaterial for intra-bony defect regeneration during open flap debridement:

- Intra-sulcular incision with maximal preservation of gingival complex.
- Minimal flap elevation and degranulation of intra-bony defects.
- Optimal root planing.
- Rinse defect with L-PRF exudate (collected at the bottom of the Xpression™ box after compressing the clot).
- Apply L-PRF membrane (or part of it) in the defect (preferably the face part of the membrane towards bone).
- Coverage of bony defect with ≥ 2 layers of L-PRF membranes, running ≥ 2 mm over the bony borders underneath the periosteum, in order to seal the socket and to force the soft tissues to grow over, instead of, underneath the membranes.
- Suture flap and try to provide primary closure of the interdental papilla, in the absence of tension.

Post-operative care:

- Soft food intake, do not bite/chew in treated area, no mechanical cleaning of the treated area.
- 0.12% Chlorhexidine twice a day for 1 min. for at least 3 weeks.
- Painkillers.

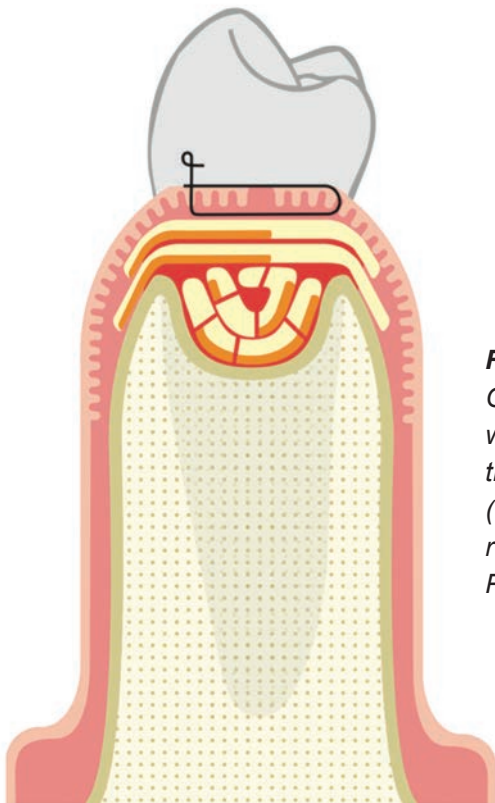


Figure 4:

Graphic representation of an intra-bony defect filled with chopped L-PRF membrane parts (preferably the face part) and covered with L-PRF membranes (≥ 2 layers with face side towards bony defect, and running over the buccal and lingual bony borders). Primary closure is not mandatory.

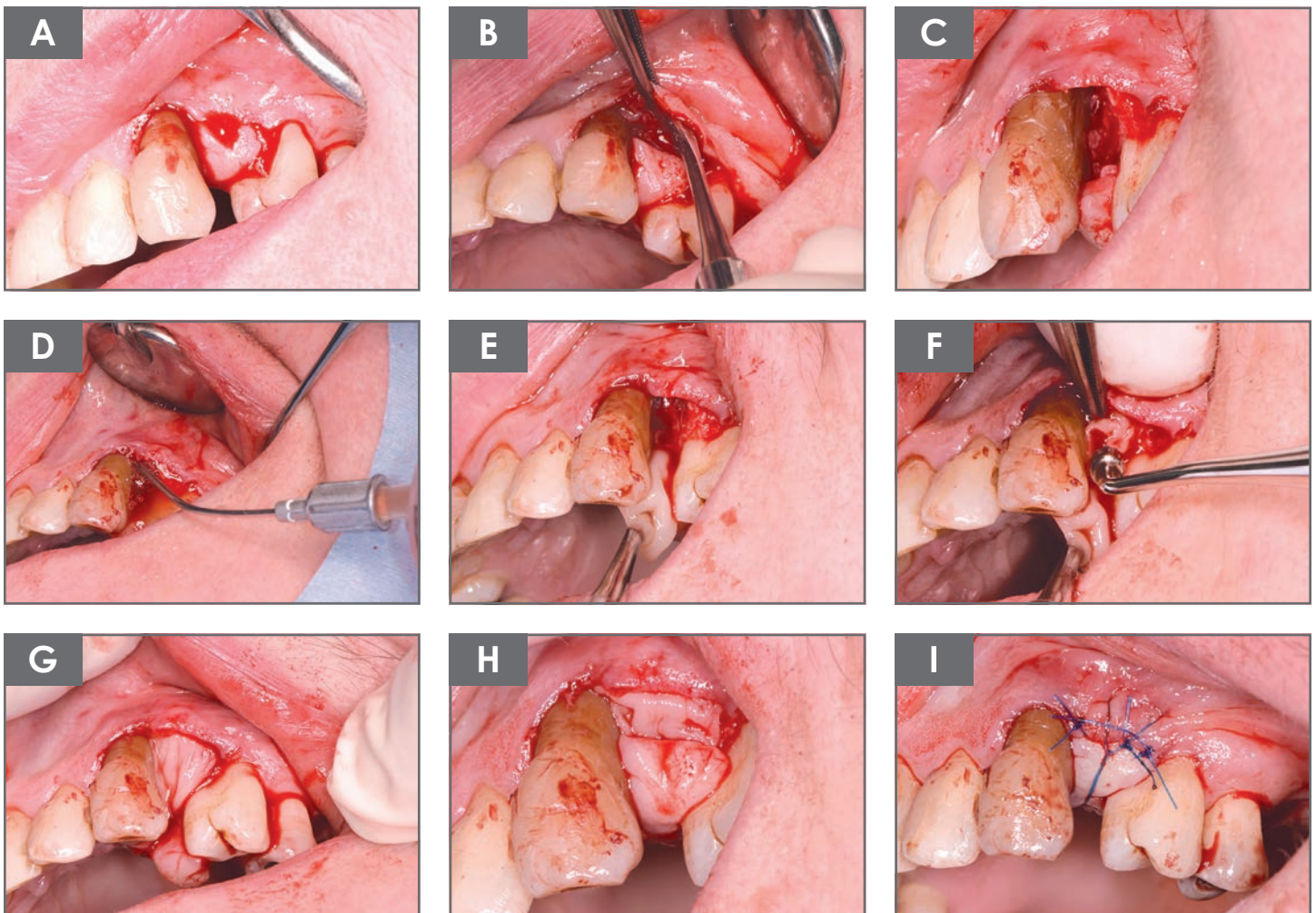
Flow Chart **Two**

Figure 5:

Regenerative treatment of intra-bony defects with L-PRF.

- A:** Intra-sulcular incision with papilla preservation.
- B:** Minimal flap elevation (palatally pediculated).
- C:** Defect after rootplaning.
- D:** Rinsing intra-bony defect with LPRF exudate.
- E&F:** Application of chopped L-PRF membranes in the defect (preferably face side).
- G&H:** Coverage of bony defect with ≥ 2 layers of L-PRF membranes.
- I:** Flap suturing, preferably with primary closure of the interdental papilla, in the absence of tension.

Flow Chart Three

Step by step approach for ridge preservation with L-PRF

Protocol for ridge preservation with L-PRF:

- A-traumatic tooth extraction with maximal preservation of alveolar bone.
- Accurate removal of inflammation and granulation tissue (if needed with bur).
- Preparation of envelope (circa 2 mm in width) between bony borders of socket and surrounding soft tissues. Insert part of the L-PRF membranes between periosteum and bony walls, in order to seal the socket and to force the soft tissues to grow over, instead of, underneath the membranes.
- If applicable use L-PRF exudate (aspirated in sterile syringe), obtained after compression of clots; to irrigate and clean the socket.
- Place the L-PRF plugs / membranes (\pm 3-5 plugs) in the socket one by one, compress vigorously with the amalgam condensor and absorb superfluous serum with a gauze.
- Cover the socket with at least a double layer of L-PRF membranes and slide their margins between soft and hard tissues around the socket (envelope) to seal the socket and to prevent epithelial infiltration.
- Suture with, for example, a modified internal mattress or external mattress technique, not with the intention to close the wound, but to keep the membranes in place without traction. Sutures have to be supported by alveolar bone in order to prevent L-PRF from being pushed out.

Post-operative care:

- No use of chlorhexidine during first 2 days, in order not to disturb initial soft tissue healing.

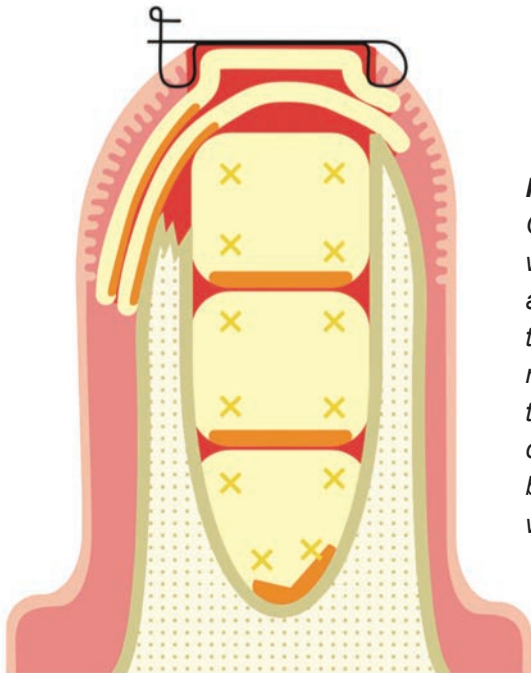


Figure 6:

Graphic representation of an extraction socket filled with L-PRF. Several L-PRF plugs/membranes (\geq 3) are condensed at the bottom (face towards bone), the socket is sealed with at least 2 layers of L-PRF membranes. These membranes are slid under the periosteum at the bony socket borders (in the created envelope between periosteum and bony borders, 2mm coverage is sufficient). Suturing without any attempt to close the wound.

Flow Chart Three

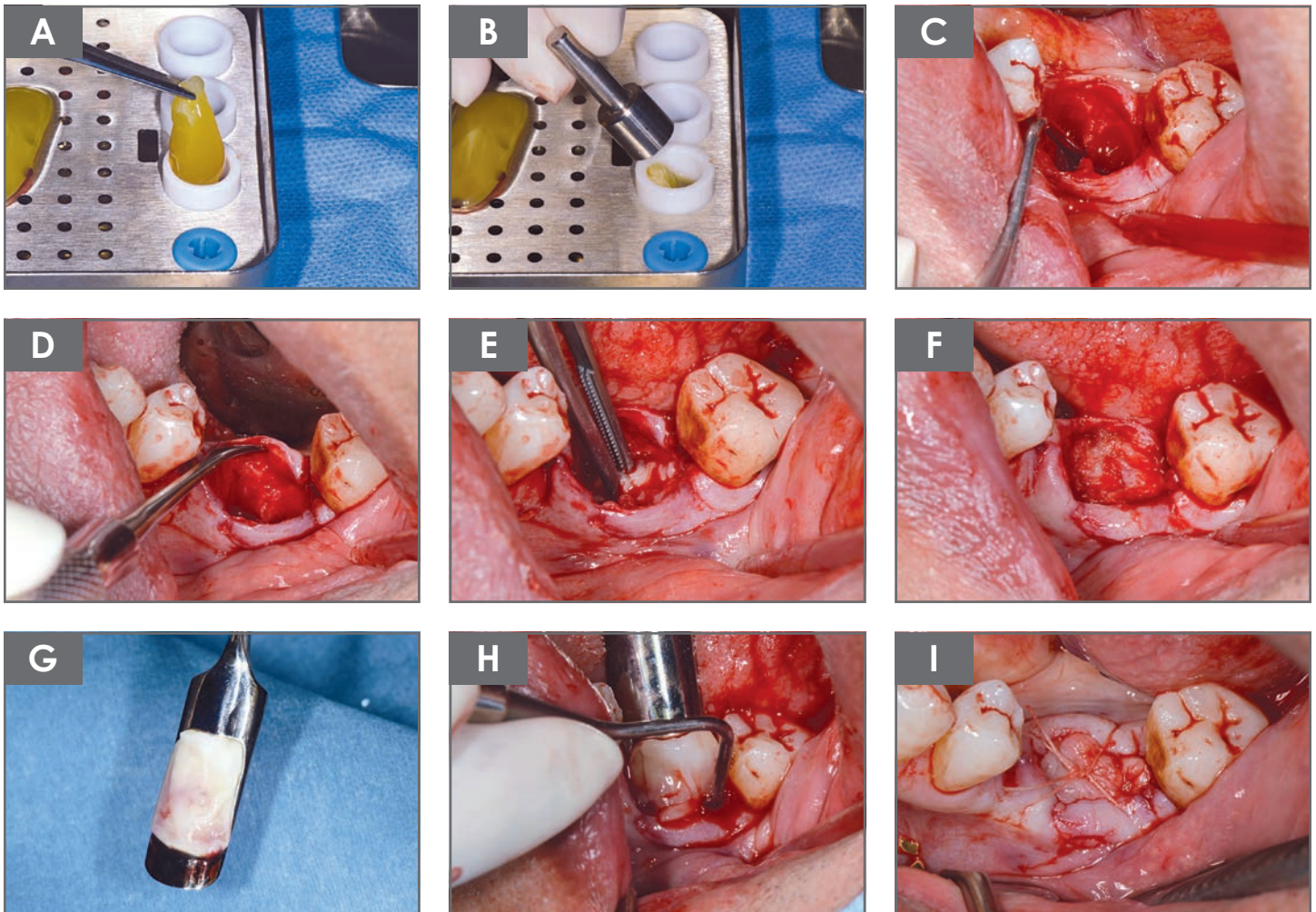


Figure 7:

The use of L-PRF as a filling material of a tooth socket aiming to maintain the alveolar bone dimensions.

A&B: preparation of L-PRF plugs with Xpression™ kit.

C: accurate removal of “all” inflammation and granulation tissue.

D: preparation of envelope (circa 2 mm in width) between bony borders of socket and surrounding soft tissues (this is needed to slide in the L-PRF membranes at the end, in order to prevent the fast ingrowth of connective tissue and to force the epithelium to grow over the membranes).

E&F: placement, one by one, of the L-PRF plugs (\pm 3-5 plugs) / membranes in the socket and vigorous compression.

G&H: coverage of socket with at least a double layer of L-PRF membranes (slide borders of membranes into prepared envelope).

I: tension free suturing with, for example, a modified internal mattress or external mattress technique, primary closure is not mandatory.

Flow Chart Four

Step by step approach for sinus floor elevation via a lateral window technique and L-PRF.

Protocol for lateral-window technique and simultaneous implant placement using L-PRF as sole grating material:

- Crestal incision (and one or two releasing incisions).
- Reflection of the flap far enough apically and distally to have a clear view.
- Preparation of lateral window with piezo-ultrasonic instruments (or with a ball drill) (check on CBCT for potential arteries in lateral sinus wall).
- Meticulous elevation of the Schneiderian membrane, the bony window can be pushed inside (prevent sharp edges), or can be removed.
- Once the membrane is elevated, the implant osteotomy site can be prepared.
- After careful preparation of the osteotomy but before implant placement, L-PRF membranes should be placed covering the Schneiderian membrane; make sure that at least 3 layers of L-PRF (preferably 2 double folded layers) are covering the Schneiderian membrane in the area where the apices of the future implants will be located.
- Place some membranes against the palatal/mesial/distal walls of the uncovered sinus.
- Insert implant(s).
- Add extra L-PRF membranes around the implants in the sinus and buccally.
- Cover the window with at least 2 layers of L-PRF membranes (L-PRF face towards sinus).
- Close flap without moving the L-PRF membranes.
- Suture with monofilamentous non-resorbable sutures.

Post-operative care:

- No flying, diving, wind instruments for at least 6 weeks.
- Prevent forceful sneezing for at least 6 weeks.
- Prescribe sufficient painkillers, systemic antibiotics, a nose spray and corticosteroids (the latter for e.g. 3 days) if needed.
- After 4-6 months of healing, the abutment can be placed and loaded if the implant is well integrated.

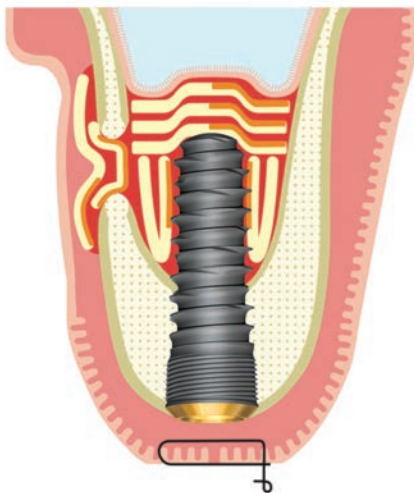

Figure 8:

Graphic representation of the final situation after a lateral window approach with immediate implant placement using L-PRF as only substitute. Several L-PRF membrane layers (≥ 3) cover the Schneiderian membrane (face towards membrane) above the apex of the implant and fill the implant site. Also the space between the implant and bony walls of the augmented sinus are filled with membranes (often ≥ 3). Finally the window is sealed with at least 2 layers of L-PRF membranes.

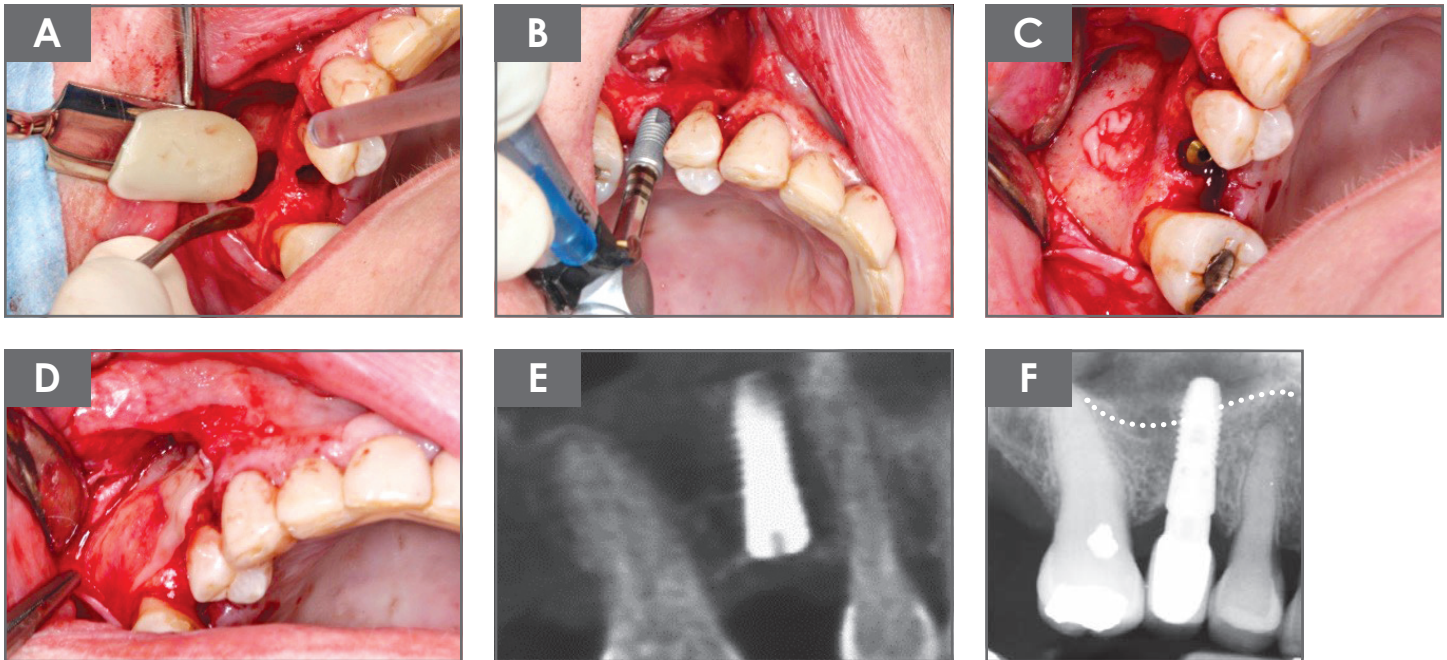
Flow Chart **Four**

Figure 9:

Sinus floor elevation via a lateral-window technique, with simultaneous implant placement using L-PRF as “sole” grafting material.

- A:** After careful preparation of the osteotomy, L-PRF membranes are placed to cover the Schneiderian membrane (≥ 3 layers) and the area to augment, especially palatally, since this area becomes difficult to reach after implant insertion.
- B:** Implant placement.
- C:** Additional L-PRF membranes placed around the implant.
- D:** Window coverage with ≥ 2 layers of L-PRF membranes.
- E:** CBCT immediately after surgery.
- F:** X-ray after 1-year (dotted line represents initial position of the sinus floor).

Flow Chart Five

Step by step approach for sinus floor elevation via trans-alveolar technique and L-PRF.

Protocol for trans-alveolar sinus floor elevation simultaneous with implant placement using LPRF as sole grafting material:

- Crestal incision and one (or two) releasing incisions.
- Reflection of full thickness flap to expose crestal bone.
- Osteotomy preparation up to 1mm away of the Schneiderian membrane (different techniques can be used including piezo).
- Placement of L-PRF membrane in osteotomy (act as a cushion for next step).
- Fracture carefully remaining floor of the sinus with osteotomes.
- Elevate Schneiderian membrane by carefully inserting several L-PRF membranes (one at the time) into sinus via osteotomy with the use of osteotomes.
- Make sure that at least 4 membranes of L-PRF are placed in the sinus.
- Insert implant(s).
- Suturing with monofilamentous non-resorbable sutures.

Post-operative care:

- No flying, diving, air instruments for at least 6 weeks.
- Prevent forceful sneezing for at least 6 weeks.
- Prescribe sufficient painkillers, systemic antibiotics, a nose spray and corticosteroids (the latter for e.g. 3 days) if needed.
- After 4-6 months of healing, the abutment can be placed and loaded if the implant is well integrated.

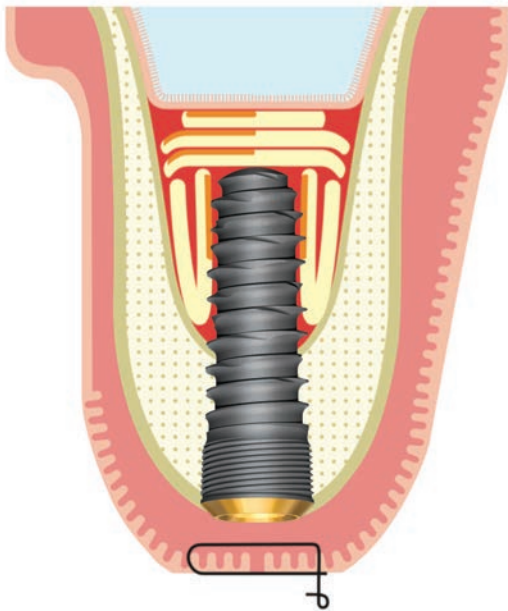


Figure 10:

Graphic representation of the final situation after a trans-alveolar approach for sinus augmentation. Several L-PRF membranes (preferably ≥ 3 layers) separate the Schneiderian membrane from the apex of the implant, and fill the space between implant and augmented sinus (often ≥ 4 membranes are needed for a single implant).

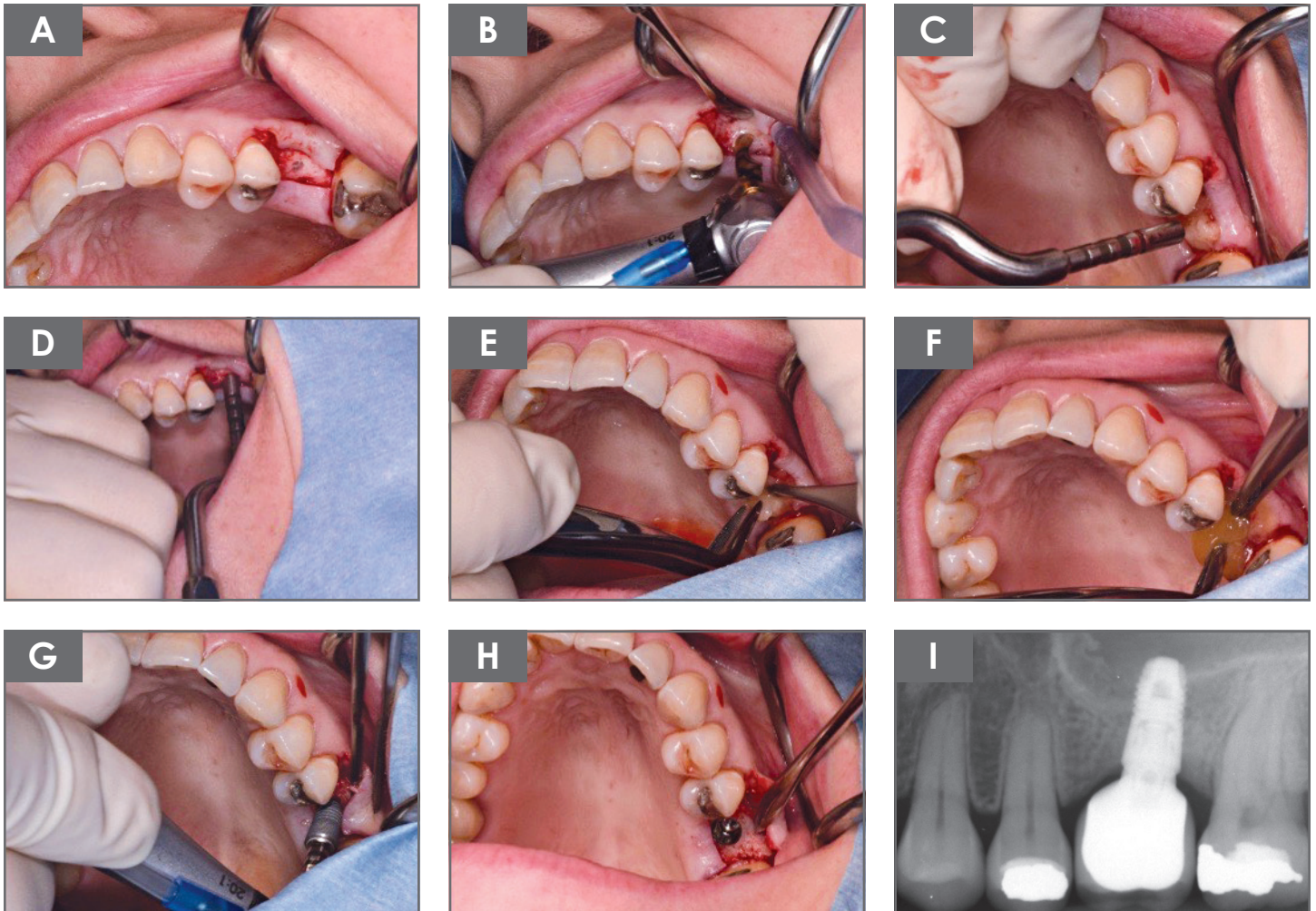
Flow Chart **Five**

Figure 11:

Sinus floor elevation via trans-alveolar approach using L-PRF as “sole” grafting material.

A&B: osteotomy preparation up to 1mm away of the Schneiderian membrane.

C: placement of 1 L-PRF membrane in osteotomy (act as a cushion for osteotomes).

D: fracturing of remaining floor of the sinus with osteotome.

E&F: elevation of Schneiderian membrane by inserting several (≥ 3) L-PRF membranes.

G&H: implant placement.

I: x-ray after 1-year.

Flow Chart Six

Step by step approach for implant coating with L-PRF.

Implant coating with L-PRF:

- Prepare implant osteotomy according to the required implant protocol.
- Use L-PRF exudate, obtained after compression of L-PRF clots, to irrigate and clean the osteotomy.
- Position the implant on the implant driver.

Option 1:

- Place a L-PRF clot in a small titanium dish.
- Let the implant slowly rotate in the clot while adding a little pressure against the wall of the dish until the L-PRF is fully wrapped around the implant.
- Insert implant in osteotomy.

Option 2:

- Place the implant in contact with the L-PRF membrane.
- Let the implant rotate slowly and wrap the L-PRF membrane around it with the L-PRF face at the outside part.
- Insert implant in osteotomy.

Option 3:

- Place the L-PRF membrane in contact with the implant
- Let the implant rotate slowly until the entire implant surface has been in contact with the membrane, remnants of the L-PRF membrane become visible on implant surface.
- Place the face part of a membrane in the osteotomy.
- Insert implant in osteotomy.

Or:

- Collect the L-PRF exudate with a sterile syringe after compression of the clots.
- Rinse the implant surface with the L-PRF exudate before insertion.
- Place the face part of a membrane osteotomy.
- Insert implant in osteotomy.

Flow Chart Six

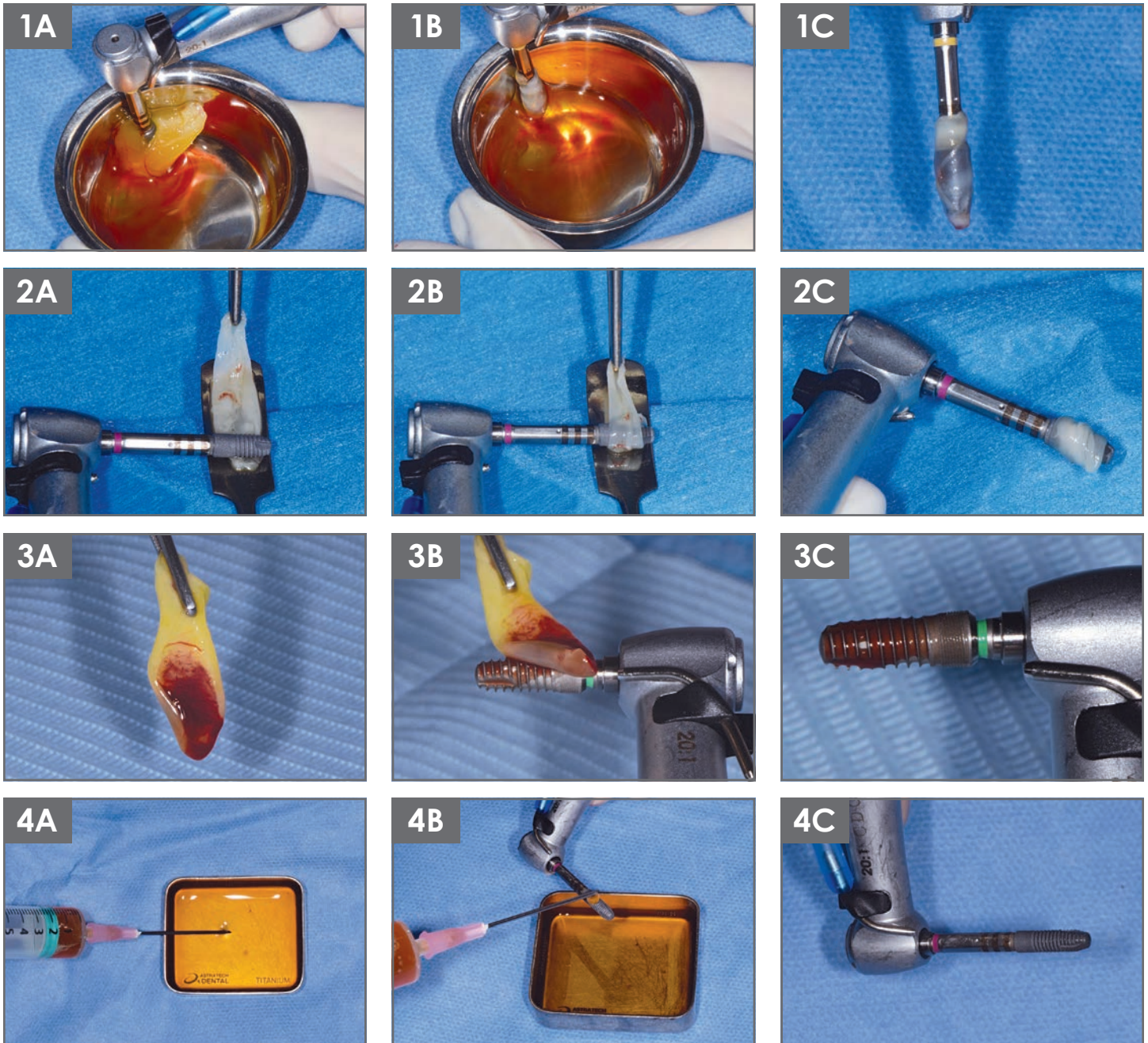


Figure 12: Different techniques to coat an implant with L-PRF before insertion.

1A: Placement of implant against a L-PRF “clot” in a small Ti-dish.

1B&1C: Slow rotation of implant in contact with the clot while adding a little pressure against the wall of the Ti-dish, the implant is wrapped in L-PRF.

2A: Placement of the L-PRF “membrane” (carried by a Ti-spatula), in contact with the implant.

2B&2C: L-PRF membrane wrapped around the implant (via slow rotation) with the L-PRF face at the outside part.

3A: Placement of the L-PRF membrane in contact with the implant.

3B&3C: Slow rotation of the implant in contact with the membrane

4A: Collecting L-PRF exudate.

4B&4C: Rinsing the implant surface with the L-PRF exudate just before insertion.

Flow Chart Seven

Step by step approach for gingival recession coverage.

Protocol for gingival recession coverage with a Coronal Advanced Flap (CAF) procedure with use of L-PRF as graft material:

- Incision following CAF protocol and Full-Split-Full thickness preparation of receptor bed
- De-epithelialisation of papilla.
- Suture minimal 2/3 L-PRF membranes (with correct dimension) together with resorbable 6-0 sutures.
- Place L-PRF graft on exposed connective tissue (receptor bed) and over the recession and suture it to the periosteum.
- Suture with a coronally advancement of the flap for coverage of the graft.

Post-operative care:

- No pressure or forces on the graft site for at least 6 months.
- Soft food intake, do not bite/chew in treated area. No mechanical cleaning of the treated area. Moderate use of the mouth. Chlorhexidine 0.12% (from day 3) 3 times per day for 1 min. for at least 3 weeks.
- Prescribe sufficient painkillers.

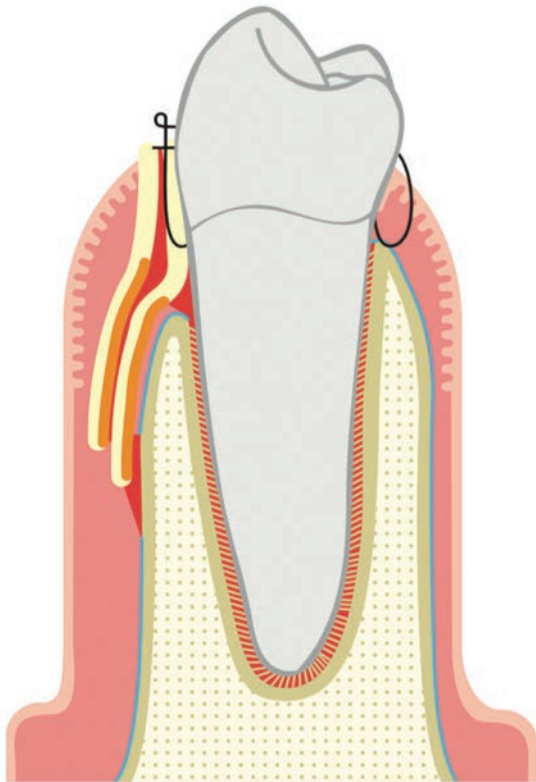


Figure 13:

Graphic representation of the final situation after gingival recession coverage with CAF and L-PRF membranes. Several L-PRF membranes (≥ 3) are placed on the receptor bed and over the recession. Suture to coronally advance the flap over the recession. (The periosteum, blue line, has been cut in order to enable coronal advancement of the flap).

Flow Chart Seven

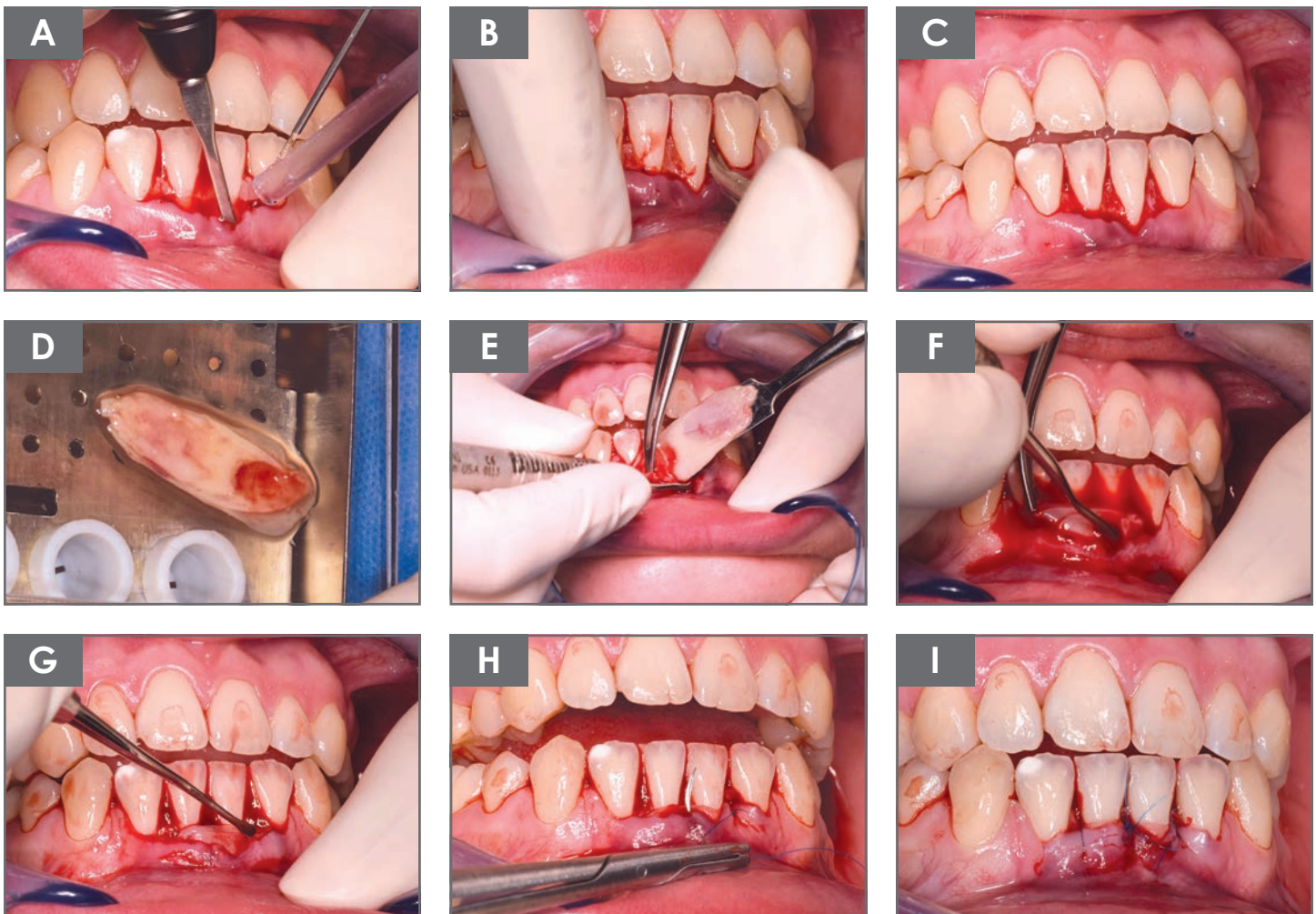


Figure 14:

Gingival recession coverage with Coronal Advanced Flap procedure and L-PRF membranes.

A: Split thickness preparation of receptor site.

B&C: De-epithelialisation of papillae.

D: Fix/glue $\geq 2/3$ L-PRF membranes (with dimensions of receptor bed) together.

E&F&G: Place L-PRF graft on exposed connective tissue (receptor bed) and over the recession.

H&I: Suture with a coronal advancement of the flap for coverage of the graft.

Flow Chart **Eight**

Step by step approach for the preparation of L-PRF block.

Protocol for preparation of PRF block™ using 0.5g of biomaterial of your choice, (allogenic or xenogenic or synthetic biomaterial):

- Venipuncture: Collect 6 tubes (9 ml red cap tubes) of blood following the L-PRF standard protocol and 2 tubes (9 ml white cap tubes), the latter is drawn last and placed last in the centrifuge (2700 rpm/408 RCF).
- Interrupt centrifugation after 3 min, remove both white cap tubes.
- Immediately restart the centrifuge with remaining red cap tubes for another 9 min.
- Immediately aspirate the yellow fluid (= liquid fibrinogen) in white cap tube with a sterile syringe, get as close as possible to the red cells, but do not aspirate them; use a plastic 5 cc sterile syringe with 21G needle and keep the liquid in that syringe with cover lid on.
- After full centrifugation of the remaining tubes, remove L-PRF clots and compress gently into membranes.

Preparation of “block”

- Chop 2 membranes in very small pieces with surgical curve scissors.
- Mix chopped membranes and bone substitute in Ti-dish (ratio: ± 2 membranes / 0,5g biomaterial), if the mix is too dry, one can add some L-PRF exudate from the Xpression™ box. Get a uniform mix.
- Add 1cc of liquid fibrinogen over the homogeneous mix, and stir gently for ± 5 to 10 seconds while shaping it to the desired form.
- Fibrinogen will clot into fibrin within a few minutes and trap the biomaterial to form a PRF block™. A variation would consist of molding the mix biomaterial / L-PRF membranes into the surgical defect and squirt the fibrinogen rich liquid onto it, it will form the block in-situ, but the liquid can only penetrate ± 5 mm deep into the mix.

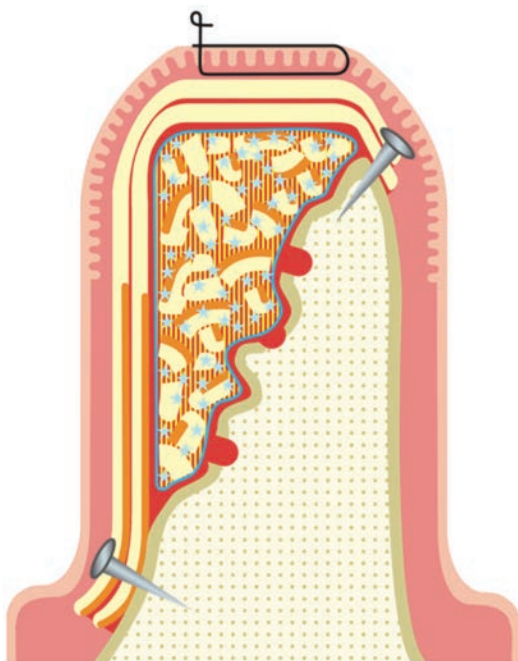


Figure 15:

Graphic representation of L-PRF block for horizontal bone augmentation. The small holes in cortical bone guarantee an optimal blood supply. The L-PRF block is quite well adapted to the bony defect, and the liquid fibrinogen is slowly transformed into fibrin. At least 2 membranes (face towards bony defect) are used to cover the block; they are fixed via membrane tacks. Primary closure while suturing is preferred.

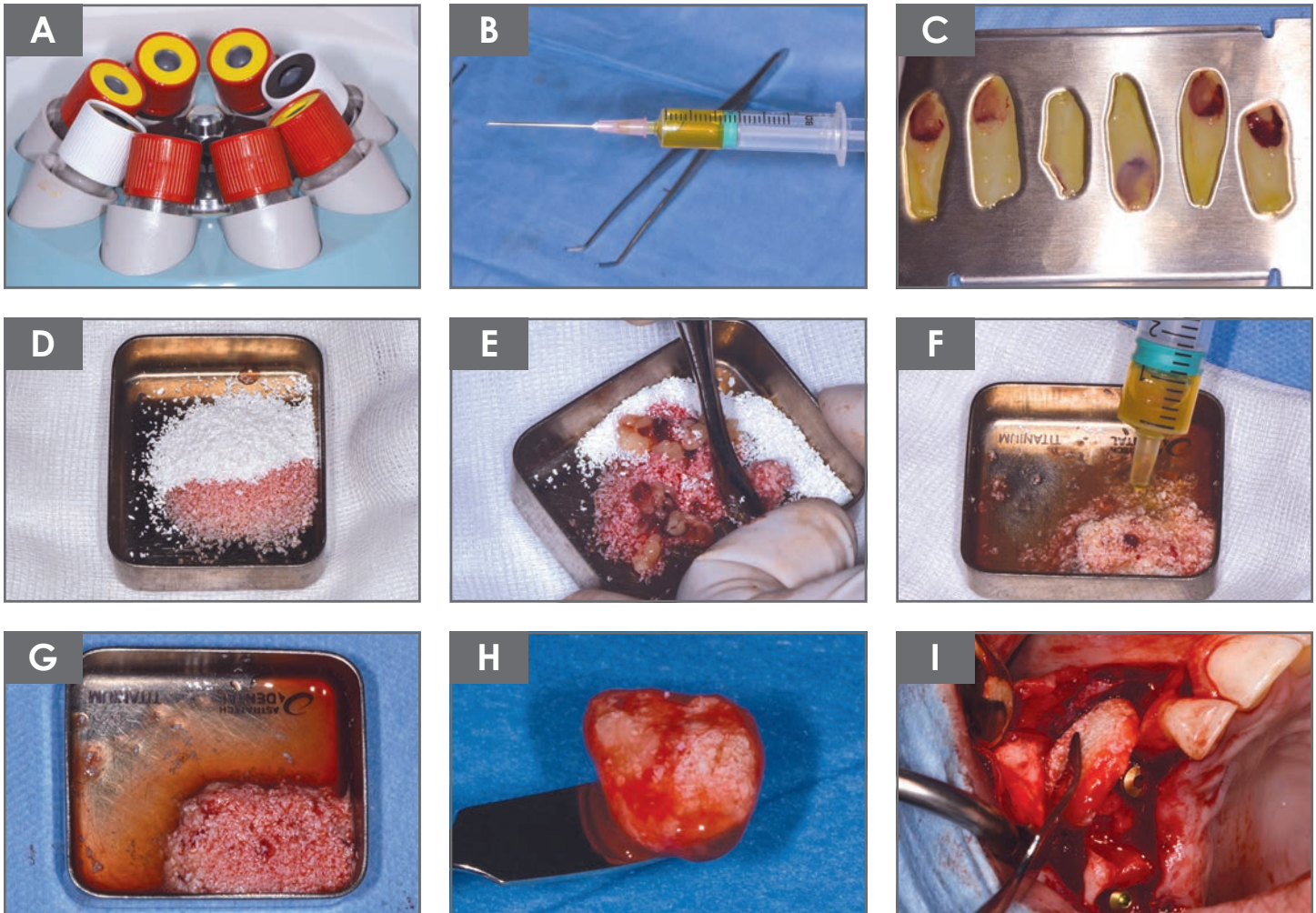
Flow Chart **Eight**

Figure 16:

Clinical preparation of PRF block™ using 0.5g of biomaterial.

- A:** Collection of 6 tubes (red cap, glass coated) of blood following standard protocol, and at last 2 tubes for Liquid Fibrinogen (white cap, plastic coating).
- B:** After 3 minutes of centrifugation, remove white cap tubes, close the centrifuge and restart for the remaining 9 minutes with the red cap tubes. Collect the liquid fibrinogen with a sterile syringe, get as close as possible to the red cells, but do not aspirate them; use a plastic 5 cc sterile syringe with 21G needle and keep the liquid in that syringe with cover lid on.
- C:** Gently compress the clots into membranes in the Xpression™ box.
- D&E:** Mix chopped membrane(s) and bone substitute in Ti dish.
- F&G:** Add liquid fibrinogen over the homogeneous mix, and stir gently while shaping it to the desired form.
- H:** L-PRF block ready to use (± 5 minutes).
- I:** Placement of L-PRF block over implant with buccal dehiscence.

♦ **Acknowledgement:** We would like to thank Jeffrey Sakoff from Intra-Lock, Inc. for the layout of this document and for some equipment photos.



Flow Charts
Step by Step Approach